

ELEMENTARY AND DENTAL RADIOGRAPHY

BY

HOWARD RILEY RAPER, D.D.S.

Professor of Roentgenology, Operative Technic, Materia Medica and Therapeutics at the Indiana Dental College, Indianapolis. Past Dental Surgeon to the Indiana School for the Feeble-Minded Youth. Member American Institute of Dental Teachers, local, state and national dental societies, First District Dental Society of the State of New York, Western Roentgen Ray Society, Associate Fellow A. M. A., Section of Stomatology.

WITH OVER 500 ILLUSTRATIONS

SECOND EDITION

Adopted as a Text-Book by the National Association of Dental Faculties

---

BROOKLYN, NEW YORK:

DENTAL ITEMS OF INTEREST PUBLISHING CO.

LONDON:

CLAUDIUS ASH, SONS & CO., Ltd.

1922

HARVARD MEDICAL LIBRARY
IN THE
FRANCIS A. COUNTWAY
LIBRARY OF MEDICINE

Copyright, 1913
By HOWARD R. RAPER

First Reprint
May 17, 1916

Second Reprint
July 5, 1916

Copyright, 1918
By HOWARD R. RAPER

Copyright, 1913, in the United Kingdom
By CLAUDIUS ASH, SONS & CO., LTD., LONDON

One of "his boys," the writer, grasps this opportunity to show his love and respect for

GEORGE EDWIN HUNT, M.D., D.D.S.

by dedicating this book to him.

PREFACE

FIRST EDITION

The object of this book is to teach, first, the elementary principles of radiography; second, special dental radiography.

The first part of the book is written on the presumption that the reader knows nothing about electricity, photography, or the X-rays, and might therefore be used by anyone who wishes to take up radiographic work, whether a dentist or a physician. In dealing with the preliminary subjects mentioned, an earnest effort has been made to avoid useless, impractical and confusing elaboration.

The second part of the book is devoted to dental radiography, and is consequently of interest mainly to dentists and specialists in radiography who do work referred to them by dentists. It gives in detail the special technic involved in the practice of dental radiography, also a chapter with one hundred and eighty-three halftone illustrations, demonstrating sixty-four different uses to which the radiography may be put in the practice of dentistry.

The use of the radiograph in the practice of modern dentistry is not a mere fad; it is a necessity, if one wishes to render the best dental service. Nothing but great good can come from its more frequent use. To the end of bringing about a more extensive use of the radiograph by dentists this work is published. At present it is the only work of its kind on the book market.

So many people have helped me in the compilation of this volume that I refrain from naming and thanking any particular individual. A publication of this kind, of necessity, represents the work of many.

H. R. R.

PREFACE

SECOND EDITION

(The beginner in radiographic work should read this.)

As stated in the preface of the first edition "the object of this book is to teach, first, the elementary principles of radiography; second, special dental radiography."

When the beginner sees this book, for the first time, and notes its size I can readily understand the feeling of discouragement which would induce him to offer a prayer for a smaller book—one which treats the subject in a less exhaustive manner, more in the manner in which the average man wishes to take it up. The prospect of having to "wade through" thousands upon thousands of words to gain a comparatively few practical facts is certainly not an inviting one. So allow me to direct the alarmed beginner's attention to these facts: The place to begin study is at the beginning of the book—not the middle. The entire subject of Electricity is covered in only 13 pages! The subject of Elementary Radiography, including the 13 pages devoted to Electricity, and chapters on X-ray Machines, X-ray tubes and the X-rays, and the technic of Making Radiographs is covered in 84 pages. Only 52 pages cover a detailed consideration of dental radiographic technic. Thus the entire subject of Elementary and Dental Radiography, as most men will wish to take it up, is covered in only 145 consecutive pages. From page 145 on, commencing with the chapter on "The Uses of the Radiograph in Dentistry" the book becomes a reference book, special attention having been given to the index in the back of the book so the reader may locate the subject he wishes to "look up" with ease.

Much of the first edition of this book, particularly the elementary part of it, was written from old notes which I had made for my own benefit at the time I was engaged in educating myself in radiography. It is owing to this fact more than any other one thing, I believe, that the book has proved of such definite value to beginners in this work; the tone of the text is not beyond the comprehension of the man or woman who is just taking up the work. It is with this in mind that I have refrained from altering the original text as far as possible, in this the second edition, and have written an appendix to each chapter where necessary, giving therein such further consideration of the subject as changes, which have developed in the past few years, seem to demand. In this way I hope to avoid the mistake, most common with writers on electro-dental and medical subjects, of overloading the reader's mind with details at the outset.

Though I have followed the plan of revision just outlined as far as possible, I have nevertheless found it imperative to make a number of changes through the book and to rewrite Chapters V and IX. These changes I hope, and believe, will add to simplicity rather than detract from it, and the appendix may be read by those who have prepared themselves for it and feel the need of further knowledge on the subject.

I made the statement in the preface for the first edition that "the use of the radiograph in the practice of modern dentistry is not a mere fad; it is a necessity, if one wishes to render the best dental service." Let me concede that, as some men use it to-day, the use of the radiograph in dentistry is only a fad.

New methods and things introduced into medicine and dentistry are often received with over and irrational enthusiasm, followed with their equally irrational abandonment. The extensive use of the radiograph is new. It is just about to pass through the stage of reaction from over-enthusiasm. Its use will never be abandoned, however; so let those of us who know its limitations teach those who do not know, lest in their discouragement and misunderstanding they fail, for a while, to avail themselves of this necessity to service. Accordingly the Appendix to Chapter VI has been written, which, to the very superficial thinker, will seem a tirade against the use of the dental radiograph, but which in reality is a most pertinent recognition of the fact that we will always use dental radiographs.

The use of dental radiographs, coupled with the modern theories of metastatic infection as a cause of so many different diseases, brings the old, old problem of pulp canal work before the dental profession in a new light—the light of the X-rays and holds it there demanding a solution. It is fitting that we should consider, at some length, "The Problem of Pulp Canal Surgery" in this volume and accordingly a chapter on this subject will be found in the appendix. The X-rays have played a most important part in bringing this problem before us again and they will play an equally important part in its solution. I direct particular attention to the chapter on "The Problem of Pulp Canal Surgery and Oral Infection," believing it contains material of considerable importance to the dental profession, the medical profession and last, but far from least, the public.

By way of explanation in fairness to some of the men whose names appear beneath the radiographs in Chapter VII, and in fairness to myself as well, I wish it known that the radiographs illustrating this chapter were chosen primarily for their clinical value, and not because they are examples of excellency in radiodontic work. There are 183 radiographic illustrations; most of these are excellent, many are ordinary, and a few are poor, but of such definite clinical value that it would be a sacrifice not to use them.

The policy of not retouching radiographs has been adhered to very closely, for retouching takes the "life" and "personality" out of radiographs. Only a very few radiographs have been retouched.

In this edition of the book, as in the first, I have not used the Roentgen words because I do not like them. Take, for example, the word radiodontia: The equivalent for radiodontia, using the Roentgen nomenclature would be Roentgenodontia. The literal meaning of Roentgenodontia, as my good friend, Dr. Ottolengui, points out, would be "Professor Roentgen's teeth."

In compiling material for this second edition I have been impressed again with the fact that a volume of this kind represents as much the work of his friends as the work of the author. I will, however, express my appreciation of the co-operation of my publishers, whose liberal policy of allowing me to use illustrations as freely as desired, regardless of expense, has added greatly to the teaching value of the book. Also, I must; I cannot keep from thanking Dr. John Callahan and Dr. Dave House, and my secretary, Miss Fannie Agnew, to whom I am greatly indebted.

TO TEACHERS OF DENTAL RADIOGRAPHY

For years I lectured to dental students in an effort to teach Radiography. I failed to get the results I knew I should get.

I then wrote my book on the subject, assigned lessons in it and quizzed over the assignments. And, again, I failed to teach the subject as it should be taught.

Students simply floundered about in the assignments and were not able to answer questions.

I wrote a compend on the subject, and discarded it, because, like all compends, it failed to cover the subject as well as it should be covered.

I then read my book (it is proof conclusive that a writer is desperate when he reads his own book) and, as I read, prepared a list of questions covering the most important points in the text, and had this list of questions published in the form of a small "Assignment Booklet." With this booklet and the text book in the hands of the student I can now assign lessons by giving a certain number of questions. After each question in the booklet is the number of the page on which the answer may be found. The questions are such as to cause the student to read all of the text included in the assignment. Much longer assignments can be made in this way. The student has something to "hold to" as he tackles his assignment. He reads the text with a feeling of security as to what is most important and to be remembered, instead of trying to remember everything in, say, a thirty-page assignment and failing to remember anything, or becoming discouraged and "chucking the whole assignment."

The results of this manner of teaching the subject have been gratifying beyond my rather enthusiastic hopes for it. It does not prepare students to go forth and straightway operate any X-ray machine with immediate and full success any more than a course of study of motors would enable a man to jump into an automobile and drive it. But it gives students such a fundamental knowledge of the subject that they may take up the work with a feeling of confidence in themselves.

This little Assignment Booklet will be found of value also to the man who is educating himself.

H. R. R.

December, 1917.

CONTENTS

CHAPTER		PAGE
	Elementary Radiography	
I.	Electricity	1
II.	X-Ray Machines	14
III.	X-Ray Tubes and the X-Rays	41
IV.	Making Radiographs	65
	Dental Radiography	
V.	Making Dental Radiographs	85
VI.	Reading Radiographs	136
VII.	The Uses of the Radiograph in Dentistry	146
VIII.	The Dangers of the X-Rays	273
IX.	Purchasing a Radiographic Outfit	292
X.	Stereoscopic Radiography	297
	Appendix	
	Electricity	319
	X-Ray Machines	320
	X-Ray Tubes and the X-Rays	331
	Making Dental Radiographs	341
	Reading Radiographs	357
	Uses of Radiographs in Dentistry	416
	The Danger of the X-Rays	423
	Stereoscopic Radiography	431
	The Problem of Pulp Canal Surgery and Oral Infection	437

Elementary and Dental Radiography.

CHAPTER I.

Electricity.

Dental radiography is the science and art of making pictures of the teeth and contiguous parts with the X-rays. Its place and value in the practice of modern dentistry will be dealt with later.

Before we can produce X-rays we must have at our disposal that something called electricity.

Electricity. Electricity is a form of energy closely related to motion, light and heat. We know it is closely related to motion, light and heat because these forms of energy can be made to produce electricity, and electricity conversely can be made to produce them. Electricity is discernible to but one of the special senses, namely, feeling. It cannot be seen, heard, smelled or tasted. Victims of severe shocks have noted a peculiar taste, which they call the taste of the electricity, but it is my opinion, neither proved nor disproved as yet, that this taste is due to the presence of new chemical bodies formed in the saliva by electrolysis. In other words, the passage of the current of electricity through the saliva causes chemical changes to occur, resulting in the formation of new chemical bodies, and it is these new bodies, not the electricity, that produce a taste.

Conductors. When electricity passes from one place to another the substance through which it passes is said to be a conductor. A substance through which electricity passes with great difficulty, when at all, is said to be a non-conductor. Metals are the best conductors of electricity. Silver is the best, then copper. Copper wire is the most used of any conductor of electricity. German silver carries electricity very reluctantly, and bismuth is the poorest conductor of the metals. It was formerly thought that electricity traveled on the surface of a conductor, but if this were true a round wire could be made to carry more current by simply flattening it and so making the surface greater; while, as a matter of fact,

the flattened wire would carry less, because of the condensation of the metal incident to flattening. The human body is a conductor. Wood, glass and vulcanite are examples of non-conductors.

When electricity passes from one place to another through a conductor, what is known as the electric current is established.

Currents. There are four kinds of electric currents: (1) The continuous, constant, or direct current, commonly designated D.C.; (2) the pulsating; (3) the interrupted; (4) the alternating or oscillating, designated A.C.

The direct current is one in which the electricity is presumed to flow through the conductor in one direction at a uniform rate of pressure.

The pulsating current is one in which the electricty flows through the conductor in one direction, but at variable pressure.

The interrupted current is one in which the electricity flows through the conductor in one direction while in motion, but which is completely arrested in its flow at frequently recurrent intervals.

The alternating current is one in which the electricity flows through the conductor first in one direction, then in the other. When the current, flowing in a given direction, reverses, flows in the opposite direction, and then resumes its original direction of flow, it is said to have completed a cycle. The number of cycles occurring in a second determines the frequency of the current. We thus have, for example, a 60-cycle frequency current, making sixty complete alternations per second.

Potential. Electricity travels from one place to another because of a difference in potential. The term potential means latent, inactive, or stored-up energy. Take lightning as an example of traveling electricity. Why does it occur? One cloud has a potential, figuratively speaking, of say 30, another of 20. These clouds approach close enough to one another so that electricity can jump the atmospheric gap between them, which it does, passing from the one with a potential of 30 to the one with a potential of 20 and equalizing the potential of each to 25. The light of lightning is caused by the resistance of the atmosphere to the passage of electricity. If such a thing were possible and an electric conductor stretched from the one cloud to the other, the potentials would be equalized as just described, but without the occurrence of the phenomenon called lightning, because the electricity would unostentatiously flow through the conductor instead of through the highly resistive atmosphere.

All electricity-producing machines, then, simply create a comparatively high potential, so that when a path is afforded—*i. e.*, when conductors are attached to the machine—the electricity leaves, in its effort to equalize potential.

Velocity. Electricity travels at an inconceivably rapid rate of speed, instantaneous results being obtained hundreds of miles distant on pressure of a button. It is stated that the velocity of electricity is about the same as light, which latter travels about 186,000 miles per second. To comprehend this great speed compare it to the velocity of sound, which travels only 1,090 feet per second.

In dentistry and medicine the terms used can often be translated literally into their meaning. For example, "odontalgia" is a combination of two Greek words meaning tooth and pain; "tonsilectomy" is a combination of a Latin and a Greek word meaning tonsil and excision. Electrical terms are, however, derived principally from proper names. For example, volt, the unit of measurement of electric pressure, has no literal meaning at all, but is so called in honor of Alexander Volta, a great electrician. And so with the terms ohm, watt and ampere.

Volt. When electricity leaves the electricity-producing, or, if you choose, potential-creating, machine, it passes into the conductors at a given pressure. This pressure is measured in volts, just as pressure in a water-pipe is measured in pounds. The volt, then, is the unit of measurement of pressure of electricity. Just what is a "unit of measurement"? Take, for example, the unit of linear measurement; it is called the "meter," and and is one-ten-millionth of the distance from the equator to one of the earth's poles. The unit of linear measurement, then, the meter, is a definite name applied to a definite distance. So the volt is a definite name applied to a definite degree of electric pressure, or, which means the same as electric pressure, electromotive force, designated E.M.F. This force is sufficient to maintain a current of electricity of one ampere (the unit of measurement of volume of electricity) through a resistance of one ohm (the unit of measurement of resistance to the flow of current offered by an electric conductor). Let us then fix this firmly in our minds. The volt is the unit of measurement of electromotive force, or pressure. Though it is not commonly used, the writer much prefers the word "pressure" to "force," believing it to more clearly express the meaning.

Ohm. No conductor carries electricity without offering a certain amount of resistance to its flow. This resistance, which might be compared to the friction offered by the sides of a pipe to the flow of water, is measured in ohms. The ohm, then, is the unit of measurement of resistance offered to the flow of electricity by a conductor, and is equivalent of the resistance afforded by a column of mercury having a cross-section of one square millimeter and a length of 106.28 centimeters, at a temperature of 0° C.

Ampere. We have considered pressure and resistance. Now we come to the energy itself, which may be compared to the water in a water-pipe, and is measured in amperes. The ampere capacity of an electric conductor corresponds to the cross-section of a water-pipe, which latter is measured in square inches. Thus the larger the pipe, which means, of course, more square inches in its cross-section, the more water it will carry; and so the larger the electric conductor of a given material the greater its ampere capacity, and the more electricity it will carry.



FIG. 1

The analogy between the water in the water-pipe and the electricity in the conductor is not perfect, however. A given-sized pipe will carry a column of water of a given cross-section and no more, because water is practically non-compressive. When the flow of the water is opposed to gravity, as when drawing water from a faucet, this complete cross-section must be obtained, too—that is, the pipe must be full—before any pressure will establish a current through the pipe. Not so with electricity in a conductor. A wire which has a normal capacity of say 30 amperes will carry a current of 10, and it can be made to carry 40 or 50 by increasing the pressure, because electricity is compressible.

Amperage, or the volume of electricity carried in a conductor, depends on two things—the pressure of the current and the resistance of the conductor. Hence Ohm's law, which is that the volume of the current can be obtained by dividing the pressure by the resistance. In other words, the amperage can be obtained by dividing the volts by the ohms.

Problem: An electromotive pressure of 100 volts is acting against a resistance of 50 ohms. What is the ampere strength of the current?

Solution: 100 volts divided by 50 ohms equals 2 amperes.

To give the exact amount of electricity represented by the ampere, it is that amount which, when passed through a standard solution of silver nitrate in distilled water, will cause a deposition of metallic silver at the rate of 1.118 milligrams per second.

Watt. Electromotive power (not electromotive pressure or force; note the word "power"), or the ability of a current to do work, depends on two things—the pressure measured in volts and the volume measured in amperes. This is also true in hydraulics. The amount of work a stream of water will do depends on pressure and volume. The watt is the unit of measurement of electromotive power, and the wattage of a current is obtained by multiplying the volts by the amperes. Thus, if we had a current of one ampere under a pressure of one volt, one watt would be operative.

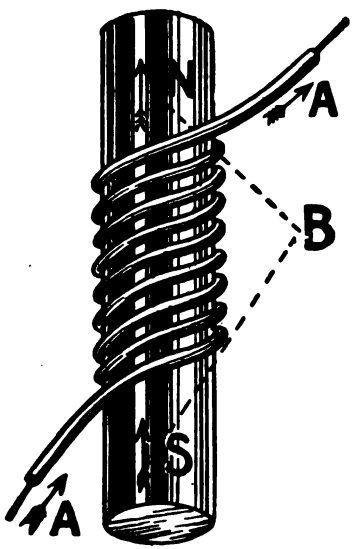

Fig. 2.

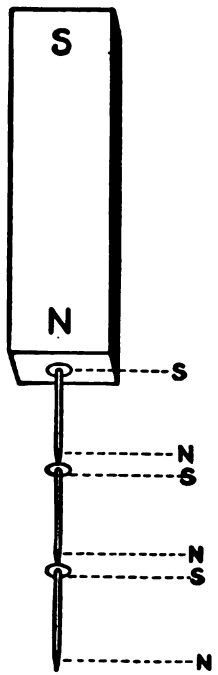

Fig. 3.

Fig. 2. Arrows A represent the direction of flow of electric current. Arrows B represent the direction of flow of magnetic flux in the magnet.

Fig. 3. Bar magnet with polarity indicated.

When 1,000 watts are active for an hour—that is, when a current 1,000 watts strong has been in motion, the current turned on, for one hour—the electrometer will register one kilowatt-hour. So bills for electricity are made out for so many kilowatt-hours.

Magnetism. Magnetism is a form of kinetic energy very closely related in its nature to electricity. Magnetism produces electricity, and vice versa.

The substance in which this energy, or property, magnetism, resides is called a magnet.

If a bar of magnetized steel be dropped into iron filings, and then raised, the fillings will adhere to the ends of the bar, but not to the center. (Fig. 1.)

The ends of the bar represent, respectively, the north, or positive, and the south, or negative, poles of the magnet. If, now, this bar be broken at its exact center, instead of having a half magnet all north pole and another half magnet all south pole, we have two magnets with two poles each. If one of these magnets be broken at its center the same thing occurs, namely, two magnets, each one-half as large as the first,

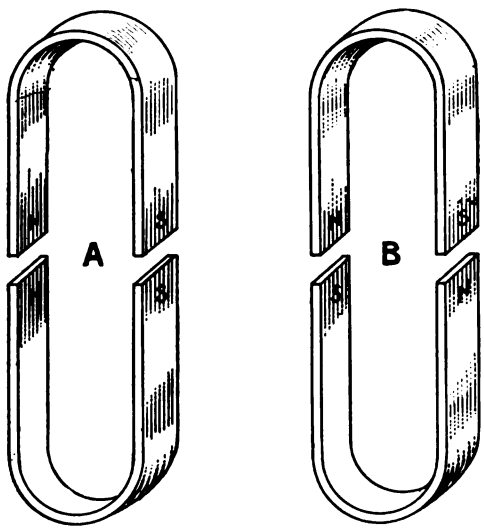

Fig. 4. When poles are arranged as in A repulsion exists between the magnets. When poles are arranged as in B the magnets are attracted to one another with the magnetic flux of each north pole flowing into the south pole of the other magnet.

are made. This redivision can be repeated down to the molecule, which would have a north and a south pole.

Magnets are of two kinds—the natural magnet, or "loadstone," and the artificial magnet.

The earth may be considered a large magnet, the poles of this magnet being near the north and south poles of the earth. The natural magnet is iron ore, found in nature with all the properties of the magnet, and representing a portion of the great magnet, the earth.

Artificial magnets are of three kinds—the electro-magnet, the permanent magnet and the induced magnet.

If a bar of soft iron be wrapped with insulated wire (wire covered with a nonconductor) and a current of electricity be sent through the wire, the iron bar becomes magnetized while the current passes through the conductor, but loses its magnetism when the current ceases to flow. Such a magnet is called an electro-magnet. (Fig. 2.) If the current be sent through the conductor in the opposite direction to that shown in the diagram, polarity of the magnet will be changed: the north pole will become the south pole and the south pole the north pole.

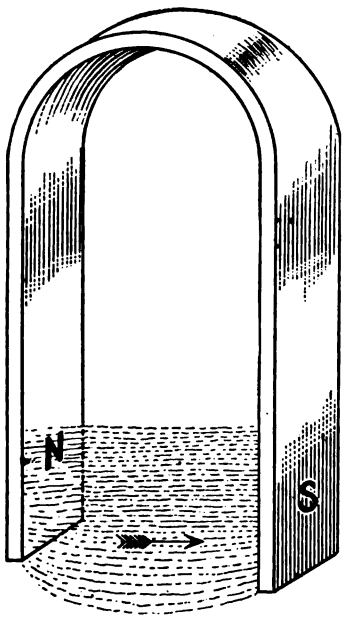

Fig. 5.


Fig. 6.

If hard steel, instead of soft iron, be used as the core and wrapped with insulated wire and a current of electricity be sent through the wire for a great length of time, then the current shut off and the wire removed, it will be found that the steel retains its magnetism and will continue to retain it over a number of years. Such a magnet is called a permanent magnet (Figs. 1 and 4, for example), though it is not actually permanent and will lose its magnetism in time. The permanent magnet in greatest general use is the "horseshoe" magnet (Figs 4 and 5), which is simply the bar magnet (Figs. 1 and 3) bent into horseshoe or staple shape.

Instead of using the electric current, a permanent magnet can be made by rubbing hard steel with another magnet.

Fig. 3 shows a magnet holding three nails. As long as the magnet

remains in contact with the first nail it will hold the second nail, and the second will hold the third. But remove the magnet and no attraction exists between the nails. While the magnet touches the first nail each nail is an induced magnet, with a north and south pole, as shown in the figure.

While either the north or south pole of a magnet will attract a piece of unmagnetized iron or steel, only unlike poles of two magnets will be attracted to one another. Thus, if two north or two south poles of magnets be brought in close proximity repulsion instead of attraction exists between them. (Fig. 4.)

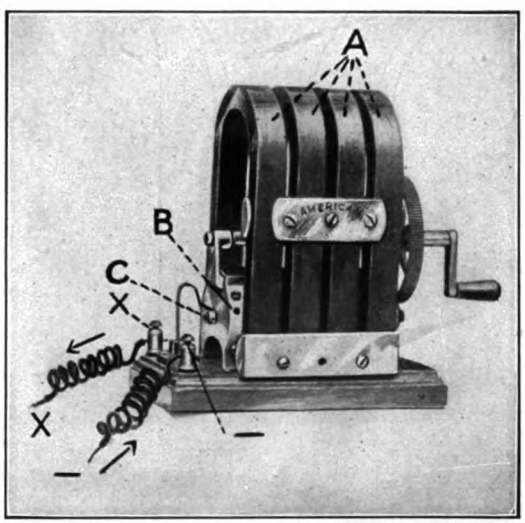

Fig. 7. Magneto-Dynamo. A, the magnets or field. B, casting surrounding revolving conductor or armature. C, appliance for outlet of electricity from armature. An alternating current is generated by this machine.

In 1831 Faraday discovered that when an electric conductor is set in motion so as to cut the lines of force of the magnet at right angles, an electric current is induced in the conductor.

Fig. 5 shows the lines of force of a horseshoe magnet passing from the north to the south pole. Imagine now a spool wrapped with copper wire, not as thread is wound around a spool, but lengthwise of the spool, the wire passing over its ends. Place this spool between the poles of the magnet, revolve it on its axis, and the copper wire—that is, the electric conductor—is made to cut the force of the magnet at right angles and an alternating current of electricity will be produced in the wire (Fig. 6), the current flowing in opposite directions as the different poles are passed.

Add to this arrangement a means for carrying the current away from the apparatus and we have the magneto-dynamo, now very extensively used in automobiles. (Fig. 7.)

Dynamos. Dynamos may be divided into two classes: the magneto-dynamo, just described, and the electro-dynamo.



Fig. 8. A Direct Current Generator or Electro-Dynamo.

All dynamos consist of three cardinal parts, to wit: the field, or magnets; the armature, or revolving conductor, and the rings, or appliance for carrying off the electricity. If the current sent out is direct instead of alternating, a commutator instead of rings must be used. A commutator is an appliance which changes the alternating current induced in the armature into a direct current as it leaves the dynamo.

The electro-dynamo, an example of which is shown in Fig. 8, differs in principle from the magneto-dynamo only in the kind of magnets used. Permanent magnets are used in the magneto-dynamo, whereas electro-magnets are used in the electro-dynamo.

Immense electro-dynamos, or generators, as they are called, make

our commercial currents, steam power being used to revolve their armatures. By commercial current is meant the electric current supplied to us by the electric light and power companies.

Let us trace a current of electricity through what is known as the electric circuit. When the armature is revolved the potential at C, of



Fig. 9. Six Pole Direct Current Generator, parts disassembled. E, electro-magnets with poles of different denominations directly opposite one another—the field. Large alternating current generators have as many as 40 poles in the field which revolves, the armature remaining stationary. A, armature. C, commutator.

Fig. 7, rises. The potential of the positive wire attached to binding post + (which post is connected to C) is instantly raised to that of C, and the current ceases to flow, potential being equalized between the armature and the positive wire. If now the positive wire of the high potential be brought in contact with the negative wire, which is of low potential, the current flows into the latter. The negative wire is attached to the negative binding post, which is connected to the magnets themselves. Thus the current passes through the negative wire into the magnets, which have a low potential. The current will continue to flow, making a circuit from C, out through the positive wire, back through the negative wire, into the magnets until their (the magnets') potential is raised

to that of C. If an incandescent light bulb be connected to the positive and negative wires the current will pass from the positive wire, through the bulb, and into the negative wire. As the electricity passes through the bulb it heats the filament of carbon to incandescence, producing light and some heat. Most of the electricity is used up in the production of the light and heat—this is true if the circuit is what is called "well balanced"—but what is not, travels in the negative wire toward the magnet, equalizing potential until it dissipates itself in the effort.

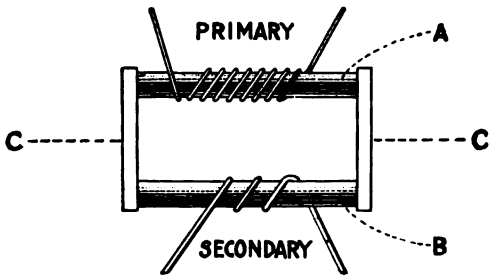

Fig. 10. Diagram of a step-down transformer.

Commercial circuits supply either a D.C. (direct current) or an A.C. (alternating current). The wiring from the D.C. dynamo to the consumer is an intricate problem, difficult to understand. It is enough for us to know that the D.C. is supplied, as a rule, only to downtown districts of cities, by a circuit giving 110 volts pressure, or a special three-wire circuit, which supplies either 110 or 220 volts, according to the manner of the connections made to the mains. The amperage depends on the size of the wires; the more amperage desired the larger the wires connecting to the mains must be.

The A.C. leaves the generator at a voltage of from 1,000 to 3,000, and flows in the mains at this pressure. Such great pressure is both dangerous and uselessly high for ordinary uses, such as lighting, running motors, operating X-ray machines and the like. So, by means of a transformer, the voltage is reduced to any desired strength, usually from 100 to 125 volts. The commercial A.C. is either 25, 60 or 133-cycle, usually 60.

Since the principle involved in the transformer is quite similar to the one met with in X-ray machines, a description of it would not be out of place in this work. Fig. 10 shows the plan of construction of a transformer. A represents an iron core, around which is wrapped insulated wire. This is the primary winding through which passes the primary current at the high voltage of from 1,000 to 3,000. As always, the amperage depends on the size of the wire. B represents another iron

core, around which is also wrapped insulated wire. This is the secondary winding, through which the secondary current passes. C shows soft iron connections between the two cores.

When the electric current is established in the primary winding a current is set up or induced in the secondary winding. Bear in mind there is no electric connection between primary and secondary windings.



Fig. 11. A Transformer.

The primary current enters, and leaves unaltered except for a slight loss in amperage, but in its passage it induces a current in the secondary.

If the wire used in the secondary winding be of the same length and size as that used in the primary winding, the induced secondary current will be of practically the same voltage and amperage as the primary current. But if the wire in the secondary be shorter and larger, the induced current will be lower in voltage and higher in amperage. Or if the wire of the secondary winding be longer and smaller than the wire in the primary winding, the induced secondary current will be higher in voltage and lower in amperage than the primary current. The wattages of the primary and secondary currents remain practically the same. For example, suppose the voltage of the primary current is 1,000, the amperage 5, the wattage would be 5,000. Suppose now, by means of the

transformer, the voltage is lowered to 100; there would be a raise in amperage to 50. Notice the wattage remains the same, 5,000. The figures do not represent what actually happens, since they do not take into account the loss of current due to the internal or intrinsic resistance of the transformer, but they do represent roughly the general principle of the action of the transformer.

A transformer which lowers voltage—the kind used on A.C. circuits between mains and consumer—is known as step-down transformer; one which raises voltage is a step-up transformer.

The transformer does not alter the nature of the current. That is, the secondary is an alternating current, the same as the primary, the change being only in voltage and amperage. Transformers cannot be used on a direct current.

The foregoing is calculated to give the reader a speaking acquaintance with electricity, the wonderful force which produces X-rays. Further treatises of the subject will be made as necessity demands. It will be noted that but one source of electricity has been considered, namely, dynamo electricity—that furnished by light and power companies. Be it known, however, that electricity can be produced by means other than the dynamo—by friction and chemical change, for examples. We have considered only the source of electricity which is used to operate the X-ray coils.

CHAPTER II.

X-Ray Machines.

It was stated in Chapter I that an electric current is necessary to produce X-rays, but nothing was said concerning the strength of the current required. It takes a current very high in voltage, varying from about 50,000 to 100,000 or more volts, and low in amperage, the amperage being measured in milliamperes. Milliamperage ranges from 2 or 3 to over 100. For dental radiographic work the milliamperage used ranges from about 5 to 60.

The ordinary commercial circuit for lighting purposes is almost invariably either D.C., 110 volts, or A.C., 60-cycle, 100 to 125 volts. The amperage varies according to the amount of electromotive power needed, ranging from 4 to 5 to over 100 amperes. The commercial current, *as supplied,* is therefore useless. However, it will operate a machine which will give the desired current.

X-Ray Machines.

X-ray machines are of two classes: Those that generate their own electricity without any external electric supply, and those that depend on a commercial current or storage batteries to excite them. There is but one of the first class, namely, the static machine (Fig. 12), and of the second class there are three—the Ruhmkorff coil (Fig. 13), the high frequency or Tesla coil (Fig. 14), and the "interrupterless" coil (Fig. 15). All of the latter class are literally induction coils, just as the transformer, described in Chapter I, is an induction coil, but when the term induction coil is used we may assume that it is the Ruhmkorff coil that is referred to. We shall follow the precedent and call the Ruhmkorff coil the induction coil, though it is no more an induction coil than the high-frequency or "interrupterless" coils.

The static machine is so much inferior to the induction coil for picture work, and so large and difficult to operate, compared with any coil, that the only reason for using it would be the lack of a commercial current with which to operate a coil. Even in such an event—the lack of a commercial current—I would advise the use of an induction coil operated by storage batteries (Fig. 16) in preference to the static machine.

Induction Coil.

The induction coil is a popular apparatus for giving the electric current necessary for X-ray picture work. It is a step-up transformer to this extent, namely, its primary current is of comparatively low voltage and high amperage, while the secondary is very high in voltage and low in amperage. It differs from the transformer in mechanical construction, and also in that the primary current must be an interrupted current, and the secondary, induced current is

Fig. 12. A static machine.

practically a uni-directional one. It will be recalled that the primary and secondary currents of the transformer are both alternating.

Installation.

Let us trace a current of electricity from the mains through an induction coil and auxiliary appliance leading to it. (Fig. 17.)

Wiring from the mains to the coil should always be done by a competent electrician. A wire of a given size will carry only a certain amperage without heating. If this amperage be exceeded greatly the wire

may become hot enough to set fire to surrounding building material of a combustible nature. There are, therefore, laws governing the size of wires to be used to carry different amperages. Coils are rated by their manufacturers to consume a certain number of amperes, and wiring

Fig. 18. Induction or Ruhmkorff coil.

should be done according to this rating. The amount of amperage necessary to operate a coil varies directly according to the size of the coil—the larger the coil the more amperes it takes. Assuming the coil to be of a medium large size, the lead wires used to connect it to the mains should be capable of carrying at least 30 amperes without heating. By "lead wires" I mean the wires leading to the machine—not lead (the metal) wires. The wires are copper.

Fuses. Somewhere near where the wires enter the building, and also at the coil itself, will be found fuses. (Fig. 18.) A fuse is a wire, an alloy of lead, of a given size, and fusing point, capable of carrying only a limited amperage without melting. Thus, if more than 30 amperes be sent through a 30-ampere fuse, the wire is heated to its fusing point, it melts, the circuit is broken, and the flow of electricity is stopped. A fuse is a



Fig. 14. High-frequency coil.

sort of safety valve. About 30 ampere fuses should be used for a medium large induction coil. This information, however, will always be given by the manufacturers of the coil.

Switches. Somewhere near where the wires enter the building, and also at the coil, are placed switches. An electric switch (Fig. 19) is an appliance for throwing the electric current into, and out, of an extended or auxiliary circuit.

Assuming that the current at our disposal is D.C., it must first be passed through an interrupter.

Interrupters. An interrupter is an electric apparatus by means of which a constant current is converted into an interrupted one. Interrupters are of three kinds: (1) The electrolytic, Fig. 20; (2) the mercury turbine, Fig. 21, and (3) the mechanical or vibrator, Fig. 22.

For picture work, in connection with the induction coil, the electrolytic, or, as it is sometimes called in honor of the inventor, the Wehnelt interrupter, is quite the best. With it the constant current may be

interrupted at the rate of from 60 to 30,000 interruptions per minute. The mercury turbine gives from 200 to 3,600 interruptions per minute, and the vibrator from 250 to 1,000 interruptions a minute.



Fig. 15. Interrupterless coil.

The electrolytic interrupter consists of a glass jar containing a solution of sulphuric acid in water, the electrolyte, in which is immersed a platinum point electrode, A (Fig. 20), and a lead electrode, B. The platinum is covered with a porcelain sheath, C, except for its point, which projects into the electrolyte. Little or much of the point may be exposed in the acid by the regulating arm, D.

We have two wires now leading from the mains to our apparatus.

Of these one is the positive wire which brings the electric current, and the other is the negative or return wire. The positive wire must be attached to the binding post of the platinum electrode, marked +. (Fig.



Fig. 16. Induction coil for use with storage cells.

20.) But how can we tell which is the positive wire? Cut some of the insulation off the ends of the wires, immerse them in a glass of water, and bubbles will be given off from the negative wire. When making this test, care should be taken not to touch one wire to the other, so making a short circuit. The term (short circuit) almost explains itself. The desired circuit in this instance is from the positive wire, through the water, which is highly resistive to the flow of electricity, into the negative wire and back to the mains. Suppose that the wires come in contact

(that portion of the wires from which the insulation has been removed), the current no longer passes through the water, but takes the shorter path of less resistance, passing directly from positive to negative wire. All the amperage formerly used and choked back by the resistive water flows through the wires, heating them rapidly.

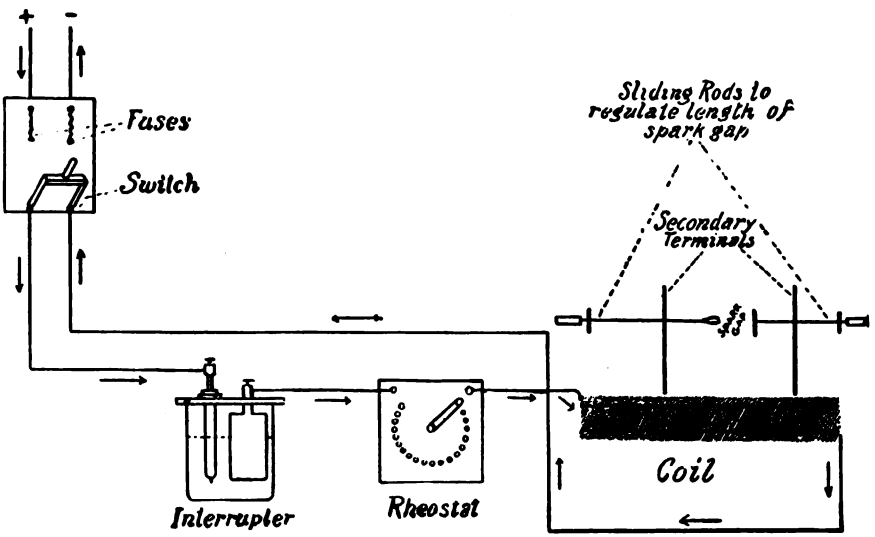

Fig. 17. The spark gap between the secondary terminals is the "parallel spark gap."

The course of the electric current, through the electrolytic interrupter, is from platinum through the acid electrolyte, and on through the lead electrode. As the current flows through the acid solution, a chemical change occurs and a gas is formed. This gas accumulates in the form of a bubble around the exposed platinum point, and momentarily stops the flow of the current. Then the bubble bursts and the current is re-established only to be stopped again in the manner just described, and so on. The more platinum exposed in the solution the slower the interruptions and the more amperage will pass through the interrupter. In order that the amperage may be increased without producing a corresponding decrease in the number of interruptions per minute, interrupters are made with several platinum points. (Fig. 23.) Thus with a multipoint interrupter, when more amperage is desired, more points are thrown into the circuit by means of small switches for the purpose. A 1 or 2-point

interrupter will draw enough amperage, and give sufficiently rapid interruptions, for dental radiographic work.

The current is sometimes stopped altogether by the interrupter. This may be due to the accumulation of a large bubble of gas, on the platinum point, which will not burst. By moving the point—or points if the inter-



Fig. 18. Patent fuses or cutouts.

rupter is multipointed—up and down several times by means of lever D, Fig. 20, the bubble will be broken and the current re-established.

On a D.C., 110-volt circuit the electrolyte should be 15 to 20 per cent. acid; on a D.C., 220-volt circuit, from 5 to 8 per cent. is strong enough. The jar should be one-half or three-quarters full. As the solution stands, some of the water evaporates, so raising the per cent. of acid in the electrolyte. As this occurs, more water should be added. The strength of the solution can be easily and accurately determined by means of a hydrometer. (Fig. 24.) As the water evaporates, and the solution gets stronger, its specific gravity raises. The hydrometer is sensitive to this change of specific gravity.

As the current passes through the interrupter, heat is produced. Hence the glass jar is placed in a metal-lined box, and the box filled with water. (Fig. 23.) Even with this means for cooling, when used continuously for fifteen minutes or longer, the electrolyte becomes so heated that the interrupter no longer works properly. In dental picture work, though, the time of operation is a matter of seconds. It, therefore, will be understood that no trouble ever occurs due to heating of the electrolyte.

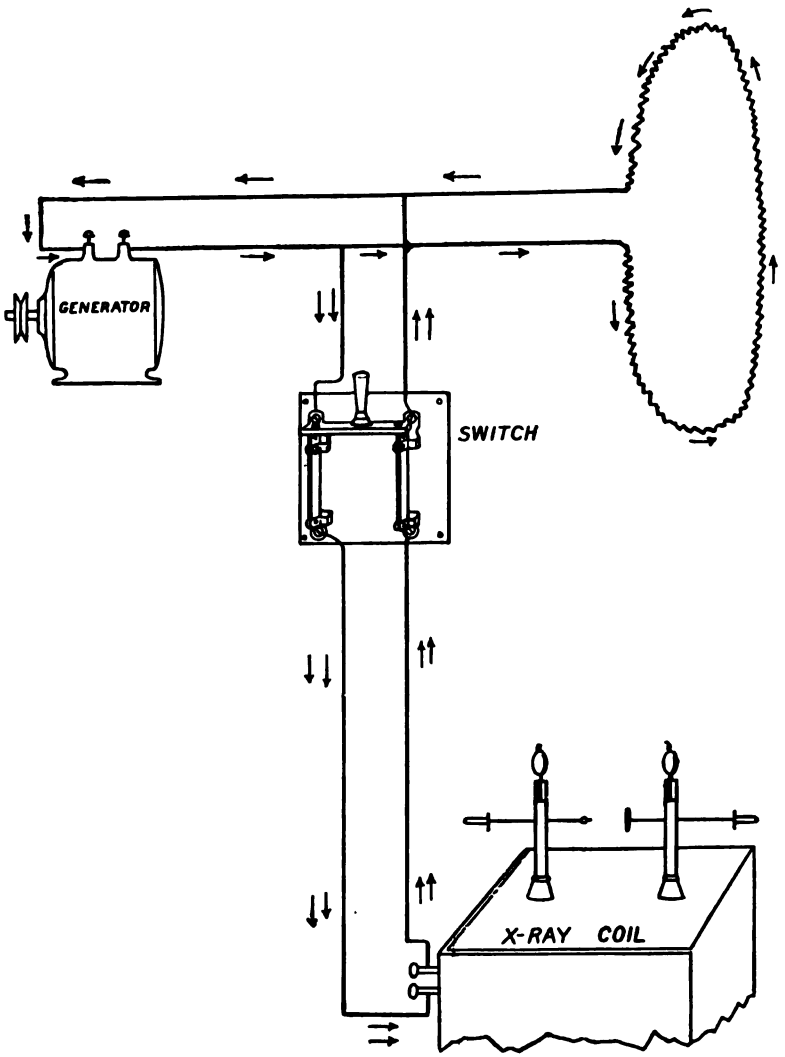

Fig. 19. Diagrammatic illustration showing the action of an electric switch. The single arrows mark the course of what we shall call (not knowing a better name) the original circuit. The double arrows mark an extended circuit. The drawing shows the switch —one of the double knife variety—closed. With the switch open the current could not pass through the extended circuit.

When the X-rays are used for their therapeutic value, long exposures are made; so long that undue heating of the electrolytic interrupter would be sure to occur. Hence, for this work the mercury turbine interrupter (Fig. 21) is best. In principle the mercury turbine is a mechanical interrupter, depending on no chemical change for its action, being operated by means of an electric motor. We shall not consider it



Fig. 20. Non-water cooled one-point electrolytic interrupter.

further, for it should not be used for picture work, except in the absence of an electrolytic interrupter.

The mechanical interrupter, or vibrator (Fig. 22), is used only on the smallest coils. The principle on which it operates is the one involved in the construction of electric bells; Fig. 25 illustrates the principle. A is a movable arm with fulcrum at B. When the current travels, the path marked with arrows, the electro-magnet, C, draws the movable arm, A, over to it, breaking the circuit at D. When the circuit is broken the electro-magnet loses its magnetism and the spring, E, draws the movable arm back, re-establishing the circuit. The rapidity of interruptions may be regulated by altering the strength of the spring. A popular form of vibrator is the ribbon vibrator illustrated in Fig. 26.

Rectifier.

In tracing the current directly from the supply wire into the interrupter, we have assumed, as stated, that we are receiving our supply from a D.C. circuit. Suppose, however, that the only current at our disposal is A.C., as is often the case. Most manufacturers consider it necessary to pass the alternating current through a rectifier (Fig. 27) before sending it into the interrupter.

A rectifier is an electrical apparatus by means of which an alternating current is converted into a uni-directional, pulsating current, and



Fig. 21. Mercury turbine interrupter.

consists of a glass jar containing an electrolyte, a solution of ammonium phosphate usually, in which is immersed a steel electrode and an aluminum electrode. The jar, the electrolyte, and the two electrodes constitute one cell. Fig. 27 shows a one-cell rectifier.

With the direct current, we are able to test and determine which of the two lead wires is positive. This is impossible with the alternating current, because polarity changes at each alternation. Either of the lead wires may therefore be attached to the steel electrode, and a wire connected from the aluminum electrode to the platinum of the interrupter. As long as the aluminum remains the negative electrode of the rectifier, the current flows from steel to aluminum and on, but when the current reverses and starts to flow from aluminum to steel, a chemical change occurs in the aluminum, making it a non-conductor and choking off the flow. Thus a current of 60-cycle frequency, after passing through a one-cell rectifier, becomes practically (there is a slight inverse current) a

uni-directional current with 30 interruptions per second. If, after passing through the rectifier, as just described, the current is an interrupted one, the questions arise: Why send it through an interrupter? Why not directly on to the coil? Because the interruptions are not sharp and complete enough. The current is pulsating rather than interrupted.

By connecting three or four rectifier cells in a certain way (Fig. 28), we are able to obtain practically a uni-directional, constant current.

If the supply current is 60-cycle, as is usually the case, the electrolyte in the interrupter remains the same as for a D.C., 110-volt circuit, namely,



Fig. 22. Vibrator or mechanical interrupter.

about 20 per cent., but if the A.C. supply is 133-cycle, the solution should be stronger—about 30 per cent.

From the interrupter the current passes into the rheostat, as per Fig. 17.

Rheostat. A rheostat (Fig. 29) is an apparatus by the use of which we are enabled to regulate the quantity of electricity entering an electric machine. The rheostat does not have much effect on voltage.

Fig. 30 illustrates the rheostat. A represents coils of wire, often German silver, offering great resistance to the flow of electricity. When the arm, B, is on button 1, the current must pass through all the resistive wire on its way to the electric machine, induction coil, motor, or what not. This resistive wire chokes back amperage. On button, 2, there is less resistance; on button, 3 still less, until on the last button the current passes directly into the machine. The rheostat illustrated acts

also as a switch, completely breaking the current when the arm, B, is on button, o.

From the rheostat the current passes into the coil proper, follows the wire of the primary winding, and passes back through the negative lead wire to the mains.

Fig. 23. Seven-point electrolytic interrupter, water-cooled.

A different method of wiring to that shown in Fig. 17 is illustrated in Fig. 31. At first glance it seems that the primary current is not interrupted, the interrupter being on the negative wire with the current passing through it after passing through the coil. But since the current cannot enter the coil any faster than it leaves, the manner of its exit will govern its entrance, and hence the current of the primary is interrupted just the same, whether the interrupter be placed on the positive or negative lead wire.

Coil.

The coil consists of a soft iron, cylindrical core, around which is wrapped insulated copper wire, the primary winding. (Fig. 32.) (The necessity for good insulation will be appreciated if we stop to consider what would



Fig. 24. A Baume hydrometer. For 110 volts the electrolyte in the interrupter should have a reading between 20 and 25; for 220 volts, between 10 and 15.

happen if the core were wound with uninsulated wire. If this were done the current would not follow the windings of the wire at all, but would choose the shorter path of less resistance, passing along the iron core, making a short circuit.) Over the primary winding is placed a heavy insulation of mica or vulcanite, and around this is wound more insulated wire, the secondary winding. (Figs. 32 and 33.)

There is positively no electric connection between the primary and secondary windings. The primary current passes through the primary

winding and into the negative lead wire. But in its passage it has induced or created a secondary current in the secondary winding.

Coils are rated and designated according to the maximum number of inches of atmosphere the secondary current can be made to jump. As the current jumps from one terminal to the other of the secondary winding, a spark occurs, due to the resistance of the atmosphere to the

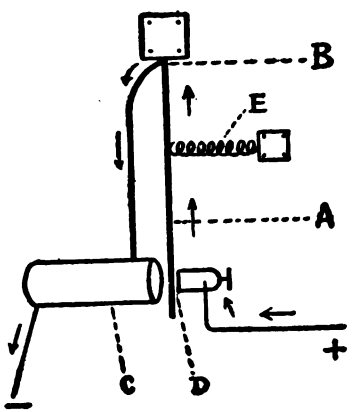

Fig. 25.

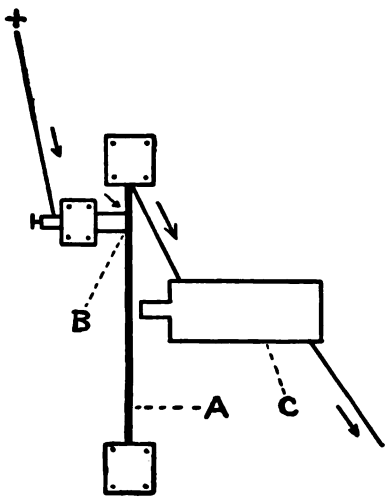

Fig. 26.

Fig. 25. A, movable arm with fulcrum at B. C, electro-magnet. D, break. E, spring.
Fig. 26. A, piece of ribbon steel. B, point where circuit is broken. C, electro-magnet.

flow of the current. When we speak of a coil as, say a 12-inch coil, we mean that the spark gap of that coil is twelve inches long; that its secondary current can be made to jump twelve inches of atmosphere. Coils with parallel spark gaps from as narrow as about 6 inches to as long as about 40 inches have been manufactured.

The induction coils manufactured today usually have a spark gap of from 8 to 12 inches. (See pages 43 and 44.)

The wire of the primary winding is from about 16- to 4-gauge; of the secondary from about 34- to 29-gauge. The length of the wire in the secondary is immensely greater than the length of the wire in the primary.



Fig. 27. One-cell rectifier.



Fig. 28. Three-cell rectifier.

At each "make" and "break" of the circuit of the primary current, a current is induced in the secondary. The secondary current induced at the break of the primary flows in the same direction as the current in the primary, while the current induced at the make flows in the opposite direction. Thus the secondary is an alternating current; but the current of the make is so much weaker than the current of the break that, for practical purpose, the secondary may be considered a uni-directional, pul-



Fig. 29. Twenty-nine button rheostat.

sating current. The current of the make is what is known as the inverse current, and it is the effort of all coil manufacturers to make a coil giving as little inverse current as possible.

The voltage of the secondary current cannot be determined accurately. Authorities differ very greatly in their estimate of the number of volts required to jump one inch of atmosphere, giving the figure as low as 10 000, and as high as 60,000. What voltage is required to jump each succeeding inch after the first, is also a question shrouded in very great uncertainty.

Estimating each inch of atmosphere at 10,000 volts, which perhaps is getting as near the truth as possible at the present time, the voltage

furnished by any size coil can easily be determined. Figuring on this basis, an 8-inch coil in full operation supplies a current with a potential of 80,000 volts; a 20-inch coil, 200,000 volts.

The amperage, or, to be more exact, the milliamperage of the secondary current of an induction coil varies according to the resistance

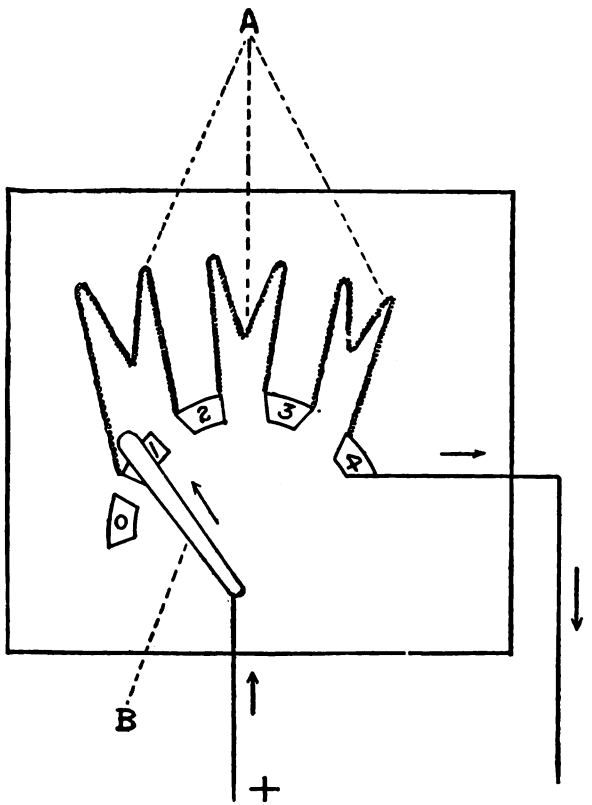

Fig. 30. Diagram of rheostat.

through which the current is forced. Thus, allowing the rheostat to remain on the same button, the milliamperage is increased or decreased accordingly as the spark gap (Fig. 17) is shortened or lengthened. With the spark gap at its maximum length, the milliamperage is least. As the sliding rods are pushed closer to one another, so lessening the length of the spark gap, milliamperage increases. Different coils are capable of forcing different milliamperages through their maximum length of spark gap. Thus one 10-inch coil may be able to force twenty milliamperes

through ten inches of atmosphere, while another could send only two milliamperes through such a resistance. All coils give a high milliamperage on a short spark gap, the amount running into hundreds of milliamperes. Instead of the sliding rods, some coils have an arrangement, as per Fig. 34, for regulating the length of spark gap.

The milliamperage strength can be estimated roughly by the appearance of the spark. A thin, blue spark indicates low amperage. A

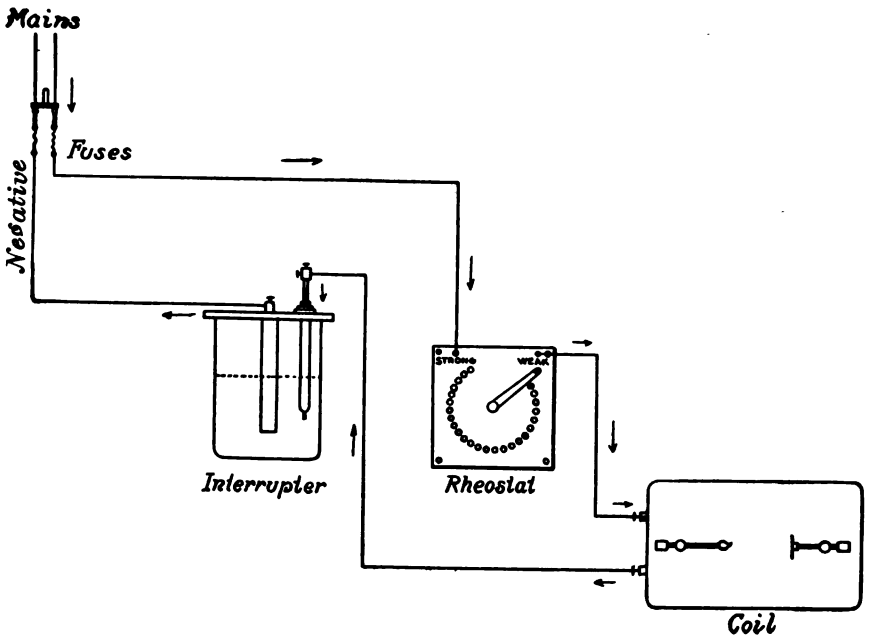

Fig. 31.

fat, fuzzy spark, the caterpillar spark, indicates high milliamperage. To do rapid dental radiographic work a coil should give at least six inches of the fat, fuzzy spark.

Amperemeters and milliamperemeters are used on the primary and secondary currents, respectively, to measure their volume. (Fig. 13.) While these meters may be considered luxuries rather than necessities, they are certainly very useful luxuries.

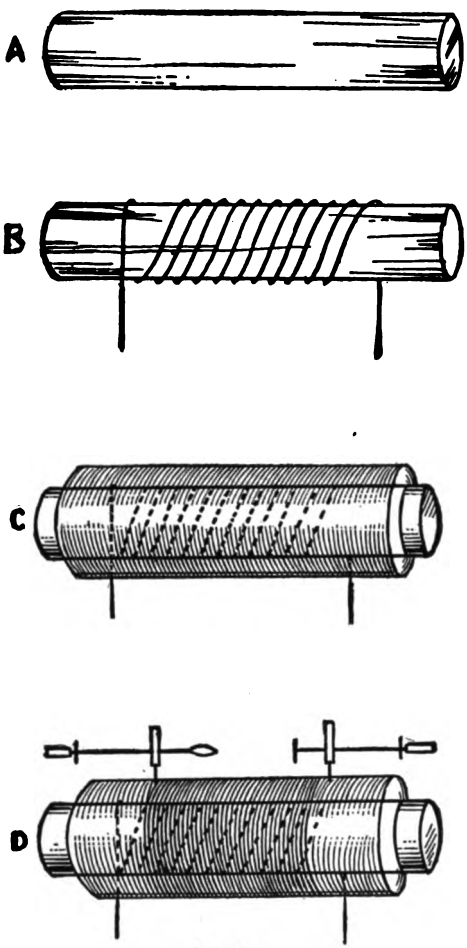

Fig. 32.

A, iron core. B, iron core with primary winding. C, iron core, primary winding and insulation. D, iron core, primary winding, insulation and secondary winding.

High-Frequency Coil.

Now let us consider the high-frequency coil. (Figs. 14 and 35.) In mechanical construction the high-frequency coil may be considered a kind of double coil with the secondary of the first coil acting as the primary of the second coil. The primary current of the first coil should be A.C.

From the supply wire the current passes through the primary winding of a step-up transformer (first coil) at the usual commercial 100 to 125 volts, 60-cycle. (Fig. 35.) An alternating current of the same frequency as the primary, but higher in voltage and lower in amperage is generated in the secondary of the transformer, and passes into the condenser, which acts as a reservoir. As the current leaves the condenser and jumps the regulating spark gap, it is oscillating at a frequency of

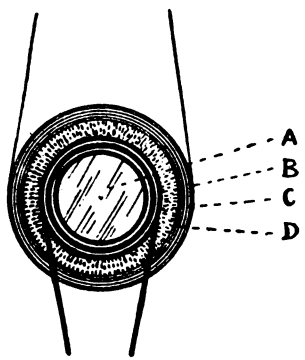

Fig. 33

Cross-section diagram of induction coil. A, iron core. B, primary winding. C, insulation. D, secondary winding.

from 10,000 to more than a million. It passes through the primary winding of the Tesla coil, inducing a secondary current of the same high frequency. This Tesla coil is the same as an induction coil (Figs. 32 and 33), except that some inert substance, instead of soft iron, is used for the core.

The secondary current of the second coil is the one supplied by the machine, the one to be used to generate X-rays. Like the current of the Ruhmkorff, or induction coil, this current is high in voltage and low in amperage. The current of the induction coil is, however, practically a uni-directional one, while the current supplied by the high-frequency coil is alternating at the inconceivably high frequency of tens of thousands or millions. Hence the term "high frequency," which is applied to the current and the coil producing it.

The frequency is governed by the size of the condenser; the smaller the condenser the higher the frequency. Thus most "high-frequency and X-ray machines" are equipped with a switch, by means of which all, or

a part, of the condenser may be used. When using the coil for X-ray work, this switch should be turned to "low frequency," so that all of the condenser is used. When using the coil for "high-frequency" treatments —using the current as a therapeutic agent—the switch should be on "high frequency," so that only a part of the condenser is used.

By means of the regulating spark gap, we can control to an extent the secondary current of the second coil—the current supplied by the

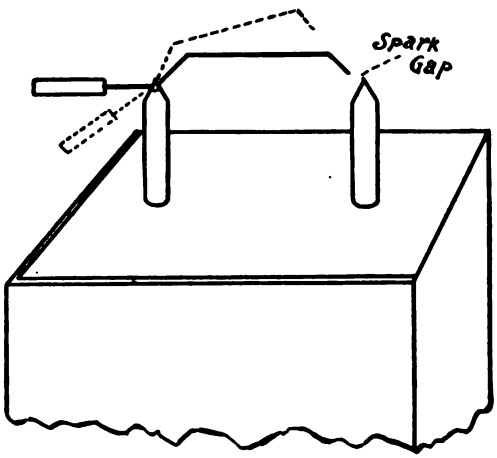

Fig. 34.

machine for use. Widening the gap increases voltage at the expense of the amperage; narrowing the gap increases amperage at the expense of the voltage. The wattage remains the same. For X-ray work the gap should be as short as possible, without reducing the voltage to a point where the current will not pass through the X-ray tube.

High-frequency or Tesla coils are often spoken of as " suitcase coils " and " portable coils," because they are frequently built in the shape of a suitcase and are transportable.

Some coils of this type are mere toys, incapable of doing good dental work, while others compare favorably, on the A.C. circuit, with small and medium size induction coils. One should be cautious, therefore, when purchasing a coil of this type.

As stated, the primary, or supply, current of a coil, built on the high-frequency plan illustrated, should be A.C. When attaching the portable coil (Fig. 14) on an A.C. circuit, therefore, all that needs to be done is to screw the attachment into a lamp socket.

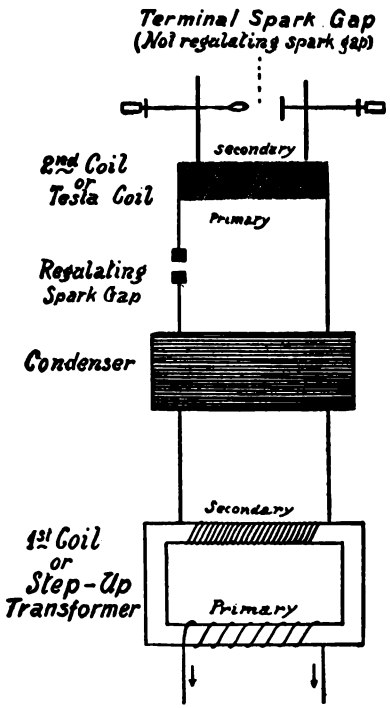

Fig. 35.

Rotary Converter.

When the supply current is D.C., a rotary converter should be used. A rotary converter (Fig. 36) consists of an electric motor set in motion by the supply current, which motor in turn revolves the armature of an A.C. dynamo, which generates the electricity that is sent into the coil. Instead of having the D.C. motor and the A.C. generator as separate machines connected by a common shaft, so that movement of the armature of one machine revolves the armature of the other, the rotary converter can be made so as to be enclosed in one casing. (Fig. 15.)

Tracing the current, as per Fig. 37, coming through the fuse and switch, the current passes through the positive wire to the starting box

or rheostat. It leaves the starting box through two wires, passing through one to the field of the motor marked S.F., through the other to the armature of the motor, marked ARM, and out of the motor through the negative lead wire. A new circuit is formed from the generator side of the converter marked A.C., passing through the coil.

It may be well to state just here that an electric motor is, in construction, practically the same as a dynamo or generator. In fact, taking



Fig. 36. Rotary converter, or motor-dynamo.

a given machine, it may be used as either a dynamo or a motor. If its armature is revolved by some power, it will generate electricity, and it is then a dynamo; if a current of electricity is sent into its field and armature, the armature revolves; and it is then an electric motor. Motors are made to be operated by both D.C. and A.C. circuits; that is, we have D.C. motors which can be run only by a direct current, and A.C. motors which can be excited only by an alternating current.

Instead of a rotary converter, some machines are equipped with a mechanical vibrator (Fig. 22), which interrupts the current as it enters the coil. This is not so efficacious as the converter. Machines with the mechanical interrupter are advertised to operate on either A.C. or D.C. circuits.

The length of the spark gaps of portable machines varies from four to ten inches. They are seldom able to give a fat, fuzzy spark longer than half the length of the spark gap. The full-length spark is almost always thin and blue.

Interrupterless Coils or Transformers.

The interrupterless coil, or transformer, as it is usually designated now, is the newest, the easiest to operate and the most powerful X-ray machine thus far made. Comparatively little space is needed to explain the principle of its construction, since it will not be necessary now for me to define and explain such common electrical apparatus as fuses, switches and the like, as it was in the description of the induction and high-frequency coils.

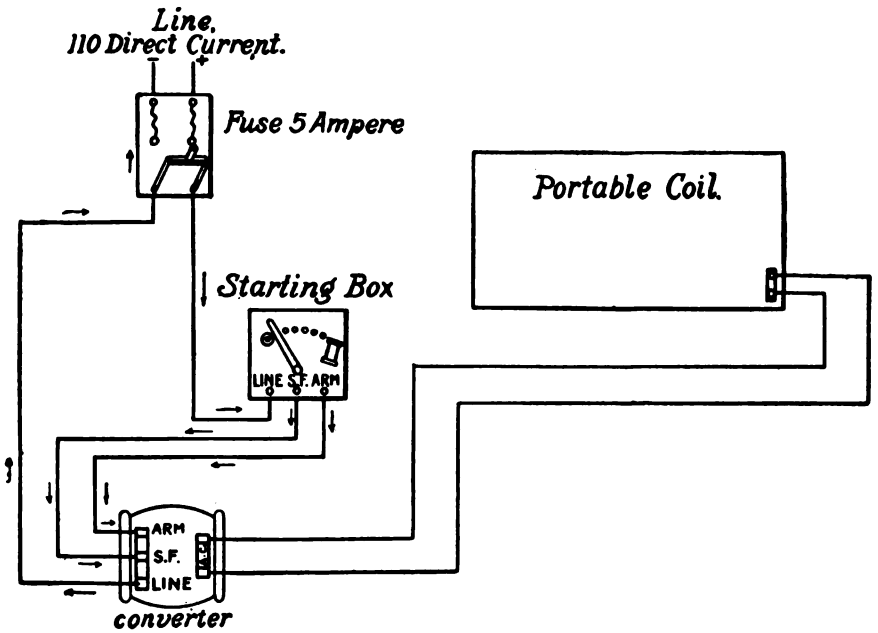

Fig. 37.

The transformer X-ray machine consists of a rotary converter, or synchronous motor, a step-up transformer, and a rectifier switch. (Fig. 38.) The step-up transformer may be of the closed magnetic circuit core type (Fig. 38B), or the open core type (Fig. 38A). These machines are of two kinds: those built to be operated on a D.C. circuit, and those designed for the A.C. circuit.

Let us consider the former first: The converter is set in motion by the commercial direct current. It generates an alternating current which is sent through the primary of the transformer. The induced current in the secondary is of the proper voltage and amperage for X-ray work, but it is alternating. It should be direct. It is made so by means of the

rectifying switch, and is then an ideal current for X-ray work. The rectifying switch is a revolving mechanical device similar to a commutator in principle.

Instead of a rotary converter the A.C. machine has an A.C. motor, on the shaft of which is the rectifier switch. From the mains, four wires

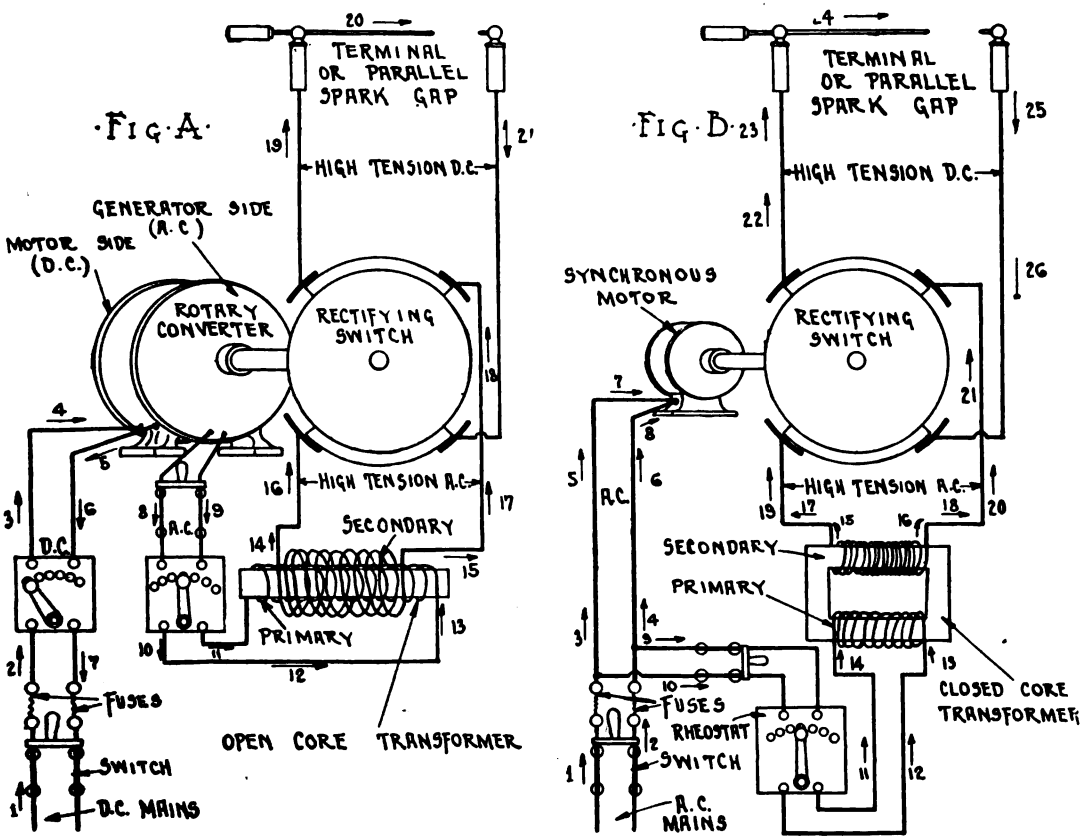

FIG. 38.

Fig. 38. Didactic drawing of the transformer or interrupterless X-ray machine. "A" the D.C. machine. "B" the A.C. machine. To trace the current, follow the arrows by number.

lead to the A.C. machine; two for the motor, two for the transformer. First the motor is set in motion. Then the current may be turned into the primary of the transformer and an alternating current is immediately generated in the secondary winding. This secondary, alternating current is of the proper voltage and amperage for X-ray work, and is made uni-

directional by passing it through the rectifier switch. In order for the rectifier switch to change the alternating current into a direct one it must revolve at a definite rate of speed, in perfect synchronism, or step, with the rapidity of alterations of the alternating current. Because of this, the motor is spoken of as a synchronous motor.

The first interrupterless coils to be made for the alternating current had an A.C. motor connected with an A.C. generator. But two main wires lead to this type of machine. The motor is set in motion with the supply current. The shaft of the motor extends to the generator, revolving its armature. The current produced by the generator passes into the primary winding of the coil, and the secondary, induced, alternating current is made direct by passing through the rectifier switch which is attached to the shaft of the generator and therefore moves in synchronism with it. It was necessary to build interrupterless coils for the A.C. circuit in this manner until motors were produced which revolve the rectifier switch in synchronism with the line or supply current.

The greatest shortcoming of the transformer type of coil has been the difficulty in making one with sufficiently high voltage to do certain kinds of X-ray work as well as the induction coil. This shortcoming, however, has been quite satisfactorily overcome.

The interrupterless coils are rated according to the amount of "energy" they create, not according to their spark gap length. The spark gap is usually ten or twelve inches long. The machines are rated to have a capacity of so many kilowatts. Take a "4 kilowatt" machine, for example. Its primary current, we will say, is 100 volts, 40 amperes (4,000 watts), the secondary current something like 100,000 volts, 40 milliamperes (4,000 watts).

This system of rating is being adopted by manufacturers of induction coils also. (See pages 43 and 44.)

CHAPTER III.

X-Ray Tubes and the X-Rays.

Thus far we have considered only the electric phase of the subject. We shall now describe the apparatus through which the electricity is passed, and which generates the X-rays, namely the X-ray tube.

An X-ray tube is a bulbular glass tube, from which the atmosphere has been exhausted to quite a high degree of vacuum—about 1/1,000,000 part of an atmosphere. It should be remembered that there is a something which occupies all space, even vacuua, and that something is known as ether. There is, of course, ether in the X-ray tube. X-ray tubes are often called Crooke's tubes, but they resemble the tube made by Professor Crooke only in having a high degree of vacuum. In mechanical construction they are quite different.

Classification of X-Ray Tubes.

Tubes may be divided, according to the machines on which they are used, into the static machine tube, the induction coil tube, the high-frequency coil tube and the transformer tube.

Since we have eliminated the static machine from consideration because it is obsolete we will likewise eliminate the static machine X-ray tube and describe first the induction coil tube. For a description of the Coolidge tube see index.

Induction Coil Tubes.

In describing the tube used with induction coils we, of necessity, consider the fundamentals of all X-ray tube construction and X-ray production.

Sealed in the X-ray tube are the anode, Fig. 39, A (also called anti-cathode and target), and the cathode, B. The anode is usually flat, placed at an angle of 45 degrees to the long axis of the tube, and made of some high-fusing metal, such as tungsten, platinum, iridio-platinum or tantalum. The cathode is concave, saucer shape, and usually made of aluminum.

Since, in connecting the tube to the coil, it is necessary to attach the connecting terminal tape or wire from the positive side of the coil to the target end of the tube, we must be able to determine which is the positive terminal of the coil. This may be done on an induction coil, as follows: Cut out the resistance of the rheostat, adjust the sliding rods to about one-half the distance of the maximum spark gap, and throw on the switch. The spark will jump the gap so quickly that it is impossible to learn by simple observation in which direction it is traveling. By watch-

ing the large disc terminal, however, this can be determined. If on throwing the switch on and off the spark is noticed to cling to the edge of the disc *always*, then the current is passing from the disc. If, however, the spark occurs from the surface of the disc just as the current is turned on (it may then seek the edges), the current is traveling from the small bulb to the disc. (Fig. 40.)

With the tube properly connected to the coil as per Fig. 41, the current is shunted (Fig. 42) through the tube, instead of jumping the

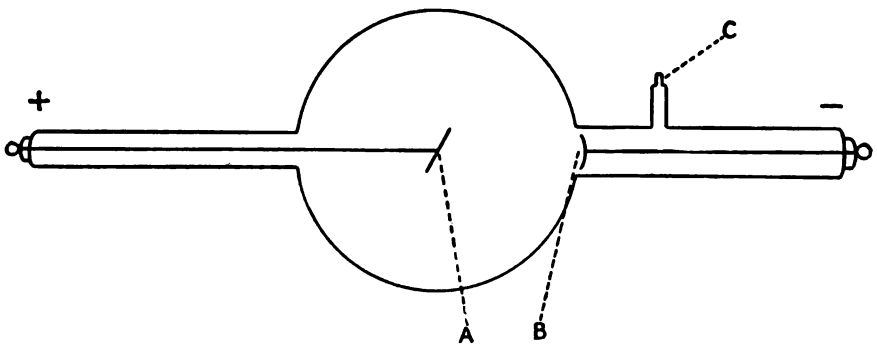

Fig. 39. A, anode. B, cathode. C, point at which the atmosphere was pumped from the tube.

spark gap, passing from anode to cathode. Whether the current will choose the path through the tube or jump the spark gap depends on which offers the less resistance. A current of electricity always travels the path of least resistance.

Classification of X-Ray Tubes According to Degree of Vacuum

Tubes are designated according to the degree of their vacuum. Thus we have the high or hard tube, in which the vacuum is well-nigh complete; the medium tube in which the vacuum is less complete, and the soft or low tube, in which the vacuum is least complete. High tubes offer the greatest resistance to the passage of the electric current through them, then comes the medium, while the low vacuum tube offers the least resistance. For dental picture work a medium tube yields excellent results.

The operator may determine whether a tube is hard, medium or soft, as follows: Connect the tube to the coil. (Fig. 41.) Separate the sliding rods to give a spark gap of two or three inches and turn on the current. Unless the tube is very low indeed, the current will jump the spark gap instead of passing through the tube. Let us suppose the cur-

rent does jump the spark gap. Now widen the gap a little; turn on the current, and it passes through the tube. The tube will, therefore, be rated as one of low vacuum, offering a resistance slightly greater than two or three inches of atmosphere. When the current jumps the spark gap instead of passing through the tube, the tube is said to have "backed up" so many inches—the number of inches of the gap—of "parallel spark." Thus a low tube will back up two or three inches of parallel

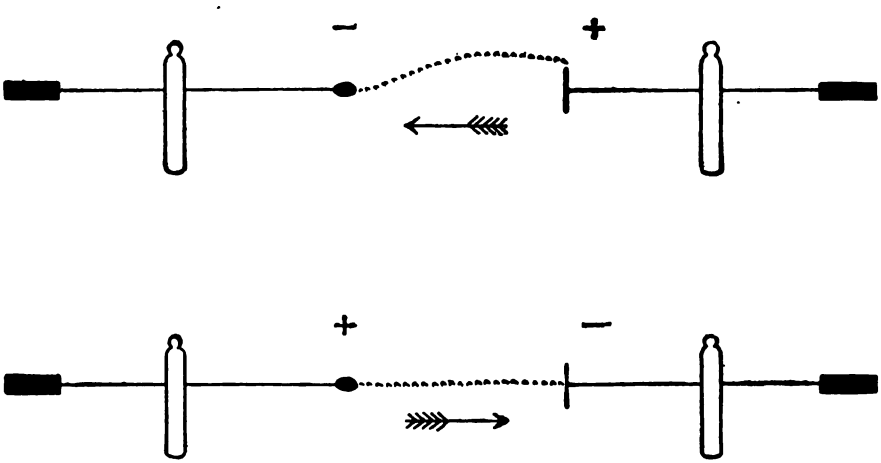

Fig. 40.

spark; a medium tube will back up four or five inches of spark; a high tube will back up six or seven inches of spark, and a very high tube will back up eight or nine inches of spark. Very high tubes offer so much resistance that only the largest coils are able to force sufficient milliamperage through them to generate a sufficient number of X-rays for picture work. A tube that will back up more than nine inches of spark is too high to be useful; it is impossible to force enough milliamperage through it. The best back up for dental work is about 5 inches.

From the foregoing it will be seen that any coil smaller than one with a 7 or 8-inch spark gap could not well excite a high tube, and that at least a ten-inch coil is necessary to light a very high tube. It seems, too, that any coil with a spark gap wider than eight or ten inches is needlessly large. The coils with the long spark gaps are, however, seldom able to throw a fat, fuzzy spark farther than eight or ten inches. The throwing of a thin, blue spark a greater distance is simply incidental and

without practical usefulness. Thus an eight or ten-inch coil may be as powerful as one with an eighteen or thirty-inch spark gap; that is, capable of forcing as high a milliampérage through a high tube. If, however, a coil can force any kind of a spark at all through from eighteen to thirty inches of atmosphere, we may be sure it will send a high milliamperage through a good radiographic tube, or, what is the tube's equivalent

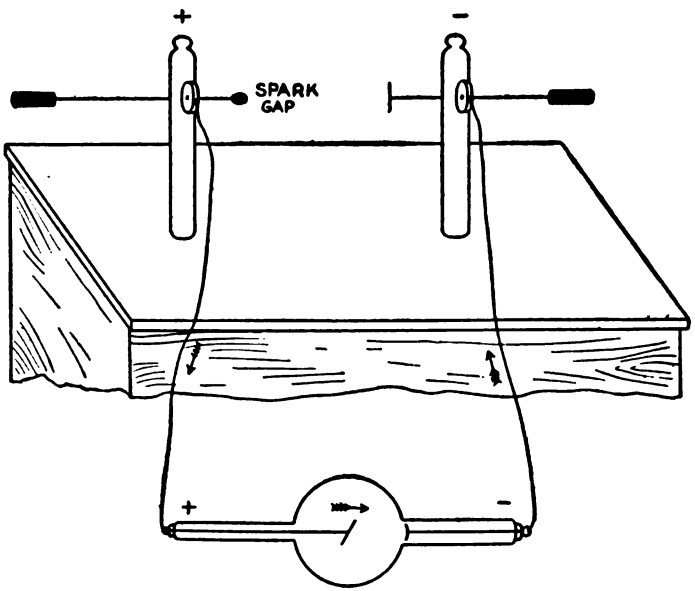

Fig. 41. The X-ray tube connected with the induction coil.

in resistance, six or eight inches of atmosphere. It is so well understood to-day that the coil with the very wide spark gap is not necessarily more powerful, that manufacturers are making practically all of their coils with from an eight to a twelve-inch spark gap, then rating them according to the milliamperage they can force through this resistance.

To light a tube well a coil should be capable of giving a fat, fuzzy spark, the distance of the parallel spark which the tube backs up.

The tube thus far described is the simplest form of X-ray tube, and no longer in general use. Next in simplicity is the bi-anodal tube. (Fig. 43.)

Bi-anodal Tubes.

When the two anodes are connected, as in Fig. 43, the positive terminal may be attached to either anode or assistant anode, preferably the anode. The advantage of the assistant anode is a matter on which authorities have widely different opinions. One manufacturer, a man

who is making one of the very best tubes on the market, tells me that he puts the assistant anode in his tubes because some of his customers demand it, and he is able to do so without impairing their efficiency; that his tubes would be just as good with but one anode. Remember the vacuum of an X-ray tube is not perfect; there are some gases in the tube. The function of the assistant anode is to draw these gases back of it away from between anode and cathode. Thus, if the removable wire

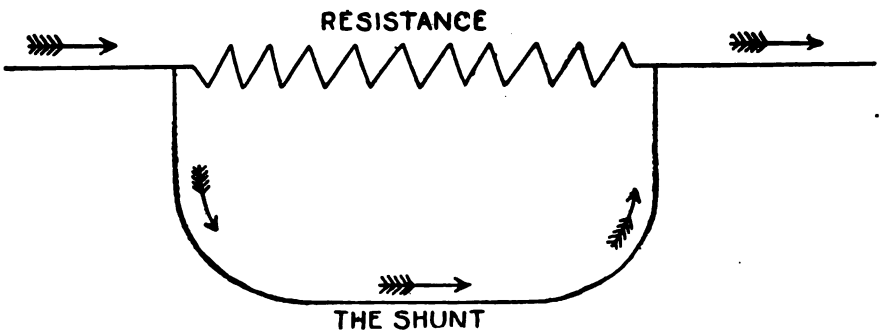

Fig. 42. The arrows show the current flowing through the shunt.

connecting the anode and assistant anode (Fig. 43) be removed and the tube hitched to the coil, the positive terminal being attached to the anode, the tube will work with a slightly lower vacuum, because the assistant anode does not draw gases back of it. Tubes with assistant anodes are supposed to be capable of transmitting a greater milliamperage.

In the past tubes were classified as tubes with a means of regulating vacuum (Fig. 44) and tubes without a means of regulating their vacuum (Figs. 39 and 43).

Tubes without regulators are no longer in general use, because, with use, they soon become too hard, and must be sent back to the manufacturers to be opened and repumped. This is expensive and annoying. A tube too high for use will sometimes drop in vacuum and regain its former usefulness if allowed to rest—remain unused—for a month or so.

Methods of Regulating Vacuum.

There are different methods of regulating the vacuum of X-ray tubes. The most popular is the one we shall now consider.

The vacuum is governed by means of a movable arm, which increases or decreases the distance be-

tween A and B, Fig. 44. This distance we shall call the tube-regulating spark gap. The shorter the gap the lower the vacuum can be made; that is, the shorter the gap the less perfect the vacuum can be made.

The current enters the tube and, let us imagine, tries to pass from anode to cathode. The vacuum in the center of the tube is more perfect

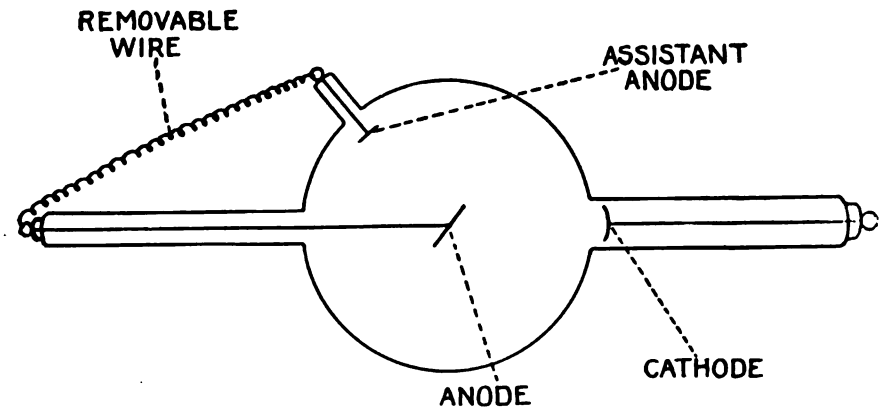

Fig. 43. A Bi-Anodal X-ray tube.

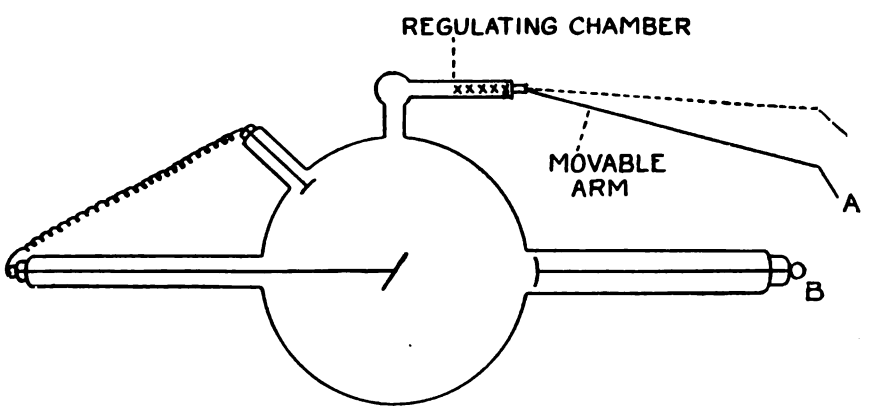

Fig. 44. X-ray tube with vacuum regulator.

than around the walls. Hence the path of least resistance is through the regulating chamber, through the movable arm, through the tube-regulating spark gap, into the negative terminal tape; unless, of course, the tube-regulating spark gap is very wide.



Fig. 45. Showing the manner of connecting the third terminal on the coil with the regulating chamber.

The regulating chamber contains asbestos impregnated with some chemical, sodium or potassium hydrate, for examples. When the current passes through the regulating chamber, heat is created, which causes the chemical to give off gases. These gases lower the vacuum of the tube, so that the current may pass directly from anode to cathode. When the

tube cools thoroughly—in the course of fifteen to thirty minutes—these gases are taken up again by the chemicals in the regulating chamber, and the vacuum rises again. Thus the vacuum of the tube may be too high when the tube is not in use, but can be lowered to the desired degree. Ordinarily the tube-regulating spark gap should be three

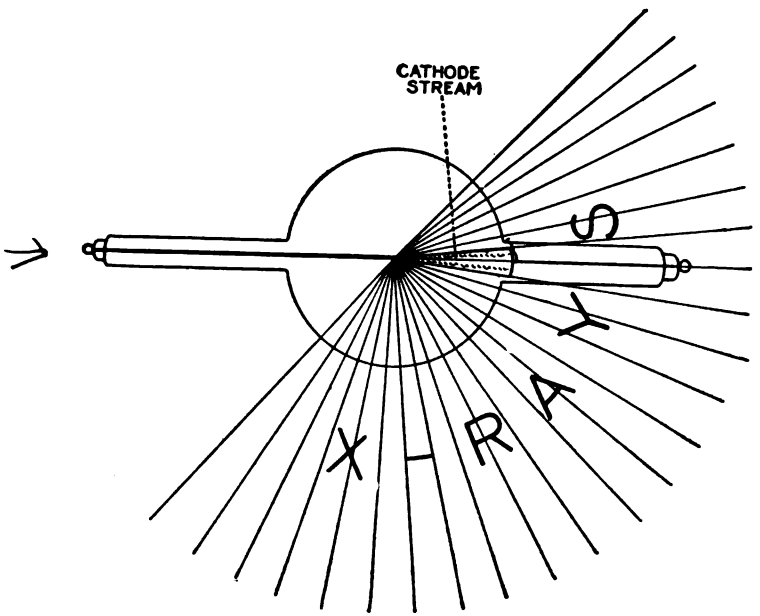

Fig. 46. Showing the direct X-ray and the cathode stream.

to five inches. As the tube gets old the tube-regulating spark gap must be made shorter to obtain the same condition of tube.

When the tube is properly hitched to the coil, and the movable arm set for a high vacuum—to give a regulating spark gap of about four inches—and the current turned on, practically all the current may at first pass through the regulating chamber and jump the tube-regulating spark gap. As explained, this lowers the vacuum, and in a few seconds the current is passing from anode to cathode. All of the current may pass directly through the tube now for a few seconds, but the passage of the current from anode to cathode raises the vacuum and presently some current will be seen to jump the gap for a while. And so on, just as the vacuum raises a little, it is immediately lowered by some of the current passing through the regulating chamber.

Instead of the movable arm, a terminal tape and a third terminal on the coil may be used. (Fig. 45.) Thus the tube-regulating spark is transferred from the tube to the coil. The hitching of a tube to a coil with a third terminal is very simple. Hitch the positive terminal to the anode, or assistant anode if desired, and the negative terminal to the cathode, as usual; and the third terminal to the regulating chamber. The advantages of the third terminal over the movable arm are that the sparking is taken away from the tube and so away from the patient (in radiographic work the tube is always near the patient), and, on some coils, Fig. 13 for example, the gap may be regulated from the end of the coil where the rheostat and switches are located, so making it unnecessary for the operator to move from his position to change the tube-regulating spark gap.

When the current passes from anode to cathode, the cathode stream (Fig. 46) is given off from the cathode. The cathode stream is a form of vibratory motion of the ether. Leaving the concave surface of the cathode, the cathode stream is focused to strike the anode or target at a point. X-rays are given off from this point (Fig. 46). The cathode stream can be seen in a tube of very low vacuum, appearing blue.

Great heat is generated at the point on the target where the cathode stream strikes it. Hence the necessity of making the target of some very high fusing metal. A small hole may be burned superficially into the target without spoiling the tube. The tube in Fig. 47 has a long sheath of metal connected with the target to take up the heat. Tubes are made with a means for cooling with water. These are intended for treatment rather than picture work, though they may be used for the latter.

X-rays were discovered by William Conrad Roentgen, professor of physics at the Royal University of Wurzburg, Germany, in the summer of 1895. Roentgen applied the name X-rays because he did not know just what he had discovered; X, the algebraic symbol for the unknown, being adopted to signify this ignorance. They were not called X-rays because the rays cross, forming an X, as is popularly supposed.

The Roentgen Congress, in Berlin, 1905, adopted a uniform set of technical terms in which the word Roentgen always occurred. Thus we have the phrase Roentgen ray for X-ray and such words as Roentgenology, Roentgenologists, Roentgenogram, etc., etc. While approving of a move for a uniform nomenclature, many of the new words are long and unwieldy and the writer shall, in this work, use many of the old and better-known terms.

X-rays are invisible, vibratory waves of or in the ether. The most

popular theory is that they are light waves with an inconceivably rapid rate of vibration. Red light rays vibrate at the rate of four hundred billion per second; violet rays vibrate at the rate of seven hundred and

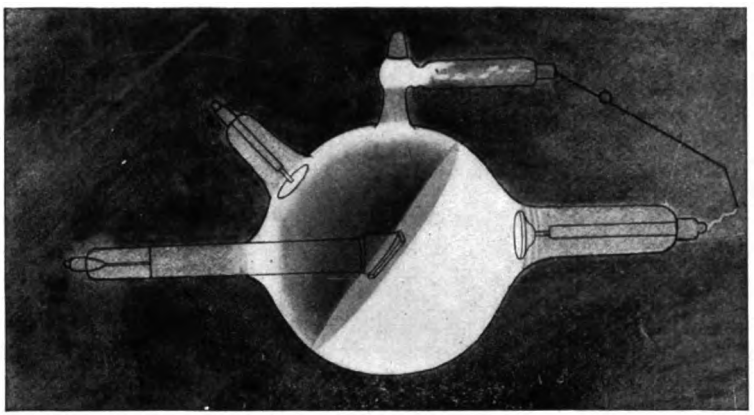

Fig. 47. X-ray tube properly lit up.

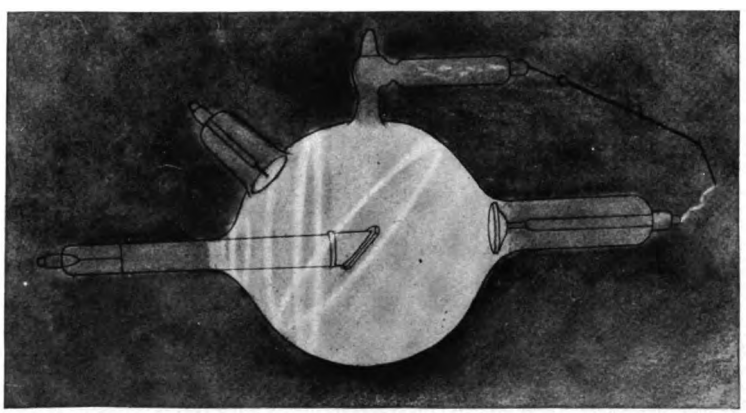

Fig. 48. X-ray tube with the current passing through it in the wrong direction.

fifty billion per second. The intermediate colors—blue, green, yellow and orange—vibrate at intermediate degrees of rapidity.

Though human vision is limited to about three hundred and fifty billion variance, the difference between four hundred billion and seven hundred and fifty billion, may we not fairly assume that there are light

rays of a higher and lower vibration invisible to us? Ultra-violet rays have a more rapid vibration than violet rays, and have no action on the retina, and are therefore invisible. X-rays vibrate more rapidly than ultra-violet rays. The rapidity of their vibration is estimated at 288,224,000,000,000* (two hundred and eighty-eight quadrillions, two hundred and twenty-four trillions—French notation) per second.



Fig. 49. The inverse spark gap on the left is open, on the right is closed.

As just mentioned X-rays are invisible; in fact, they are not discernible to any of the special senses. They pass from the focal point on the target in regular, diverging lines (Fig. 46). When they strike an object they are absorbed by it or pass through it. Broadly speaking, it may be said they penetrate objects inversely, according to the density of the object. They cannot be refracted or condensed, and the fact that they can be reflected is of academic interest only since they are not reflected except under what I should call experimental conditions.

The passing of the X-rays through the glass of the tube gives rise to a green fluorescence (green light) in the active hemisphere—the hemisphere in front of the target—of the tube. Whether a tube is working well or not can be determined by this fluorescence. There should be a definite line of demarcation between the active and inactive hemispheres of the tube. A tube working properly should light up as per Fig. 47. The light is never quite steady; it wavers a little. High, medium and low tubes give slightly different fluorescences when in operation. The fluorescence from a high tube is a very light yellowish green; from a low

*Custer's "Dental Electricity."

tube a bluish green and from a medium tube an intermediate shade of green.

Just here let it be said that an exact colored picture of an X-ray tube in operation has never been made. I obtained the services of an artist and spent a great many hours on the work, but was unable to make a picture worthy of reproduction. The light from an X-ray tube in



Fig. 50. Patent series or inverse spark gap for positive terminal.

operation is of a peculiar brilliancy that cannot be reproduced in crayons, water-colors, or ink.

When the vacuum of a tube is so low as to render it useless for radiographic purposes, a definite blue color can be seen here and there in the tube, the cathode stream can sometimes be seen appearing blue, and the line of demarcation between the active and inactive hemispheres of the tube is not well defined.

When a tube is punctured the vacuum gets very low, of course, and its appearance in operation may be as just described, or, as sometimes occurs, it gives rise to a fluorescence as variegated as a rainbow, or it may not light at all. A punctured tube can sometimes be repaired by the manufacturer.

When the vacuum of a tube is too high, the tube lights up reluctantly a very yellowish green, and the line of demarcation is not at all distinct.

Fig. 48 illustrates fairly well the appearance of a tube with the current passing through it in the wrong direction. When this condition is seen the current must be turned off quickly, or the tube will be ruined. Sometimes, when the tube is properly hitched to the coil, light rings back of the target, similar to those shown in Fig. 48, may be seen. This

signifies that the coil is generating considerable inverse current. Recall that, while the current generated by the induction coil is practically a unidirectional one, there is an inverse current which is sometimes strong enough to manifest itself as just mentioned, especially when the vacuum of the tube is low.

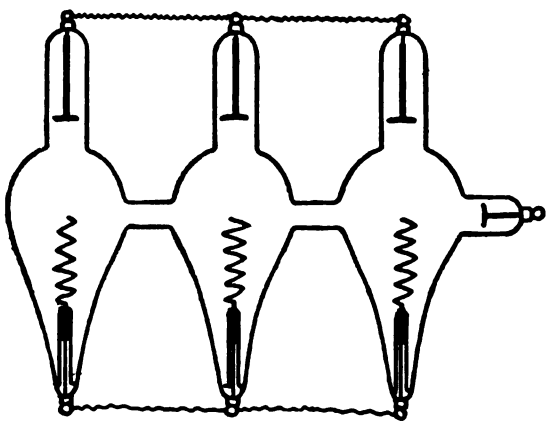

Fig. 51. A triple valve tube.

Cutting Out Inverse Current.

It is not at all desirable to allow inverse current to pass through a tube, for it gives rise to a scattering generation of X-rays which interfere with the making of a clear X-ray picture. There are four moderately satisfactory means of preventing the passage of inverse current through the tube.

The first and simplest means of eliminating inverse current is to make what we shall call an inverse spark gap. (This gap is usually referred to as the "series" spark gap because it is in series with the X-ray tube.) The word series, so used, is a technical, electrical term, and fails to explain the function of the gap as well as inverse spark gap. The gap can be seen between the positive terminal of the coil and the standard holding the positive terminal tape reel (Fig. 49). A similar gap may be made on the negative side. This gap cuts inverse current out of a tube by increasing resistance to the point where the voltage of the inverse current is not sufficient to jump the gap. Unless it is needed to cut out "inverse" from the tube there should be no inverse spark gap; the gap should be closed as on the right, the negative, side of Fig. 49.

The second means of eliminating "inverse" is by the use of the patent spark gap. (Fig. 50.) The current passes easily from point to disc, but reluctantly from disc to point. Thus this series spark gap may be used to cut out inverse current from a tube, with the points toward the positive terminal tape and the points away from the negative terminal tape. Fig. 50 shows the point toward the positive terminal tape. They should be turned in the opposite direction at the negative terminal—away from the tape.

The third means of cutting the inverse current out of an X-ray tube is by means of a valve tube. (Fig. 51.) The valve, or Villard tube, is a tube of low, or, as it is often called, Geissler vacuum—1/1,000 to 3/1,000 of an atmosphere—with a disc electrode and a spiral electrode, both made of aluminum. The exact reason for its action is not known, but the electric current cannot travel through it well except in one direction—from

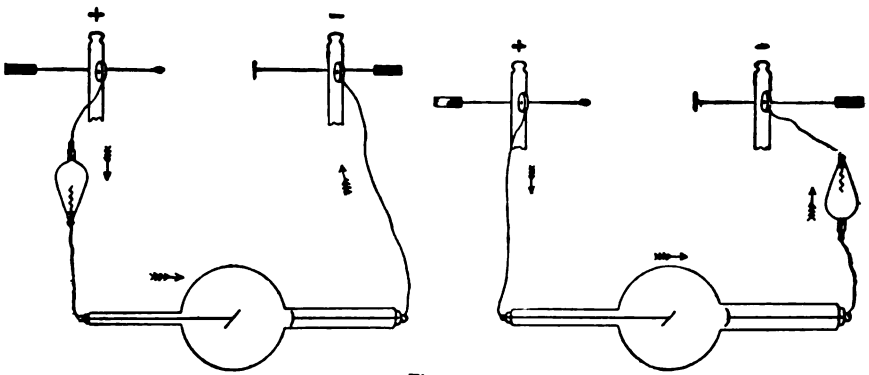

Fig. 52.



Fig. 53. An oscillimeter.

disc to spiral. Thus, to cut out inverse current the disc end of the valve may be attached to the positive terminal tape of the coil, and, by means of a piece of conducting tape, or wire, the spiral end connected with the target side of the tube. Or the disc end of the valve may be attached, with a piece of conducting tape, to the cathode side of the tube and the spiral end of the valve to the negative terminal tape of the coil. (Fig. 52.) Fig. 83 shows a valve tube built into—i. e., as a part of—an X-ray tube.

It is claimed by some that the valve tube acts only as an additional resistance to the flow of the inverse current, cutting it out of the X-ray tube in the same manner that the inverse spark gaps do.

The fourth means of eliminating " inverse " from tubes is by what is called a multiple inductance control on the induction coil. By means of this control, which is found only on the more expensive coils, the output current of the coil may be raised or lowered in voltage. If " inverse " is seen in the tube the voltage should be lowered.

Oscillimeter

The oscillimeter or oscilloscope (Fig. 53) is a Geissler vacuum tube by means of which inverse current may be detected when the X-ray tube is covered with an opaque

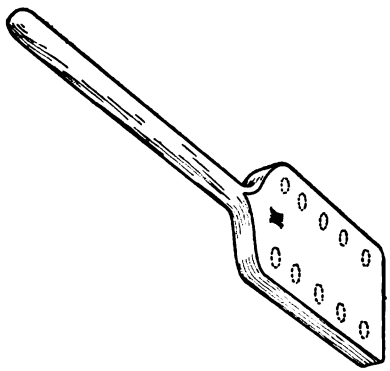

Fig. 54. The Meyer penetrometer.



Fig. 55. A fluoroscope.

shield. (Fig. 64.) I have never felt the need of it, though I have used an opaque shield over my tube.

Demonstration of X-Rays.

As has been stated, the X-rays are not discernible to any of the special senses. Their existence, however, can be demonstrated as follows:

Place an X-ray tube in a wooden box so that when the current is sent through it no fluorescence can be seen. Excite

the tube in a dark room and approach it with some object coated with calcium tungstate or platino-barium cyanide, and the object will be seen to fluoresce or glow something like phosphorus. This fluorescence is due to the action of the X-rays (which penetrate the wood of the box easily) on the calcium tungstate or platino-barium cyanide. Hence the closer the object to the tube the more and stronger the X-rays which strike it, and the brighter the fluorescence.

Power of Penetration of X-Rays.

X-rays from different tubes differ in power of penetration. A low tube gives the least penetrating X-rays; then comes the medium tube, while the X-rays from a high tube are the most penetrating.

The degree of penetration may be determined by means of a penetrometer. (Fig. 54.) This particular kind of a penetrometer consists of two small flat pieces of wood fastened together, with a sheet of lead between them. Holes are made through both wood and lead. Into these holes are placed thin metal discs which just fit the holes. The different holes receive different numbers of discs.

To use this style of penetrometer we must have a fluoroscope. A fluoroscope (Fig. 55) consists of a light proof box, tapered and made to fit over the eyes at one end, and covered at the other end with pasteboard coated with calcium tungstate or platino-barium cyanide. If one should look into the fluoroscope holding it toward ordinary light nothing could be seen—one would look into perfect darkness. But if the fluoroscope should be held so that the X-ray struck its screen—i. e., the pastboard covered with calcium tungstate or platino-barium cyanide—it would be seen to fluoresce, or glow, or light up.

If now the penetrometer is held between the fluoroscope and the source of the X-rays a shadow will be seen on the screen, because the lead in the penetrometer is opaque to X-rays. Whether the X-rays will penetrate the metal in the holes depends on how much metal there is to penetrate and how penetrating the X-rays are. Thus the more penetrating the rays the more holes can be seen.

There are a great many different kinds of penetrometers. I shall not describe them here, but will give the scale of the two most popular, the Benoist and the Walter, together with that of the Meyer (Fig. 54).

	Benoist.	Walter.	Meyer.
Soft, or low tube	1— 2	1	1— 2
Medium	3— 5	2—3	3— 4
Hard or high	6—12	4—6	5—10

While the penetrometer is a very valuable appliance, it is far from being a necessity in the practice of dental radiography.

Secondary Rays.

As X-rays pass through the glass of the tube more X-rays are generated. These are known as "secondary rays." They are short and feeble and do not travel parallel with the direct X-rays, but pass

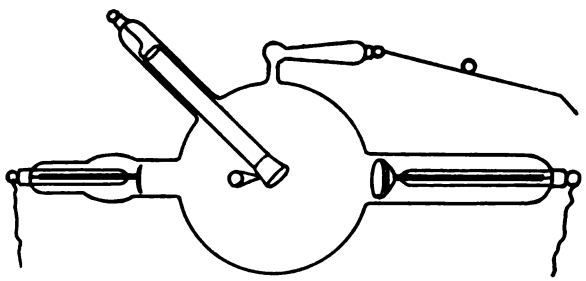

Fig. 56. High-frequency X-ray tube.

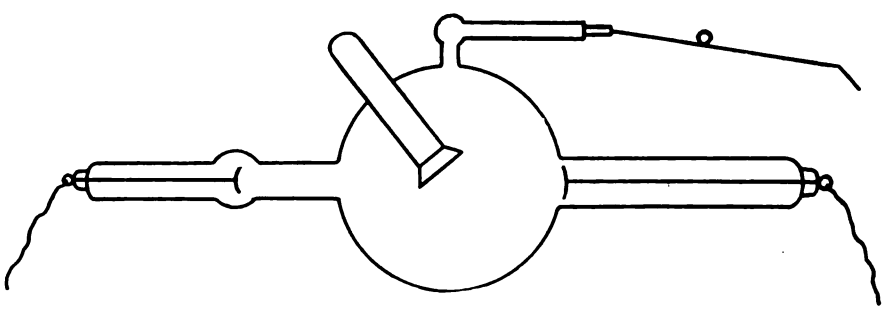

Fig. 57. High-frequency X-ray tube.

out from the tube in every direction intersecting the direct rays. Secondary rays are also given off from any object which X-rays strike. Thus, direct rays will strike a wall; secondary rays are given off from the wall and strike the other walls, the floor, and the ceiling, whereupon a new set of X-rays, tertiary rays, are produced. When the tertiary rays strike an object still another set of X-rays are generated, and so on, each new set of rays being much shorter and weaker than the former. So a room in which an X-ray tube is excited is filled with X-rays—not with the direct rays, but with the comparatively feeble and inconsequential secondary, tertiary and other subordinate rays.

Classification of X-Ray Tubes According to Size.

X-ray tubes are of different sizes. The bulb varies in diameter from five to eight inches. Thus we have the five-inch tube, six-inch tube, and so on. The six-inch tube is about right for dental work.

With use the glass of the active hemisphere of the tube discolors to a purplish color. This does not materially affect the tube.

The fatal injury to most tubes is a puncture. One means of guarding against punctures is to keep the tube clean. "A fruitful cause of



Fig. 58. Tube rack for tubes when not in use.

puncture is the discharging of the current from the tube into the rack on which the tube is kept when not in use. The tube may have been discharged by the operator touching the terminals before putting the tube away, but if the tubes are stored in the same room where high-frequency and other coil discharges are taking place, they will recharge themselves from the atmosphere and discharge onto the rack, no matter of what material the rack may be made. A safe way of putting away tubes is to connect the anode and cathode terminals together by a wire during the time the tube is at rest."

High-Frequency X-Ray Tube.

The general principle of construction of the high-frequency X-ray tube (Figs. 56 and 57) are those already given in the description of the tubes built to be operated by a unidirectional current. The

chief difference between the high-frequency tubes and those already described lies in the different means resorted to in the former to dispose of one direction or wave of the alternating current, or, to speak more definitely, one cathode stream.

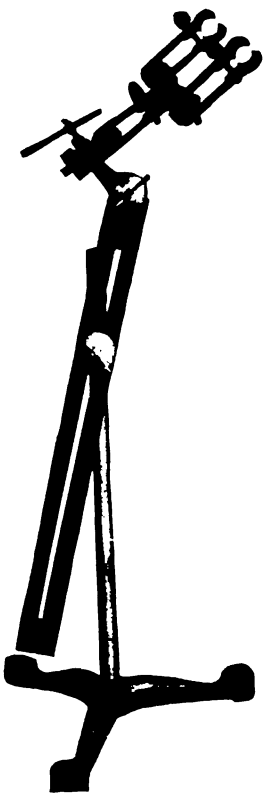

Fig. 59.



Fig. 60.

Fig. 59. Plain X-ray tube stand.

Fig. 60. Tube stand, with a lead glass protection shield and a compression cone.

Either end of a high-frequency X-ray tube may be connected with either terminal tape of a high-frequency coil. While this is theoretically true, it will sometimes be found in practice that the tube works better hitched up one way than the other.

When the tube is hitched up the current oscillates through it and two cathode streams are generated. One of the streams is focussed against the target and X-rays are given off from the focal point, while

the other is focused into a funnel in the back of the target. (Fig. 56.) X-rays cannot be given off from this funnel; hence the tube lights up in the active hemisphere as illustrated in Fig. 47. This funnel scheme is

Fig. 61. A pedestal, with a lead glass protection shield, compression cone and plate holder.

one way of taking care of one cathode stream while the other is being used for X-ray production. Another scheme is to move one cathode back so far that the cathode stream focuses before reaching the back of the target. (Fig. 57.)

The high-frequency tube may be used to advantage on an induction coil which is generating a great deal of inverse current.

Transformer X-Ray Tubes

The transformer tube is almost identical in construction with the induction coil tube. It is, however, made to take a current higher in milliamperage and lower in voltage; that is, the target is thicker and the metal sheath leading from it heavier to take up the heat due to the use of the high milliamperage, and the vacuum is normally a little lower.

To avoid "straining" a tube, it should not be used again, after having been used till hot, until it has cooled thoroughly. Overheating the tube will destroy the gases in it, and so raise the vacuum to such a degree as to make it impossible to force a sufficient milliamperage through it to produce a sufficient number of X-rays. Sending a very strong current



Fig. 62. Table, with a lead glass protection shield and compression cylinder.

through a tube of low vacuum will also destroy the gases of the tube and spoil—strain—it.

Fig. 58 is a tube rack for holding the tube when not in use.

It is obvious that there must be some kind of a device for holding the tube when in use. This may be either a plain tube stand (Fig. 59), or a tube stand with a lead glass, protection shield and a compression

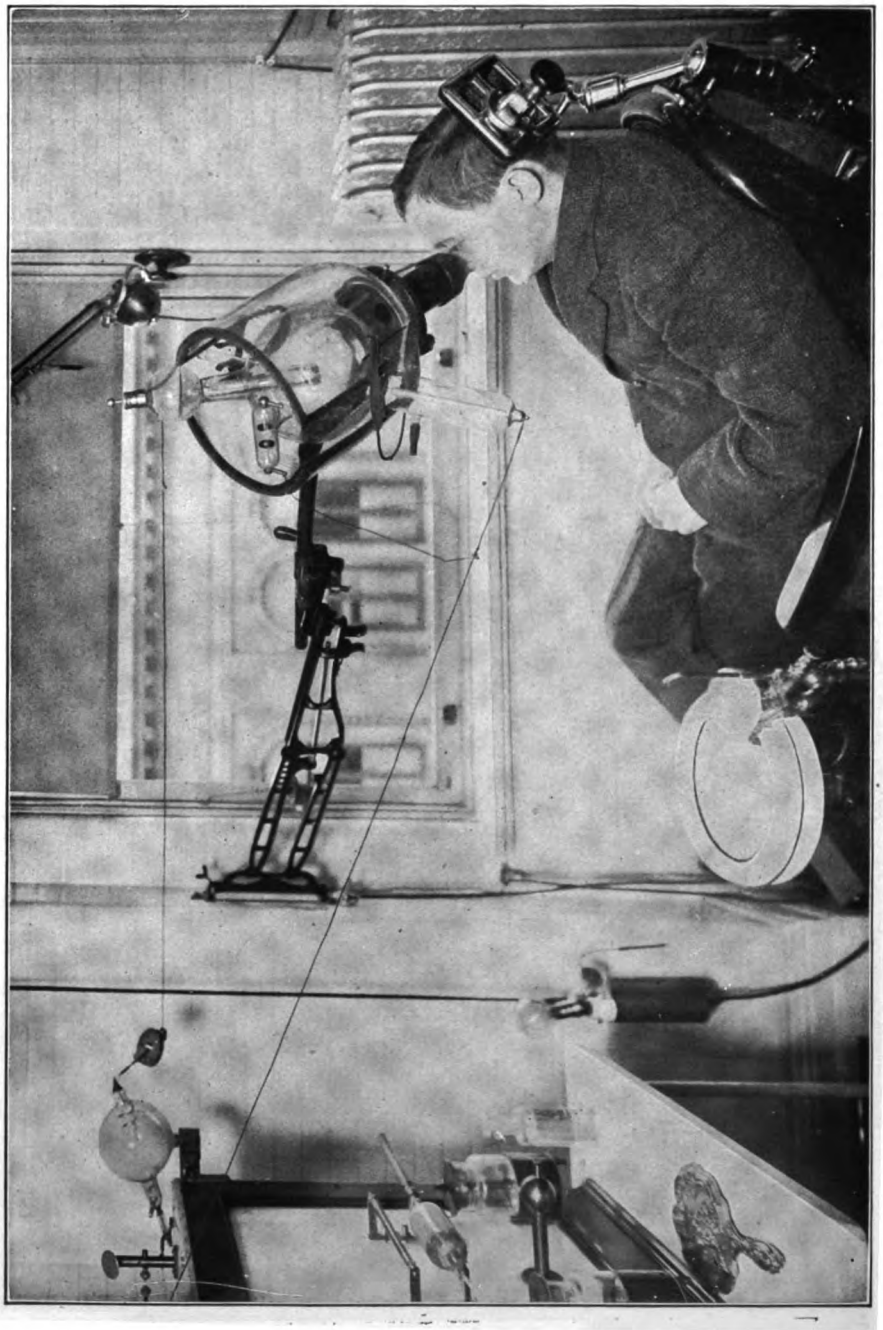

Fig. 63. Doctor Blum's wall bracket tube holder with lead glass protection shield and compression cylinder.

cone (Fig. 60), or a pedestal with a lead glass protection shield, compression cone, and plate holder (Fig. 61), or a table with a lead glass, protection shield and compression cylinder. (Fig. 62.)

Dr. Blum, of New York, uses a wall bracket fixture to support a lead glass, protection shield and compression cylinder. The tube, one of the water-cooled type, is seen fitting into the lead glass shield.



Fig. 64. A Protection Shield.

(Fig. 63.) This would be, I imagine, a very adaptable and satisfactory apparatus.

A tube stand should be heavy enough to be firm and not allow any vibration of the tube while in use. The parts coming in contact with the tube must be made of an electric non-conducting material; otherwise the current would pass from the tube into them, so puncturing the tube.

The uses of the compression cone or cylinder are: (1) To cut out secondary and inverse current rays (Fig. 65). (2) To aid the operator in directing the X-rays at the correct angle. (3) In general radiography, to hold the patient immovable and compress the soft parts as when making a picture of the kidney, for example.

A protection shield, often called a Friedlander's shield (Fig. 64), which is opaque to X-rays except for the window or opening in it, and which is used to cover X-ray tubes, also cuts out some, but not all, secondary rays given off from the glass of the tube. Thus if the X-rays from an

X-ray tube are directed on a part through a diaphragm and cone or cylinder, only the direct rays strike the part, as in the diagram study shown in Fig. 65. While, with the Friedlander shield, *some* of the secondary rays

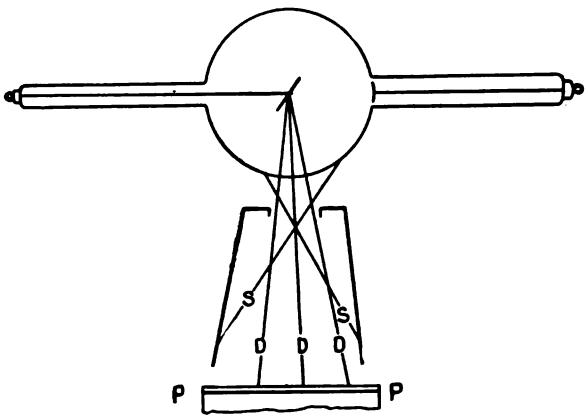

Fig. 65. D D D, direct ray. S S, secondary ray. P P, part.

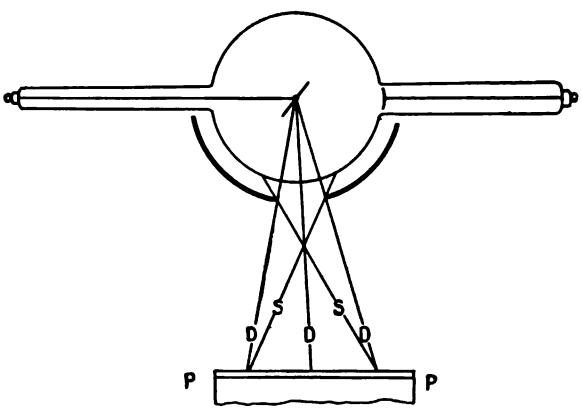

Fig. 66. D D D, direct rays. S S, secondary rays. P P, part.

might strike the part also. (Fig. 66.) The diaphragm is a piece of lead with a hole in it, situated, as a removable part of the tube stand, between the X-ray tube and the cone, cylinder, or square. (Fig. 328.)

CHAPTER IV.

Making Radiographs.

The X-ray picture is variously called radiograph, skiagraph, Roentgenograph, radiogram, skiagram and Roentgenogram. The word radiograph is a combination of a Latin and Greek word meaning *ray* and *write* or *record*. The word skiagraph (spelled also sciagraph) is a combination of two Greek words meaning *shade* or *shadow* and *write* or *record*. The word Roentgenograph is a combination of a proper name, Roentgen, and the Greek word meaning *write* or *record*. The terminal gram occurring in the words radiogram, skiagram and Roentgenogram —as well as the more common words such as telegram, program, epigram, and others—is of Greek origin and denotes that which is written or marked.

The use of the X-rays for radiographic work depends on two properties of the rays. First, they penetrate substances in direct proportion to the density of the substance, and second, they affect the photographic plate or film the same as white light does.

Photographic Plates.

A photographic plate is a piece of transparent plate glass about an eighth of an inch thick, one side of which is coated with an emulsion of a silver salt, usually silver bromide, and gelatine, albumen, or collodion. The use of the gelatine, albumen or collodion is simply to stick the salt to the glass. When a thin coating of this emulsion has dried on the glass we have what is called the photographic "dry plate." In appearance it is similar to translucent greenish-white glass, but on close inspection one is able to detect that one side is a little less glossy than the other. The less glossy is the coated side, also called the sensitive, the film, or the emulsion side of the plate. The term "dry plate" is to-day an almost superfluous one, practically all the plates used being dry plates. There is, however, a photographic plate known as the "wet plate," but, since it is never used in radiography, I shall not describe it.

The dry plate is made in the absence of white light, put up in light-proof packages, and so supplied to consumers. These packages must not be opened except in a dark room, for the slightest exposure to a white light will spoil them.

The difference between the photographic dry plate and the photographic film is only that the plate is a piece of glass coated with a silver salt, while the film is a thin sheet of transparent celluloid coated with a silver salt. As with the plate, the sensitive side of the film is a little less glossy than the uncoated side. The film curls slightly toward the coated side, unless it is of the "non-curling" variety, when it is straight, or may even curl slightly away from the coated side. One method of making non-curling films is to coat the non-sensitive side with gelatin without any silver incorporated in it.

Special X-ray Plates and Films

X-ray pictures may be made on ordinary plates and films made to be used in cameras. While this may be done, the results obtained are usually not nearly so good as when special X-ray plates and films are used. Special X-ray plates and films are extremely sensitive—that is, easily acted upon by light—for, though the X-rays have a wonderful power of penetration, their action on the silver emulsion of the photographic plate is feeble compared to the white light of day. To make them especially susceptible to the action of the X-rays some X-ray plates contain some fluorescent substance in the silver emulsion. Multi-coated plates are plates which have been coated with more than one coating of emulsion, one coat on another.

Special X-ray plates and films can be obtained from many photographic supply houses and from any X-ray equipment company. The following is a list of the manufacturers who make special X-ray plates: George W. Brady & Co., Chicago, Ill.; the Eastman Kodak Co. and the Forbes Dry Plate Co., Rochester, N. Y.; Cramer Dry Plate Co., St. Louis, Mo.; the Hammer Dry Plate Co., St. Louis, Mo.; the Lumiere N. A. Co., New York City, and the Ilford Mfg. Co., London, England. So far as I am able to learn only two manufacturers make X-ray films: The Eastman Kodak Co. and the Ilford Mfg. Co. Since the war it has been difficult to obtain the Ilford film. A German film, the Schleussner film, can no longer be obtained at all on account of the war.

I wish here to advise against buying large quantities of either plates or films at a time. They deteriorate in a few months.

Technic of Making Radiographs

The making of a radiograph of the hand is one of the simplest operations in radiography, and for that reason it will be described to teach elementary principles. The following technic of making a radiograph will, of necessity, be much broken into by descriptions of materials and appliances used.

A 5 x 7-inch plate is about the right size to make a radiograph of

the hand. Plates are supplied by the manufacturer packed in light-proof boxes, holding usually one dozen plates, with the warning on the box. "Open only in a dark room." The "dark room" is simply what the name states—a room from which light is excluded. A closet without a window makes a good dark room, except that there is seldom running water in it. It is not absolutely necessary to have running water in the dark room, but it is very convenient. If a closet cannot be utilized a room, light-

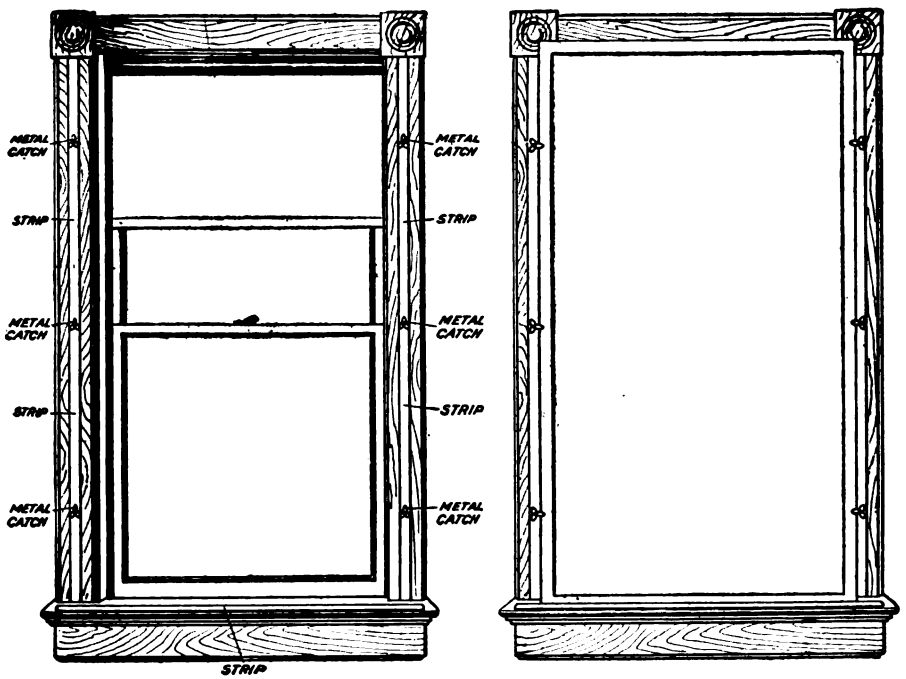

Fig. 67. To left, window ready for frame. When frame is in position the metal catches are turned to hold it. The frame fits inside of the strip on the sill. Figure to right shows frame in position.

proof except for one window, may be made dark by covering the window with a frame on which is tacked some material such as the leather or rubber used for side and storm curtains in buggies. If this material does not completely turn the light, it should be painted with thick black paint. The frame should be made to fit over, not into, the window casing. (Fig. 67.) With the frame so placed, if a little light comes in around it, it does not come directly into the room, but is reflected to the side. The more perfect the darkness of the room the better, but the *very little* light

which can enter through a window with the blind drawn down, and with a well-made frame over it will not cause any trouble. If the door to the room permits light to leak in around it, such light should also be shut out.

It would be impossible, of course, to work to any advantage in a perfectly dark room, for we could not see what we were doing. Hence the necessity of having a dark room lantern (Fig. 68), which will give sufficient light to guide us in our work, without being of such nature as to have any action on plates or films. The term "developing light"—the



Fig. 68. Dark room lantern.

light given by the dark room lantern—may mislead one to believe that the light in some way aids in developing a plate by its action on it. But such is not the case. The light is of value only because it enables the worker to see. The light may be a candle, a coal oil lamp, or an incandescent electric light shining through red glass. While such a lantern can easily be made, the writer warns against it, for, though the light of a home-made lantern may appear the same to the eye as the light of the lanterns manufactured by photographic supply manufacturers, its action on a plate or film may be disastrously different. The lantern shown in Fig. 68 consists of a 16-candle power incandescent light with a frosted glass bulb, in a light-proof tin box, the front of which is of removable glass. The light shines first through the frosted glass of the bulb, then an orange-colored glass, then a ruby glass.

In the dark room, with only the light of the dark room lantern we

open our box of plates,* take out one, carefully close the box, and place the plate in an envelope of black, light-proof paper just large enough to receive it. Now place plate, black envelope, *et al.*, in another envelope of black or orange-colored paper, putting the open end of the first envelope in first. We may now expose this package to ordinary daylight and artificial light with impunity, and the plate is ready for use in the making of a radiograph. These envelopes are obtained from the plate manufacturers.

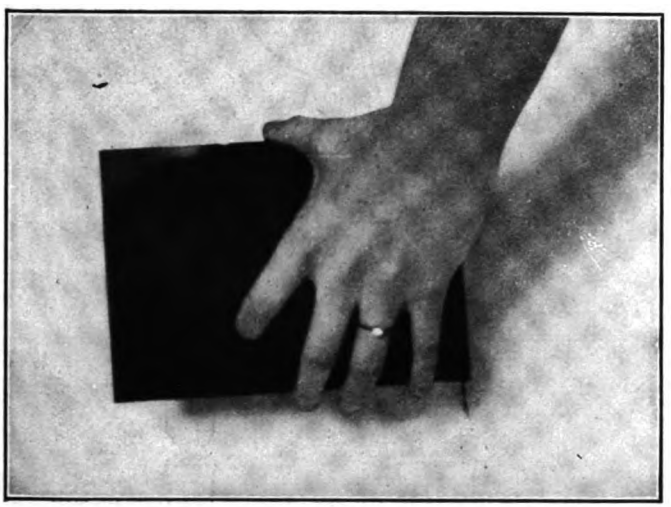

Fig. 69. Showing how to handle a plate by its edges.

While in the dark room, before putting the plate in the envelope, we must note which is the sensitive side, and bear this in mind until the outside envelope is marked properly to designate it. As formerly stated, the sensitive side is a little less glossy. Another way to determine which is the coated side is to look through the plate just *at the edge.* When the glass side is up, one is able to look through the glass and see the film beneath. The sensitive side of the plate should present toward the smooth side of the envelope—away from the seam side.

The plate should be handled by the edges. (Fig. 69.) This applies to the handling of the plate at all times, and to the handling of the film as well. Unless the fingers are wet or greasy, touching the sensitive side

*Experienced photographers prefer to handle sensitive plates in absolute darkness, and soon learn to detect the film side of the plate by feeling lightly with the fingers, thus obviating the need of the dark room light when "loading" plates.—Ed.

of the plate is not likely to result in spotting the picture, but it is always well to eliminate as many chances of failure as possible.

We are now ready to arrange tube, hand, and plate in their proper relative positions to take the picture. In all radiographic work it must

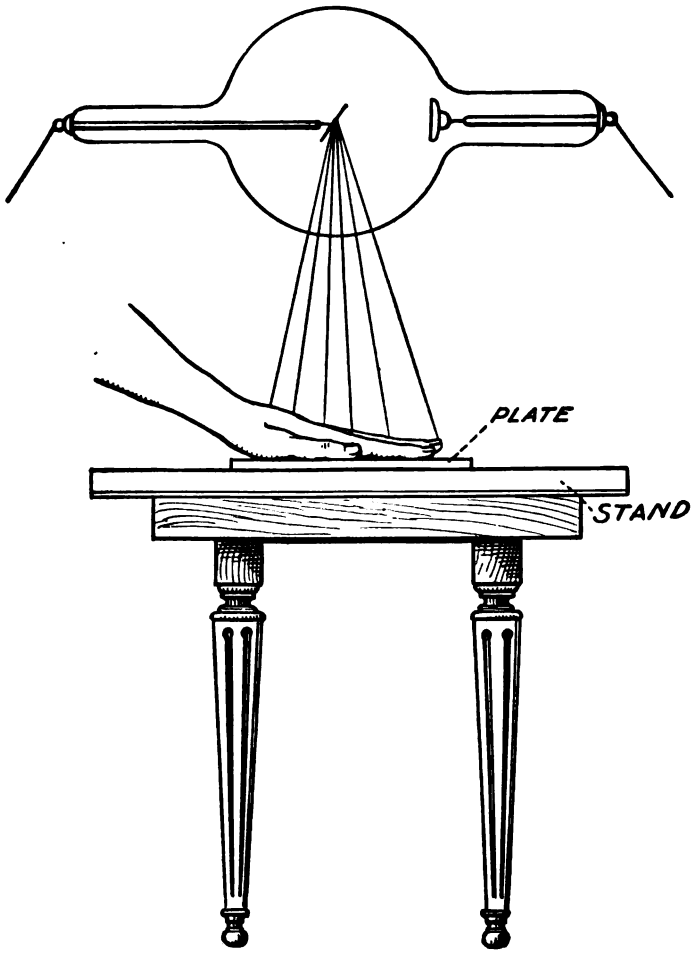

Fig. 70. Showing relative positions of tube, hand, and plate for making a radiograph of the hand.

constantly be borne in mind that we are making a shadow picture; that we are simply throwing a shadow on the plate, using X-rays as the source of light.

Lay the plate on a stand, sensitive side up. Place the hand on the plate. Adjust the tube at a variable distance directly above the hand. (Fig. 70.)

The distance from the tube to the plate may vary from about 10 to 30 inches, measurements being taken from the target, not from the glass of the tube. It is not necessary to have the target and the plate parallel to one another (in the same plane) as some writers direct. On the contrary, the position as in Fig. 70 is a better arrangement.

Assuming now that the tube is properly hitched to the coil and working properly, we are ready to make the exposure—to take the picture.

In giving demonstrations, I find that at this point someone invariably volunteers to "turn out the light." This is not necessary. The only reason for having the rooms even slightly darkened is to enable the operator to observe how his tube is working. The picture could be taken in bright daylight; the envelopes will protect the plate against all light except the X-rays. (See Chapter V for technic of lighting X-ray tube.)

When the switch is turned on and the X-rays produced, they, the rays, shine down on the plate penetrating the paper of the envelopes as though the plate were not covered at all. The rays penetrate the hand also and act upon the plate beneath. They penetrate the bones of the hand less readily than the flesh, and hence there is less action on the plate directly beneath the bones. In other words, there is a shadow of the hand thrown on the plate, the shadow of the bones being denser than the shadow of the flesh. The shadow of the flesh, in fact, may be so light that it is scarcely discernible, or even entirely blotted out. This is the case when a very high tube is used and a long exposure made.

Duration of Exposure.

The length of time of the exposure of the plate to the action of the X-rays when making a radiograph depends on several things. (1) The milliamperage sent through the tube. Other factors remaining the same, the more milliamperage sent through the tube the shorter the exposure necessary, because the higher the milliamperage sent through the tube the greater the number of X-rays produced. A coil equipped with a milliamperemeter enables the operator to observe the exact number of milliamperes passing through the tube. (2) The nature of the X-rays. Other factors remaining the same, the more penetrating the X-rays the shorter the exposure necessary. The higher the vacuum of the tube up to a given point, the more penetrating the rays from it. A low tube is useless for radiographic work. (3) The distance of the plate from the tube. Other factors remaining the same, the shorter the distance between the plate and the tube the shorter the exposure necessary. (4) The thickness of the part to be radiographed. Other factors remaining the same, the thicker the part the longer the exposure necessary. (5) The density of the part

to be radiographed. Other factors remaining the same, the denser the part the longer the exposure necessary. (6) The sensitiveness of the plate. Other factors remaining the same, the more sensitive the plate the shorter the exposure necessary. The product of some manufacturers is more sensitive than others. As a plate or film grows old it becomes less sensitive, finally becoming entirely useless.

Fig. 71. Radiograph of the hand, made from a pose similar to Fig. 70. (Reduced one-half.)

It will be seen from the foregoing that so many things enter in for consideration that the exact time of exposure cannot be stated with any degree of clearness. Elaborate systems of calculation have been worked out so that if the distance of the tube from the plate, the penetration of the X-rays measured with a penetrometer, the milliamperage sent through the tube, and the thickness of the part be known, reference can be made to a printed table and the exact time of exposure necessary learned. While commending such work as efforts along the right line, I consider them failures so far as practical application in dental work is concerned. Notice that in the calculation the density of the part and sensitiveness of the plate are not taken into account at all.

Each man must learn to properly time his exposure by personal experimentation. This statement is likely to be contradicted by those who construe it to mean that no idea at all of the time of the exposure can be learned except by experiment. That is not what I am saying, however. The idea I wish to convey is that these tables of calculation, on the time of exposure, give only the approximate length of time necessary, and that a very little experience and the use of judgment render them useless. They are always useless except when a penetrometer is used and the coil is equipped with a milliammeter.

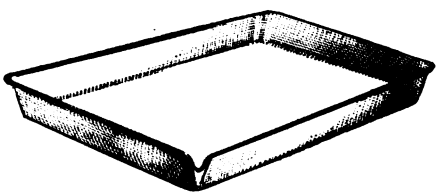

Fig. 72. Trays for developing and fixing solution

To make a negative (the picture on the glass of the plate) like the radiograph shown in Fig. 71, the factors may be as follows:

1. Machine used: A large induction coil, with a two-point electrolytic interrupter, operating on 110-volt, D.C. circuit. Three-fourths of the resistance of rheostat cut out.

2. Strength of current: Machine not equipped with ammeter or milliammeter. Approximate amperage of the primary current, 20. Secondary current sufficiently powerful to obtain a fat, fuzzy spark 10 inches long—an estimate, about 10 milliamperes.

3. Penetration of X-rays: Tube backs up 5 inches of parallel spark. Distance of tube regulating spark gap 5 inches. Therefore, the tube is medium high and the rays from it rather penetrating when it is properly lighted. Benoist penetrometer 5.

4. Distance of target from plate: Twenty (20) inches.

5. Thickness of part: That of hand, about 1½ inches at thickest part.

6. Density of part: That of hand.

7. Plate used: Paragon special X-ray plate. (An ordinary camera photographic plate might have been used to take such a picture. Had this been done, however, the time of exposure necessary would have been about twice as long.)

8. Time of exposure of plate to action of rays: Two (2) seconds.

9. Time plate remained in developer: Five minutes.

During exposure, the patient, tube and plate must be perfectly immobile. After the exposure we are ready to "develop the negative."

Method of Development.

Remove the plate from the envelope in the dark room, exposing it only to the ruby light. It has not changed in appearance at all. It still looks like a piece of translucent, white glass. But the picture is there. It needs only to be developed.

This is done by immersing the plate, sensitive side up, in an aqueous solution of chemicals, the developer. This developer causes that part of the plate which has been acted upon by the X-rays to turn dark, but does not cause that part of the plate which has not been acted upon by the X-rays to turn dark. The degree of darkness produced by the developer in the plate varies directly according to the extent of the action of the X-rays on the plate.

Place the plate in the tray (Fig. 72) containing the developer with the coated side up, quickly covering the plate with the solution. A convenient way to make certain that the developing solution covers all of the surface of the plate immediately is to place the plate in the empty tray (sensitive side up of course) and pour the developer, out of a tumbler, over it. Expose the plate to even the light of the dark room lantern as little as possible until development is well under way. Trays can be purchased from any photographic supply house. Always use a tray sufficiently large to easily receive the plate. The action of the developer will be hastened and made more uniformly perfect by slightly raising, then lowering, one end of the tray, and so moving the developer over the surface of the plate.

The length of time it takes the image or "picture" to "come up" or show varies according to the length of exposure. If the exposure has been well timed and the developer used acts as the average developer acts, neither very rapidly or very slowly, the image will appear in about 30 seconds; if the exposure has been a little overtimed, the image may appear in about 10 or 15 seconds; if it has been a little undertimed, it may take 1 or 2 minutes for the image to appear.

Developing is not completed as soon as the image shows. Sometimes the image can be seen better by removing the plate from the developer and holding it up to the ruby light. If the exposure has been well timed the "high lights" will commence to appear (i. e., the plate will begin to turn dark in places) in about 15 seconds, and, as just stated, the image can be seen tolerably well in 30 seconds. If this is the case the plate should be left in the developer about 5 minutes. From the foregoing we

may make the following rule: Leave the plate in the developer about 20 times as long as it takes for the high lights to appear, or 10 times as long as it takes for the image to appear. This is not an inflexible rule. Indeed, no inflexible general rule can be made, because of the difference in the action of different developers. Another rule is to leave the plate in the developer until the image can be seen on the glass side of the plate.

The actual time of developing will vary: 2 or 3 minutes for over-timed exposures; about 5 minutes for plates which have been well exposed; 10 to 15 minutes for undertimed exposures. This applies to most developing solutions. However, developers known as "slow" developers require about 20 minutes for well-exposed plates, and the Brady, Paragon developer, known as the "four-minute developer," requires only 4 minutes.

There are a very great many different developing formulas, any of which may be used. In making up developers, chemicals should invariably be dissolved in the order as named. The following are some of the most popular developer formulas:

M—Q DEVELOPER *

	Avoirdupois	Metric System
Water	10 ounces =	300 c.c.
Metol	7 grains =	1½ grammes
Hydrochinon	30 grains =	2 grammes
Sulphite of Soda (desiccated)	110 grains =	7 grammes
Carbonate of Soda (desiccated)	200 grains =	13 grammes
10 per cent. solution Bromide Potassium	40 drops =	40 drops

HYDROCHINON DEVELOPER

No. 1

	Avoirdupois	Metric System
Hydrochinon	300 grains	20 grammes
Sulphite of Soda	6 ounces	180 grammes
Water	48 ounces	1,440 c.c.

No. 2

Carbonate of Potassium	4 ounces	120 grammes
Water	32 ounces	960 c.c.

TO DEVELOP, take

No. 1, 6 ounces (180 c.c.); No. 2, 4 ounces (120 c.c.); 10 per cent. solution Bromide of Potassium, 3 to 10 drops. Mix.

---

*M—Q stands for "metal—quinol." In photography the word "quinol" is used as an abbreviation for "hydroquinol." This is unfortunate, because quinol and hydroquinol are different substances. There are several words and different spellings of the same word used to designate the substance—hydroquinol. They are: hydroquinon (spelled also hydroquinone); hydrochinol (spelled also hydrokinol); hydrochinon (spelled also hydrochinone, hydrokinon, and hydrokinone).

PYRO DEVELOPING FORMULA

Pyrogallic Acid Solution

"A"

	Avoirdupois	Metric System
Pyrogallic Acid	1 ounce	30 grammes
Sulphuric Acid	20 minims	1 c.c.
Water	28 ounces	840 c.c.

SODA SOLUTION

"B"

	Avoirdupois	Metric System
*Carbonate of Soda (Anhydrous)	2 ounces	60 grammes
*Sulphite of Soda (Anhydrous)	3 ounces	90 grammes
Water	28 ounces	840 c.c.

TO DEVELOP, take

"A," 1 ounce (30 c.c.); "B," 1 ounce (30 c.c.); Water, 8 ounces (240 c.c.). This developer will then contain 1.56 grains Pyro per ounce.

The developer may be made and kept in stock solutions as above, if desired. A better plan is to buy the prepared developing powders. They may be purchased at any photographic supply store. The chemicals come in glass tubes or packages mixed in the proper proportions, and all that is necessary to make the solution is to dissolve them in the quantity of water (distilled or tap water either) suggested on the package. The package or tube usually contains a sufficient quantity to make 4 to 8 ounces of developing solution. The advantages of this over mixing the chemicals yourself are: First, the convenience and saving of time, and second, only small quantities being made at one time, the developer is used immediately, and is therefore always fresh when used.

A developing bath does not keep well in stock solution unless the bottles are full and well corked. Even then discoloration and disintegration occur in the course of a month or so. It is always advisable to use as fresh a solution as possible. Packed in the box with the plates will always be found a formula for a developer recommended by the manufacturer of the plates. It is not at all necessary to use the particular developer recommended.

Temperature. During the hot summer months it is necessary to use ice in the developer, ice water to make the solution, or place the tray containing the developer in another larger tray with ice water in it. If the developer is too warm it will soften the emulsion, cause frilling at the edges, blistering and fogging of the negative. The developer should be between 65 and 70 degrees F. If too cold, development takes place slowly, and the negative, when finished, is pale and thin. I use tap water in the winter and have no trouble due to improper temperature. In the summer, though, even using ice water and ice, the work is often discouraging. If possible during the hottest weather defer development until the cool of the evening.

*If crystals are used, double the quantity.

Fixing. When development is complete, remove the plate, dip it in clear water, then immerse it in the fixing bath. The fixing bath is a solution of chemicals which dissolves out the unaffected silver. Leave the plate in the fixer for two or three minutes after the milky appearance of the glass side of the plate has disappeared. A plate must be removed promptly from the developer as soon as development is complete, or the negative will be overdeveloped, spoiled, but it may be left in the fixing bath for hours longer than necessary without danger of spoiling the negative.

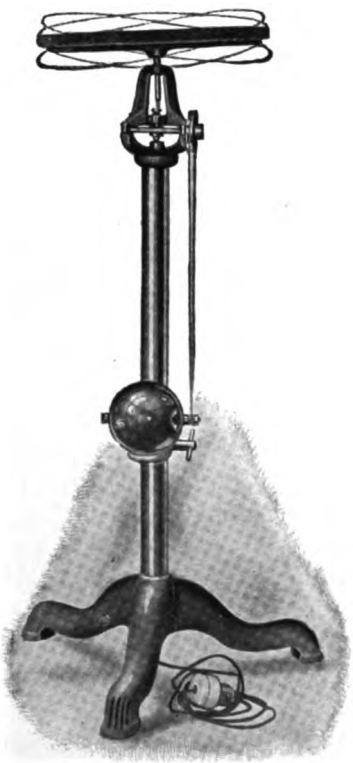

Fig. 73. Titubator.

It will not injure the plate to remove and replace it in the baths at any time during developing or fixing.

The actual time required for fixing varies from 5 to 20 or 30 minutes. The thicker the emulsion the longer time it requires for fixing. Movement of the fixing solution over the surface of the plate will hasten

fixing. A titubator (Fig. 73) is a machine on which the fixing bath tray may be set, and the bath kept in constant movement over the plate.

When several negatives are being made at the same time, it is well to use a fixing box (Fig. 74) instead of a tray. If the plates were piled one on another in the tray, they would probably stick to one another and, when pulled apart, the emulsion would be scarred. The plates stand on end in the fixing box, fitting into grooves.

Hyposulphite of soda is the standard fixer. There are not a great number of fixers, as there are of developers, to choose from. Hyposulphite of soda and water alone will fix plates, but is not so efficacious as when other chemicals are added to harden the emulsion.

ACID-FIXING BATH

	Avoirdupois	Metric System
Water	64 ounces	2 liters
Hyposulphite of Soda	16 ounces	450 grammes
Sulphite of Soda (Anhydrous)	¾ ounce	20 grammes
When fully dissolved, add the following hardener:		
Powdered Alum	½ ounce	15 grammes
Citric Acid	½ ounce	15 grammes

A stock solution may be made as given in the foregoing formula, or the prepared fixing powder purchased, and the fixing bath made by simply dissolving the powder in a stated quantity of water. There is nothing secret about the formulas of the prepared fixing powders. They are all practically the same as the formula given. The advantage in using them lies in the saving of time and energy that would otherwise be spent weighing chemicals. If prepared developing and fixing powders are used, it will not be necessary to have a pair of scales for this work. A graduated glass for measuring liquids will be all that is needed. During the hot months, it is expedient—not necessary—to use a freshly mixed fixer. If this is done the negative is less likely to frill or blister. Unlike the developing bath, however, the fixing bath will keep without disintegration for months. If scum or sediment appears after standing for some time, this may be removed by filtering the solution through filter paper or cotton.

The temperature of the fixer should be at least as low as that of the developer, and better lower, say about 50 degrees F.

When fixed, if the plate is held up to the light (any light, for the plate is no longer sensitive to light), the shadow of the bones of the hand will appear as transparencies; the flesh shows a little less transparent than the bone, and the balance of the plate will be opaque and black. Thus the shadows show light, and where no shadow was thrown the plate is dark. Hence the name negative which is applied to this picture on the plate. The making of the positive picture on paper, the print, as it

is usually called, from the negative will be described presently. The plate is no longer sensitive to white light, and may therefore be exposed to it any time after having been in the fixer a minute or so.

Great care must be exercised not to get any of the fixing bath into the developer. A very little "hypo" will spoil the developer. It is well to label the trays so that the tray used to hold the fixer one time will not be used for the developer another. Or, instead of labeling the trays, a black one may be used for the developer and a white tray for the fixer.



Fig. 74. Fixing box.

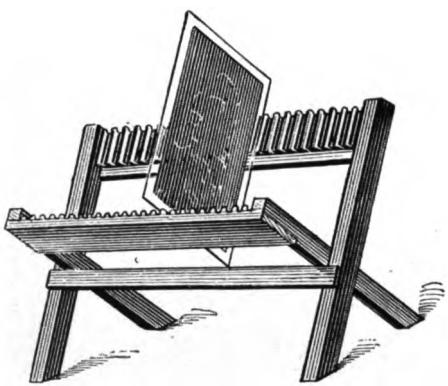

Fig. 75. Plate, or negative, rack.

Washing. When fixing is completed the negative must be washed in clear water to remove all "hypo" from it. If the negative be placed in a tray, the tray in a basin or sink and the tap turned on, or, in other words, if the negative be washed in running water it requires 15 to 30 minutes to thoroughly wash it. Where running water cannot be had,* and sometimes during hot weather when tap water is too warm, the negative may be placed in a larger vessel of water and left for about an hour, changing water several times. A tray of water used on a titubator is efficient. The water must be changed often, and the time required is about three-quarters of an hour or longer. When several negatives are being made, it is advisable to use a washing box similar to the fixing box. (Fig. 74.)

---

*"Running water" is much to be preferred, as the friction or movement of the water is a great factor in cleansing the plate. After a few months, if plates show cloudiness, or a metallic luster is observed, this means that the plates were not thoroughly washed. It is even advisable, after washing, to rub the surface of the film side with clean, wet cotton, holding the plate under a faucet during the act.

Drying. The next, and the last step in the making of the negative, is to dry it. The plate should be set on edge. Drying should take place in a clean atmosphere, so that no dust or soot will fall on and stick to the coated surface of the negative. Plate racks (Fig. 75) may be used, but are not a necessity. The plate may be set on edge at an angle of about 95 degrees by simply leaning it up against some perpendicular wall. (Fig. 76.) Drying requires several hours. It may be hastened by placing the negative in a breeze. By immersing the negative in a mixture of formalin and alcohol, then placing it in the breeze of an electric fan, drying will be very materially hastened. The use of the formalin and alcohol sometimes causes spotting and blurring of the negative. If all the salts of the fixer are not well washed out of the emulsion, it will not dry promptly, but will become rough and sticky, and, when finally dry, it will be full of little holes.



Fig. 76. Negatives leaning against perpendicular wall, drying.

Summarizing the making of the negative, it consists of exposing, developing (washing—mere dipping in water), fixing, washing, and drying.

If the negative when finished is very dark, so dark that parts of the image are lost, the plate was either overexposed, or overdeveloped, or

both. I prefer usually to say that it was overdeveloped, for even if it had been exposed unnecessarily long, this mistake might have been corrected by leaving it in the developer a shorter length of time. If the negative is almost entirely transparent and the image can hardly be seen, it is due to underexposure, or underdevelopment, or both.

Reducers.

The mistake of overexposure or overdevelopment can be corrected to an extent by the use of a "reducer."

The following solution is a reducer:

*A. Water	16 ounces	(480 c.c.)
Hyposulphite of Soda	1 ounce	(30 grammes)
B. Water	16 ounces	(480 c.c.)
Potassium Ferricyanide	1 ounce	(30 grammes)

Mix 8 parts of solution "A" and one part of solution "B," and use in subdued light.

The negative can be placed in this solution directly after fixing, without washing. Or it may be washed—it makes little or no difference. If a dry negative is to be reduced, it must be soaked in water for at least half an hour before placing it in the reducer. When sufficiently reduced, wash thoroughly for about three-quarters of an hour, then dry. The work of reducing may be done in any light.

When not in use keep solution "B" protected from the action of light. Remember that this solution is one of the most powerful poisons known. Handle it with extreme caution.

Intensifier.

The mistake of underexposure cannot be corrected to an appreciable extent by any means.

The mistake of an underdevelopment can be corrected to an extent by the use of an "intensifier."

After having fixed the negative, wash it well in running water for about thirty minutes or longer, then place in the following solution:

Mercuric Bichloride	200	grains	(13.3 grammes)
Potassium Bromide	120	grains	(8.0 grammes)
Water	6½	ounces	(195 c.c.)

Keep the plate in this solution a short time, when it will be observed to be bleached uniformly white (the longer the negative is bleached the denser it will ultimately become). Remove from the bleaching solution, wash in running water for a few minutes, then blacken in the following solution:

Sodium Sulphite	1 ounce	(30 grammes)
Water	4 ounces	(120 grammes)

Or

Ammonia	20 minims	(1 c.c.)
Water	1 ounce	

---

*"Electro-Therapeutics and Roentgen Rays," Kassaban.

When sufficiently blackened, the negative is again washed, then dried. Intensifying should be done in a subdued light—not in bright daylight.

An old negative, one which has been made for some time, may be intensified by first soaking in water, then following the technic given.

Prepared reducers and intensifiers, with directions for their use, may be purchased at any photographic supply house.

Fig. 77. Showing how the printing frame is held up to the light to expose the photographic paper. Also showing the back of the printing frame, the frame half open, and the photographic paper in position.

While reducers and intensifiers have their place in dental radiography, they are used only to correct mistakes, and they do not entirely correct the mistakes. It is usually expedient to make a new negative rather than to attempt to reduce or intensify a faulty one.

Round transparent spots on the negative are caused by air bubbles, or air "bells," as they are called, attaching themselves to the emulsion side of the plate while in the developer.

Spots of irregular size and character appearing on a negative are due often to the use of an old developer. In radiographic work, where the appearance of a spot may determine a diagnosis, it is to be hoped that fresh developer will always be used. By fresh developer I mean developer not, at most, over a month or so old, having been kept while in stock in a filled, tightly stoppered bottle, and free from all scum and sediment. A developer containing pyrogallic acid disintegrates so rapidly that it must be used immediately after mixing—it will not keep at all. "Pyro" developers stain the hands badly.

Positive Prints.

When the negative is dry we are ready to make the positive pictures. The pictures are made on sensitized paper, a very fine grade of white paper, one side of which is coated with a silver salt somewhat as plates and films are coated. These papers sell under such various names as Velox, Cyko, Artura, and Azo, and may be purchased in any size, put up in light-proof packages. Papers are not as sensitive as plates and films, and an orange instead of a ruby light may be used in the dark room.

Place the negative, emulsion side up, in the printing frame (Fig. 77). Place a sheet of paper, sensitive side down, over the negative, and close printing frame. The sensitive side of the paper may be determined by observing that the paper curls slightly toward it; or by biting a corner of the paper, when the sensitive side will stick slightly to the teeth.

To make the exposure now, either artificial or daylight may be utilized. Before making the exposure be sure that the balance of the paper in the package is well protected against the light. Hold the printing frame so the light will shine through the negative and strike the paper. (Fig. 77.) It is not necessary to hold the printing frame immovable during exposure. The time of exposure varies greatly according to the density of the negative; the denser the negative the longer the exposure must be. Some idea of the time of exposure necessary may be learned from the directions enclosed with the paper. To make the print for Fig. 71, a 16 c.p. electric light was used, holding the printing frame about 8 inches from the light and exposing the paper—Azo—3 minutes.

Development of Prints.

With the 16 c.p. light turned off, in the orange light, the paper is now removed from the frame. As with the plate there is not the slightest change in the appearance of the paper after exposure, but the image is there, it is latent, it needs only to be developed.

The developing formulæ for papers are, broadly speaking, the same as for plates. It is very important that the developer for paper be freshly mixed, for the slightest discoloration of the bath will soil the paper. It is not desirable to save the developer used to make the negative and use it again for the paper. It is too liable to cause discoloration of the print. "Pyro" is a very poor developer for paper.

Immerse the paper quickly, sensitive side up, gently passing the tips of the fingers over the surface, to hasten development by agitating the developer, and to keep the paper submerged. As soon as the image appears as desired, transfer it to clean water, then quickly into the fixer. (It is kept in the water but a moment or so.) If, when placed in the developer, the image comes up so quickly that it gets too dark before it

can be transferred to water and fixer, it has probably been overexposed. Shorten the time of exposure, and if the image still comes up too quickly, dilute the developer. If the image appears very slowly and the whites of the print are gray, increase the time of exposure; if the whites still come gray, add a few drops of a 10 per cent. solution of bromide of potassium to the developer.

The fixing bath for prints is the same as for plates, but the bath used to make the negative should not be saved and used again for prints. It might discolor them.

Allow prints to remain in the fixer 15 to 20 minutes. This dissolves out the unaffected silver.

Next wash print in running water for about thirty minutes. No visible change occurs in the print from the time it leaves the developer. Fixing and washing are done to make it permanent. The temperature of the developer, fixer, and water should be the same as for plates, to obtain the best results.

When thoroughly washed remove the prints from the wash water and place on a piece of clean glass face down one on the other, and press out the water. Then lay them out separately on a frame, covered with cheese cloth. The cheese cloth being very thin, allows the prints to dry on the side next the cloth as well as the upper side.

When dry the prints may be mounted on cardboard.

Dental Radiography or Radiodontia.*

CHAPTER V.

Making Dental Radiographs.

In the foregoing chapter we dealt with the general elementary principles of radiography. We shall now take up a more concrete consideration of dental radiography.

The first radiograph of the teeth was exhibited by Prof. Koenig to the Society of Physics at Frankfort-on-Main, Germany, in February, 1896—only a few months after the discovery of the X-ray. Five months later an article appeared in Dental Cosmos by Morton, entitled "X-rays in Dentistry." Since then there have been many articles written on the subject and published in various dental, medical, and Roentgenographic journals.

For convenience in describing the technic involved in the practice of dental radiography the subject will be considered under the following heads: (1) Manipulation of the X-ray machine and lighting of the X-ray tube. (2) Posing the patient and adjusting the X-ray tube and film or plate. (3) Exposure. (4) Making the negative.

The Manipulation of the X-Ray Machine and Lighting of the X-Ray Tube.

Since the X-ray machine of each manufacturer has characteristics of control peculiar to itself I can give here only the general principle of manipulation.

As the reader already knows, there are three types of X-ray machines in general use: (1) The induction coil. (2) The high-frequency coil.

---

* Radiodontia is a new word coined by the writer. Radiodontia is the science and art of making and interpreting radiographs of the teeth and contiguous parts.

A radiodontist is one engaged in the practice of radiodontia.

These words will be found quite useful and have been promptly adopted by all interested in the subject except advocates of Roentgen words, who believe all X-ray words should contain the proper name Roentgen, no difference how unwieldy or senseless they may be.

(3) The transformer. We shall consider the manipulation of the induction coil first.

Manipulation of the Induction Coil.

Different induction coils have a different number of controls of various sorts. Selecting a coil with all the different controls I shall name them. (See

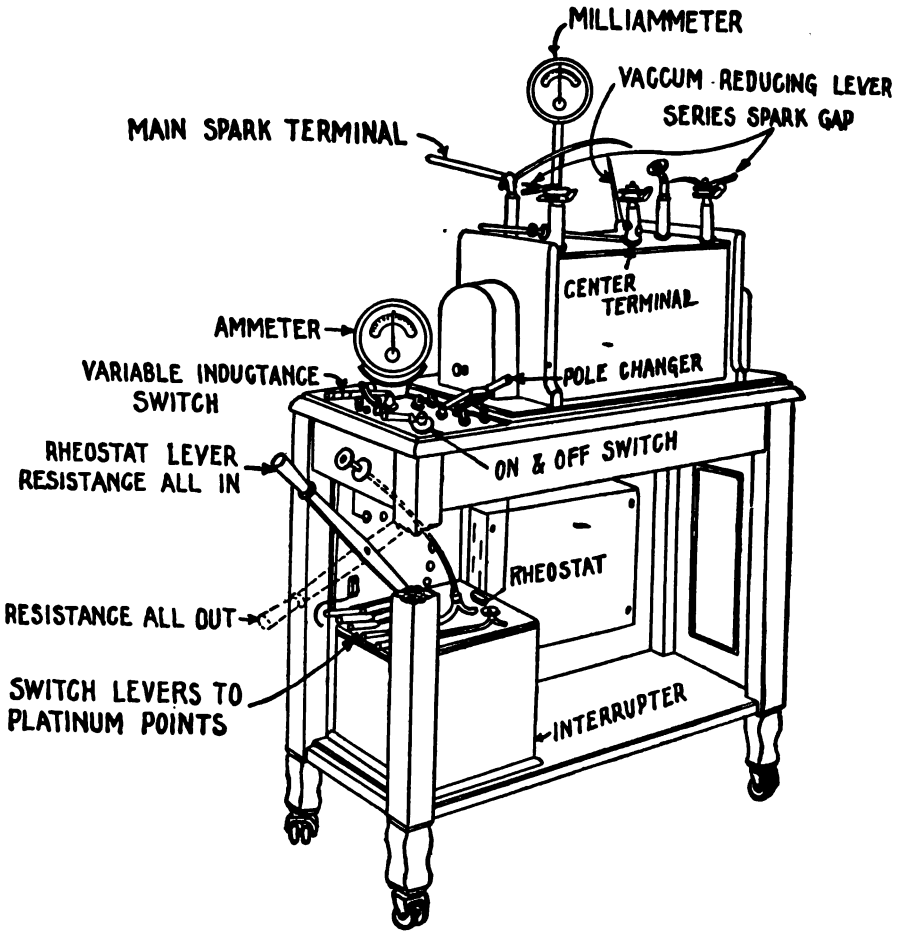

FIG. 78

Fig. 78. Induction coil, showing the various controls.

Fig. 78.) First, the "on and off switch"; second, the "pole changer"; third, "the rheostat lever"; fourth, interrupter switches, levers and screws "to platinum points"; fifth, the parallel or "main spark" gap;

sixth, the "vacuum reducing lever"; seventh, the "series spark gap" or inverse current spark gap; eighth, the "variable inductance switch."

The "on and off switch" is the one by means of which the current is turned into the machine. This control is on all coils.

The "pole changer" (Fig. 78) is a double-throw knife switch by means of which the secondary current, or output current produced by the coil, can be made to flow in either direction—when this switch is down on one side the current flows in one direction, when it is down, or closed, on the other side it flows in the opposite direction. If, after the tube is connected to the coil, it is found, by the manner in which the tube lights, that the current is traveling through it in the wrong direction (Fig. 48 and bottom of page 52) the tube need not be detached and re-attached to the coil; instead, change the pole changer switch. This pole changer control is found on comparatively few induction coils.

The rheostat controls the quantity of electricity entering the machine and so the quantity produced by the machine to be sent through the tube. (Fig. 30.) On very large induction coils it is often inexpedient to cut out all of the resistance of the rheostat, while on the smaller ones, and the special dental X-ray coils of the induction coil type, it is usually necessary. Always, when the current is turned into the tube for the first time, the rheostat lever should be on a low button. The rheostat control is found on all induction coils.

Multiple point electrolytic interrupters are equipped with switches by means of the manipulation of which only one, only a part, or all of the platinum points may be used. Screws or levers, or both, control the length of the platinum exposed in the electrolyte. For the beginner at least it is best that the interrupter adjustment be made or set and its further manipulation avoided as much as possible. If more than three points are used in the interrupter, set the platinum exposed to the electrolyte at from ⅛ to 2/8 inches. If one to three points only are used, set the exposure of the platinum to the electrolyte between 2/8 and ⅜ inches.

Interrupters are made which adjust themselves automatically. The end of the platinum rests against a piece of porcelain. It is weighted down to place, and thus the amount of platinum exposed remains the same always. In this style of interrupter base metal is sometimes used instead of platinum. The exposed metal disintegrates and wears away but the weight keeps the end of the point resting against the porcelain and so the amount of the point exposed remains the same. (Fig. 79.)

The parallel spark gap may be manipulated to determine the number of inches of spark the tube will back up and so determine the degree of vacuum. (Pages 42 and 43.) As the operator becomes familiar with his

tubes and machine he will manipulate this gap less. It is the practice of some men to set this gap at about 7 inches and leave it there, resorting to the regulation of the vacuum of the tube only when sparking occurs at the parallel spark gap. The parallel spark gap control is found on all induction coils.

The "vacuum reducing lever" is the lever by means of which the tube-regulating spark gap (Pages 46 and 47) is made wide or narrow. If the tube will light properly, and no sparking occurs at a 6 to 8-inch parallel spark gap, the tube requires no vacuum regulation. If sparking occurs across 6 to 8 inches of parallel spark, reduce the distance of the



Fig. 79. Self-adjusting electrolytic interrupter.

tube-regulating spark gap to an inch or two and, with the rheostat on a low button, turn on the current for 2 or 3 seconds. This may be repeated if necessary and will lower the vacuum of the tube. As tubes get old, the vacuum gets high, and they become "cranky." To handle an old tube it is often necessary to open the parallel spark gap as wide as possible, and set the tube-regulating spark—5 inches for a slightly "cranky" tube, as short as 2 inches for a very high "cranky" tube—allowing the

tube-regulating spark gap to remain set all the time the current is turned on. The object of the operator should be to avoid regulation of the vacuum of the tube as much as possible.

The "vacuum reducing lever" control is not found on all induction coils. When the machine does not afford this control, the width of the tube-regulating spark gap is controlled by means of a movable arm at the tube. (Fig. 44.)

The "series spark gap" or inverse spark gap, should be used only when necessary to cut inverse current out of the tube, otherwise the gap should be closed. If a valve tube (Figs. 51 and 52) is used it is seldom necessary to make a series spark gap.

By means of the "variable inductance switch" the output current of the induction coil can be raised or lowered in voltage. The voltage required for a new tube is not as great as the voltage required for an old tube with a higher vacuum. When a great deal of inverse current is seen in a tube it may mean that the induction coil is generating a current too high in voltage. When a new, unknown tube is used for the first time on an induction coil with an inductance switch, start with the lowest voltage, and the rheostat on a low button. Flash the current through the tube, advance the rheostat, flash again and so on until all of the resistance of the rheostat is cut out. If no inverse current has been observed in the tube, advance the inductance switch to a higher voltage, start with the rheostat on a low button again, flash the current as before and so on, advancing to a higher voltage in this way, until the tube shows inverse current passing through it. The tube should be operated just this side of the point where inverse current appeared in it—say for example on inductance button 3, rheostat button 15. If the tube is labelled, inductance 3, rheostat 15, it may be used with the machine set according to the label for some time. Comparatively few induction coils have the "variable inductance" control.

Summary of Technic for Lighting X-Ray Tube with Induction Coil.

The technic for lighting an X-ray tube with an induction coil (without a variable inductance control) may be summarized as follows: (1) Test the coil by means of the on and off switch, starting with the rheostat on a low button and advancing the rheostat between test flashes. You should be able to obtain *at least* 5 or 6 inches of fat, fuzzy, parallel spark. This step is unnecessary save for the beginner using a new coil for the first few times. It shows such a beginner how much of the resistance of the rheostat must be cut out to obtain a fat, fuzzy spark. It shows that the machine is operating properly, that the interrupter is properly set. On some machines with terminals of the right shape it enables the operator to determine the polarity of the parallel spark gap terminals. (Page 42,

Fig. 40.) (2) Connect the tube to the coil. (3) Set the parallel spark gap at about 6 or 8 inches.* (4) With the rheostat on a low button flash the current on. Advance the rheostat between flashes. If the current is passing through the tube in the wrong direction change the pole changer switch or reverse the attachment of the tube to the coil. Once the polarity of the terminals has been determined the operator may depend on this polarity remaining the same, unless the pole changer switch is changed, and he may always connect the tube to the coil accordingly. *If* sparking occurs at the parallel spark gap, lower the vacuum of the tube. *If* inverse current is seen in the tube, make a series spark gap or place the rheostat lever on a lower button. *A little* inverse current in a tube will not materially interfere with the making of a good radiograph, especially if a diaphragm and cone or cylinder are used. (Fig. 65.) The great dif-

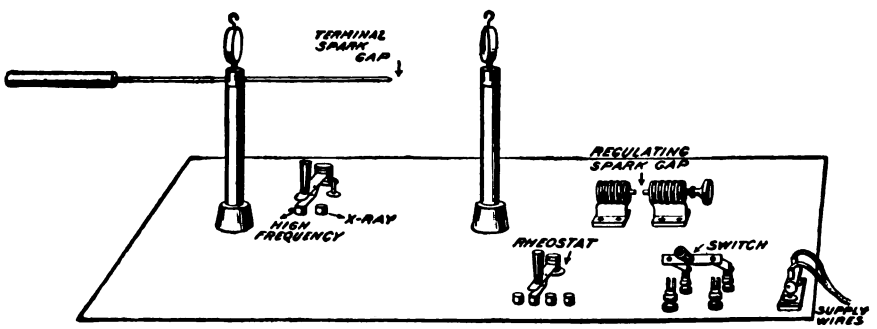

Fig. 80. Drawing of a high-frequency X-ray machine showing various controls.

ficulty in the technic of operating an induction coil is the problem of not allowing inverse current to pass through the tube.

Manipulation of the High-Frequency Coil. The controls shown in Fig. 80, for a high-frequency coil are: First, the frequency control, labelled "high-frequency" and "X-ray"; second, the on and off switch, labelled "switch"; third, the "rheostat"; fourth, the "regulating spark gap"; fifth, the "terminal spark gap" or parallel spark gap.

By means of the "high-frequency" and "X-ray" control switch either all or part of the condenser of the machine is used. When on the "X-ray" button all of the condenser is used and the frequency is lower. This button is sometimes labelled "low frequency" instead of "X-ray."

* See page 349 for Soft Tube Technic.

This control is found only on machines built for electro-therapeutic work as well as X-ray work.

The on and off "switch" turns the electricity into the machine.

The "rheostat" controls the quantity of electricity entering machine.

The "regulating spark gap" controls, within limits, the nature of the output current delivered by the machine. Widening the gap increases voltage at the expense of milliamperage, narrowing it increases milliamperage at the expense of the voltage. The gap should be as narrow as possible with the voltage high enough to jump the maximum parallel spark gap. (As the machines of this type are now built, the maximum spark gap is usually about 6 inches.) This gives the greatest milliamperage obtainable with sufficient voltage, or pressure, to force the current through a medium or medium-high vacuum, X-ray tube. The metal studs at the "regulating spark gap" should be cleaned occasionally: Place a piece of emery cloth or sandpaper between the studs, screw them together until they hold the cloth or paper loosely, and draw the cloth or paper back and forth over the surface of the stud.

On machines of this type, the parallel spark gap is practically always kept at its maximum width for X-ray work. If sparking occurs across it the vacuum of the tube must be lowered. When the tube is old and the vacuum of the tube cannot be lowered sufficiently to stop sparking between the terminals (remember the terminals are only about 6 inches apart on this type of machine) the writer has resorted to placing a piece of glass between them. This is a strain on the insulation of the coil.

Summary of Technic for Lighting X-Ray Tube with High-Frequency Coil. The technic for lighting an X-ray tube with a high-frequency coil may be summarized as follows: (1) Open the parallel spark gap to its maximum width, *i.e.* 6 or 7 inches. (2) Cut out all resistance of the rheostat. (3) Turn on the on and off switch and adjust regulating spark gap to get as fuzzy a spark as possible. (This should be done as quickly as possible so the current, with all of the resistance of the rheostat cut out, will not be turned into the coil needlessly long.) (4) Turn current off and connect tube to coil. (Since the current produced by this machine is alternating either terminal may be attached to the anode end of the tube.) (5) With the rheostat on a low button, flash the current through the tube. Advance rheostat, flash again, advance rheostat and so on until all the resistance of the rheostat is cut out. (6) If sparking occurs at the parallel spark gap, reduce the vacuum. The most convenient way to do this on a machine not equipped with a vacuum reducing lever, where the vacuum is controlled by a movable arm at the tube (Fig. 44), is to set the arm to give a certain width to tube-regulating spark gap and leave it there. For

new tubes the tube-regulating spark gap should be 5 or 6 inches, for old tubes 2 or 3 inches, this to be governed by sparking at the parallel spark gap. If sparking occurs at the parallel spark gap the width of the tube-regulating spark gap should be reduced until this ceases.

In case the high-frequency coil is operating on a direct current circuit

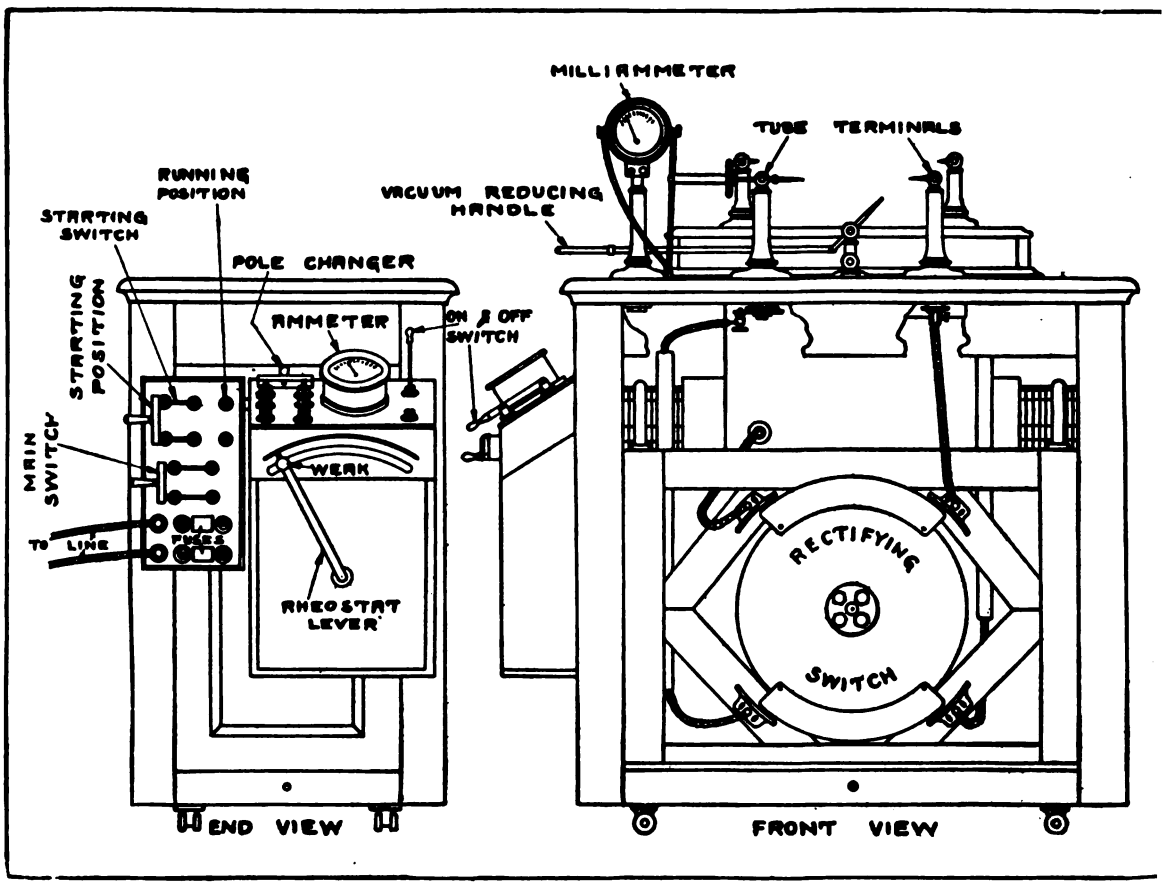

Fig. 81. Drawing of a transformer or interrupterless X-ray machine showing various controls.

the first step in the technic of manipulating the coil is to set the rotary converter in motion. This is accomplished by means of a switch and rheostat. (Fig. 37.)

Manipulation of A. C. Transformers.

The controls on a transformer built for an A.C. circuit are: First (Fig. 81), the "main switch"; second, the synchronous motor switch, a two-pole, double throw, knife switch labelled "starting switch" in Fig. 81; third,

the " on and off switch " which controls the output current of the machine; fourth, the " pole changer switch "; fifth, the " rheostat " which controls the quantity of output current; sixth, the " vacuum reducing " lever.

The " main switch " simply brings the current up to the machine.

By means of the " starting switch " the motor is set in motion. This revolves the " rectifier switch." The switch is thrown one way to start the motor, then, quickly while the motor is in motion, to the other side.

When the " on and off switch " is closed, the current is sent into the primary of the transformer and immediately the secondary current, or output current of the coil, jumps the parallel spark gap, or, if an X-ray tube is connected, passes through it, providing, of course, the vacuum of the tube is not too high.

The "pole changer" double throw switch, works on exactly the same principle as the pole changing switch on an induction coil. Unless the A.C. transformer is equipped with an indicator one never knows, before testing the current through the tube, which is the positive and which the negative terminal. Which way the current will flow depends on how the rectifying switch happens to pick it up. Some machines do not use the " on and off switch " shown in Fig. 81, but eliminate it entirely, and use the double-throw pole changer switch, trying it first on one side, then on the other, if necessary, to send the current through the tube in the right direction.

The " rheostat " controls the amount of current entering the primary winding of the transformer and so controls the strength of the output current.

The lever, or sliding rod, for reducing the vacuum on a transformer is practically the same as the lever, or sliding rod, for the same purpose on an induction coil. (Figs. 78 and 45.)

Summary of Technic for Lighting X-Ray Tube with A.C. Transformer.

The technic for lighting an X-ray tube with an A.C. transformer may be summarized as follows: (1) Connect the X-ray tube to the coil. Either terminal may be attached to the anode. (2) Have the parallel spark gap about 6 or 7 inches wide.* (3) With the rheostat on button 1 flash the current through the tube. (4) If the current is not passing through the tube in the right direction reverse the pole changer switch. (5) Advance the rheostat, with intermittent flashes, until the desired amount of current passes through the tube. According to the machine used and to the length of time the operator wishes to give for exposure, the current sent through the tube may be anywhere from 10 to 20 milliamperes to as much as 40 or 50 milliamperes. (Practically all machines of this type are equipped

* See page 349 for Soft Tube Technic.

with milliammeters.) If the machine used is a very small one (one of the special dental machines) all of the resistance of the rheostat is usually cut out, if the machine is a large one, from a half to three-fourths of the resistance of the rheostat is cut out.

If, when the current is first flashed through the tube, some sparking occurs at the parallel spark gap, lower the vacuum of the tube by reducing the tube regulating spark gap to an inch or so and, *with the rheostat on a very low button,* turn the current on for about 2 or 3 seconds. If the rheostat is advanced too far when the vacuum of the tube is lowered, too much current will pass through the regulating chamber and the vacuum of the tube will be made too low. *Transformer tubes require very little vacuum regulation* and the less done the longer the tube will give good service.

When lighting a tube with a transformer no manipulation is necessary to eliminate inverse current from the tube, for the machine produces no inverse current. This simplifies the manipulation for tube lighting tremendously.

Summary of Technic for Lighting X-Ray Tube with D.C. Transformer.

The technic for lighting an X-ray tube with a D.C. transformer is so much like the operation of an A.C. transformer that a summary of it would be simply a repetition of technic already given. There are, however, two points of difference to which I direct your attention.

The first step in operating a D.C. transformer is to start a rotary converter and this is done by means of a switch and rheostat.

Because the current from the rotary converter, and not the line current, enters the primary of the transformer in a D.C. transformer, polarity of the terminals always remains the same, unless the pole changing switch is changed. Thus it is not necessary to test the current through the tube or observe an indicator each time to learn which way the current is flowing when using a D.C. transformer as it is when using an A.C. transformer. Once the operator learns which terminal is positive he may depend on it this terminal will remain positive always, unless the pole changing switch is changed and he may connect his tube to the coil accordingly.

Posing the Patient and Adjusting the X-Ray Tube and Film or Plate.

Dental radiographs, or odontoradiographs, have been divided into two classes: (1) The intra-oral and (2) the extra-oral. Intra-oral radiographs are made by holding films in the mouth; extra-oral radiographs are made on plates, or films, usually plates, placed outside of the mouth for exposure.

Intra-Oral Radiographs

It makes no difference what sort of a radiograph is to be made, it should always be borne in mind, while posing the patient and adjusting the tube and plate, or film, that you are using your X-rays as a source of light to cast a shadow of some object—*i.e.*, the object being radiographed—on a screen—*i.e.*, the film or plate.

To impress this idea more firmly in your mind observe Fig. 82. The source of light, the candle, casts a distorted—an elongated—shadow of



Fig. 82.

the object, a plaster of Paris tooth, on a white screen. As you observe this illustration contemplate what would have to be done to overcome the extreme distortion of the shadow and make it approximately the same length as the tooth. Is it not true that either the light must be moved upward or the screen must be placed more nearly parallel with the tooth, or perhaps a little of both? If you follow this reasoning you are on the way to making proper poses for radiographs, for the principle involved is the same.

The ideal pose for making a radiograph is to have the focal ray, or central ray, indicated by the pointer at the end of the cylinder in Fig. 83, directed to strike the object being radiographed, and the plate or film,

at right angles. (See Fig. 70.) This is impossible much of the time in the practice of radiodontia.

Distance Between X-Ray Tube and Patient.

As the beginner first attempts posing patient and adjusting his tube his first question is, "How close should I place the tube to the patient?" If the tube stand used is one with a cone or cylinder, the length of the cone or cylinder will govern this. The cone or cylinder will almost touch the patient. If a shield like the one shown in Fig. 64 is used let the distance between the glass of the tube and the patient's face be anywhere from 6 to about 12 inches.



Fig. 83.

Proper posing can be taught best by observation of illustrations, but before proceeding further with the subject of posing we should stop and consider the films used for dental X-ray work.

Dental X-Ray Films.

The Eastman Kodak Co. supplies films especially prepared for intra-oral dental X-ray work, in three sizes: No. 1 film 1¼ by 1⅝ inches, No. 1A film 1½ by 2¼ inches and No. 2 film 2¼ by 3 inches. These films are supplied in packets, two films to a packet, wrapped in black paper to protect them from ordinary light, over which is wrapped oil paper to protect them against moisture when placed in the mouth. The most popular size is the No. 1.*

* A new size film, 1¼ by 2 inches, suggested by the writer for the posterior teeth, has just been placed on the market.

There are two kinds of Eastman X-ray films: "Positive" films and "negative" films. The names "positive" and "negative" are misleading. They give one the idea that there is some difference in the films without suggesting at all what the difference is. The differences between the "positive" and "negative" Eastman X-ray films are: The "positive" is less sensitive than the "negative" film; it therefore requires a longer exposure than the "negative" film and need not be handled with the same care in the dark room. Radiographs made on the "positive" film are more "contrasty" than those made on the "negative" film.

It is a matter of interest to know how the names "positive" and "negative" happen to be applied to the Eastman films. The first films supplied to the dental profession for X-ray purposes by the Eastman Co. were cinematograph—*i.e.*, motion picture films—cut to the proper size and covered with black paper. There are two kinds of cinematograph films, the negative and the positive. The negative is the one used in the motion picture cameras to obtain the original negatives of the scenes and action



Fig. 84. A, rubber dam stretched out and fastened to a board with pins. B, the rubber covered with cement and the film packet on it. C, pins removed from one end and the rubber lapped over packet. D, all pins removed. E, excess rubber trimmed off.

pictured. The positive film is the one used to make the "reels" used in the projection lanterns at the motion picture theaters. The "reels" made on the positive film, for the projection lanterns are made from the original negative made on the negative film. It is not unlikely that the words positive and negative will soon be displaced by the words slow and fast: The positive films will be known as the slow films, the negative as the fast films.

Besides the films prepared especially for dental X-ray purposes, the Eastman Co. also makes films of all standard sizes—*i.e.*, 4 by 5 inches, 5 by 7 inches, 6½ by 8½ inches—put up in light-proof packages of 1 or 2 doz. films.

If he desires to do so the operator may, in his dark room, cut these larger films to any desired size or shape and cover them with black paper himself. For protection against moisture he may cover the black paper with rubber dam—Fig. 84. Or he may take a piece of mending tissue, such as is used by tailors to mend clothing, of such size that when folded over the film packet (Fig. 84C and D) it will extend beyond the packet

on the three open sides, about one-half inch. Warm the edges of the tissue slightly by passing it over the flame of an alcohol lamp, or Bunsen burner, and pinch them together. Then warm them (the edges) to stickiness again and turn them back and stick them to the tissue covering the back—*i.e.*, the non-sensitive side—of the film packet.

There is no particular advantage derived from preparing one's own film packet, and the practice is rapidly being discontinued. When the X-ray machine used is small and the time of exposure is long, it may be found expedient sometimes to give more protection against moisture than is afforded by the oil paper of the prepared film packet.

For the time being, owing to the war in Europe, the Eastman is the only available X-ray film so far as I am able to learn. The Ilford and the Schleussner are X-ray films manufactured abroad.

Fig. 85. Position of film in mouth for making radiographs of the upper cuspid, bicuspid and first molar region.

The smooth side of the Eastman film packet, the opposite side to the one on which the ends of the covering paper lap, represents the sensitive side of the enclosed films. When placing the film packet in the mouth have the sensitive side of the films—*i.e.*, the smooth side of the packet—present toward the teeth. Except when intensifying screens are used (see index: intensifying screen) the sensitive side of films and plates always present toward the object to be radiographed and the X-ray tube.

Poses for Upper Posterior Teeth.

With the film placed in the mouth as per Fig. 85 the pose should be as in Fig. 86. Figure 87 is a diagrammatic illustration of the pose shown in Fig. 86.

With the film placed in the mouth as per Fig. 85, Fig. 88 represents an incorrect pose. The angle at which the X-rays are directed at the

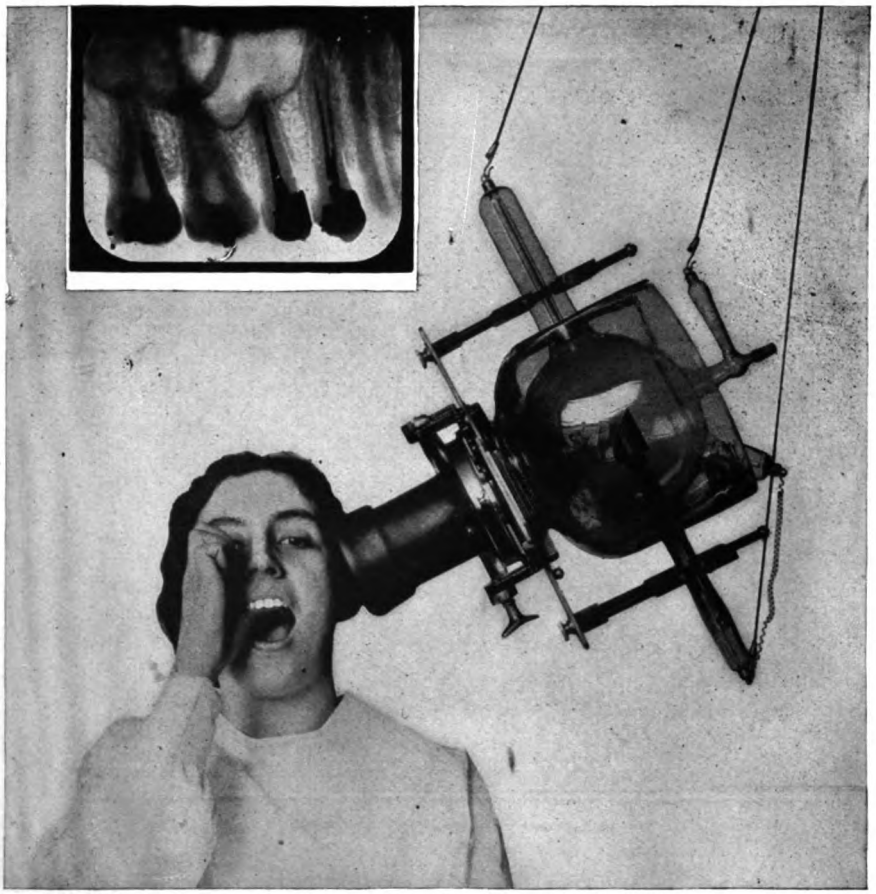

Fig. 86. The correct pose for making radiographs of the upper bicuspid and molar region and a radiograph made from the pose.

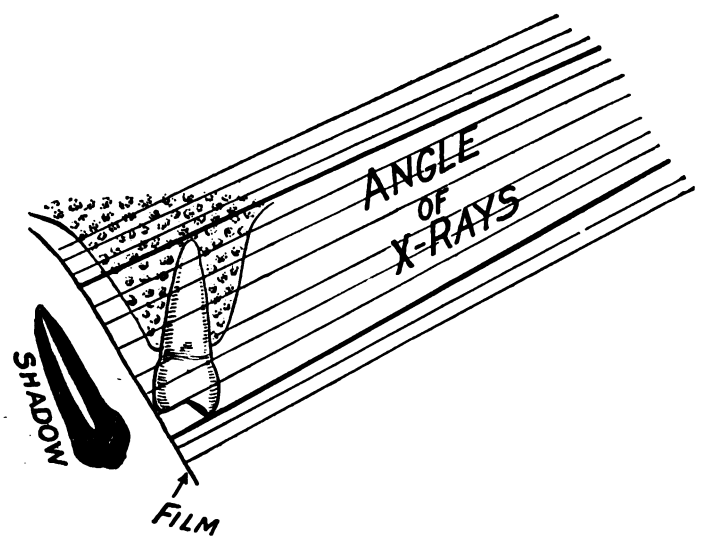

Fig. 87. Diagrammatic illustration of pose seen in Fig. 86, showing the X-rays striking the tooth and film at such an angle as to avoid either lengthening or shortening of the shadow cast on the film. (Schematic drawing after Dr. Price.)

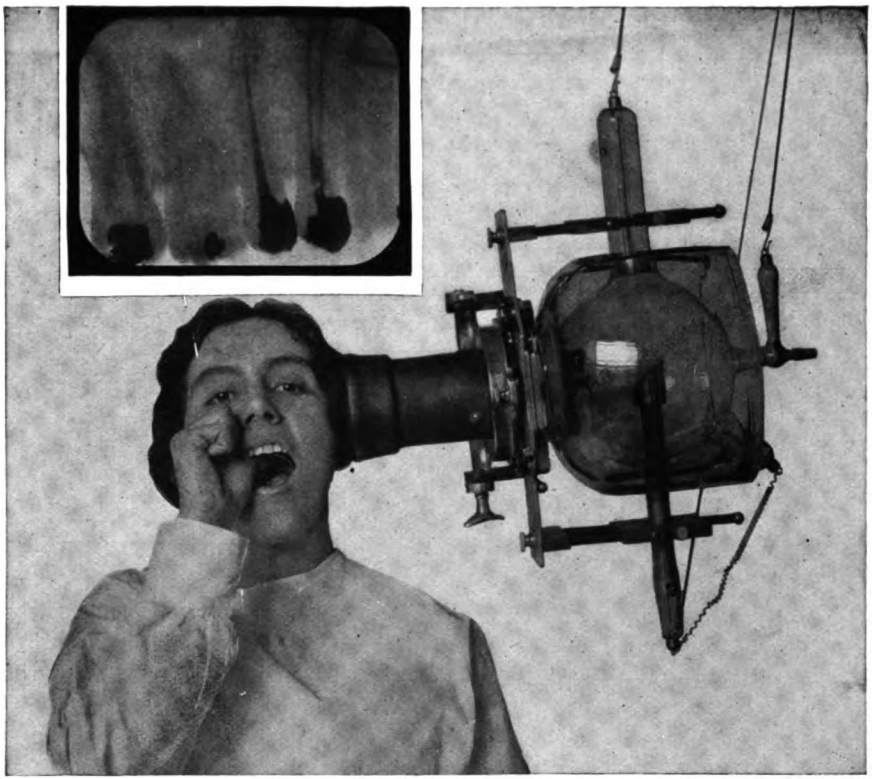

Fig. 88. Incorrect pose for radiographing the upper bicuspids and molars, and a radiograph made from the pose.



Fig. 89. Diagrammatic illustration of the pose seen in Fig. 88, showing the X-rays striking the tooth and film at such an angle as to cause elongation of the shadow cast on the film.

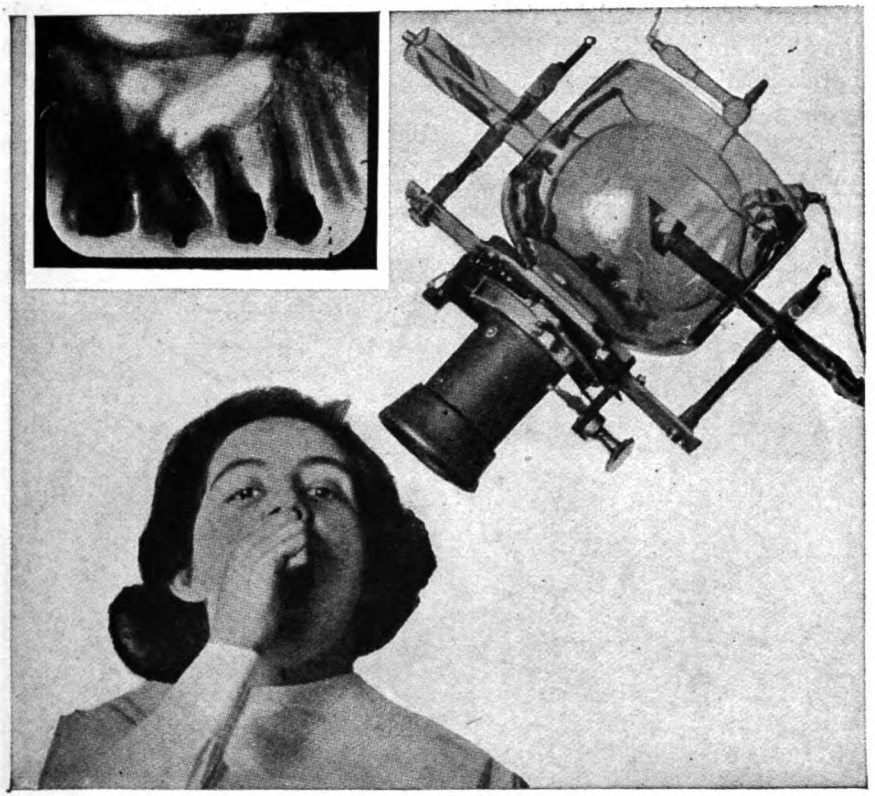

Fig. 90. Incorrect pose for radiographing upper bicuspids and molars, and a radiograph made from the pose.

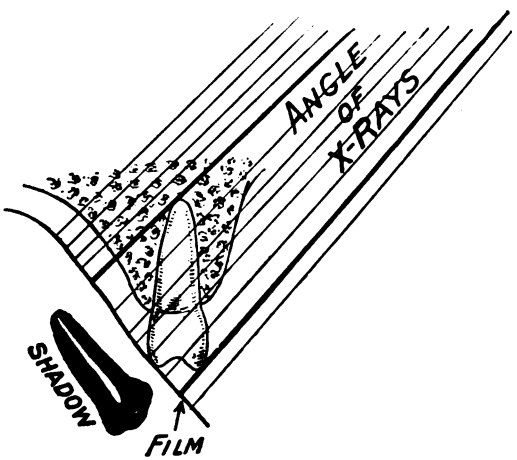

Fig. 91. Diagrammatic illustration of the pose seen in Fig. 90, showing the X-rays striking the tooth and film at such an angle as to cause shortening of the shadow cast on the film.

teeth and film is not right. This position of the tube would be correct, if the film were parallel with the teeth; but it is impossible to place the film in this relation to the upper teeth. Fig. 89 is a diagrammatic illustration of the pose shown in Fig. 88.

With the film placed in the mouth as per Fig. 85, Fig. 90 illustrates another incorrect pose. The X-rays do not strike the teeth and film at the correct angle and the teeth in the resulting radiograph are too short. Fig. 91 is a diagrammatic illustration of the pose shown in Fig. 90.

A study of Figs. 87, 89 and 91 will show that in order to make a radiograph which will not picture the teeth too long nor too short the

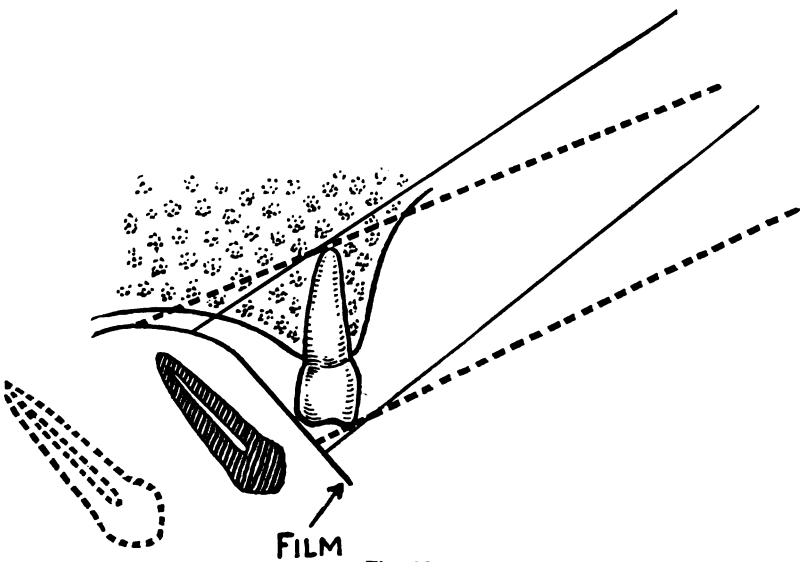

Fig. 92.

X-rays should strike the film almost, but not quite, at right angles to its surface. This same idea has been expressed thus: "The X-rays should be directed at right angles to a neutral line drawn between the film and the tooth." Another writer expresses the same idea so: "Bisect the angle made by the plane of the teeth, and the plane of the film, and direct the rays so they will fall perpendicularly to this bisecting plane."

The angle of the film in Figs. 87, 89 and 91 is what it would be in the average mouth. Suppose, however, the vault is very flat. In such an event the angle of the X-rays as illustrated in Fig. 87 to be correct, would cause a marked lengthening of the shadow, as illustrated by the dotted lines and drawing in Fig. 92. The angle of the X-rays should be as in Fig. 91 to avoid, as nearly as possible, any distortion. (Notice in Fig. 92 that the bending of the film would cause a lengthening of the shadow.)

Just in proportion as the vault becomes more flat the film departs from the vertical and the tube must be at a different and higher angle. And so, inversely, as the vault is higher the film may be placed more nearly parallel with the teeth and the tube may be lowered.

From the foregoing it will be understood why we can never be *sure* that our radiograph gives the *exact* length of upper teeth.

By making slight changes in the positions of the film as illustrated

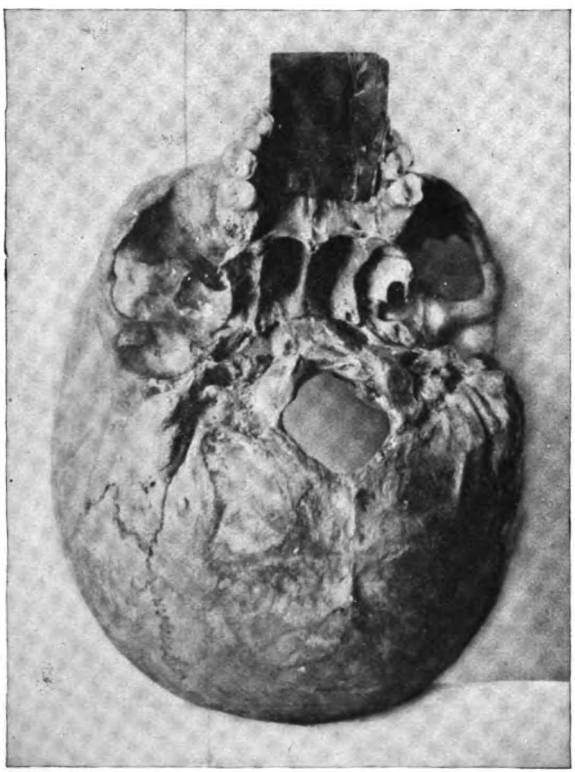

Fig. 93. Position of film in the mouth for radiographing upper anterior teeth. See pose Fig. 94.

in Fig. 85 and the tube as illustrated in Fig. 86, all of the teeth from the third molars forward to the cuspids (and in some mouths the laterals) can be radiographed.

Pose for the Upper Anterior Teeth.

Figure 93 illustrates the position of the film for making radiographs of the upper anterior teeth. While bending of the films is to be avoided as far as possible, because it causes distortion of the radiographic image, when

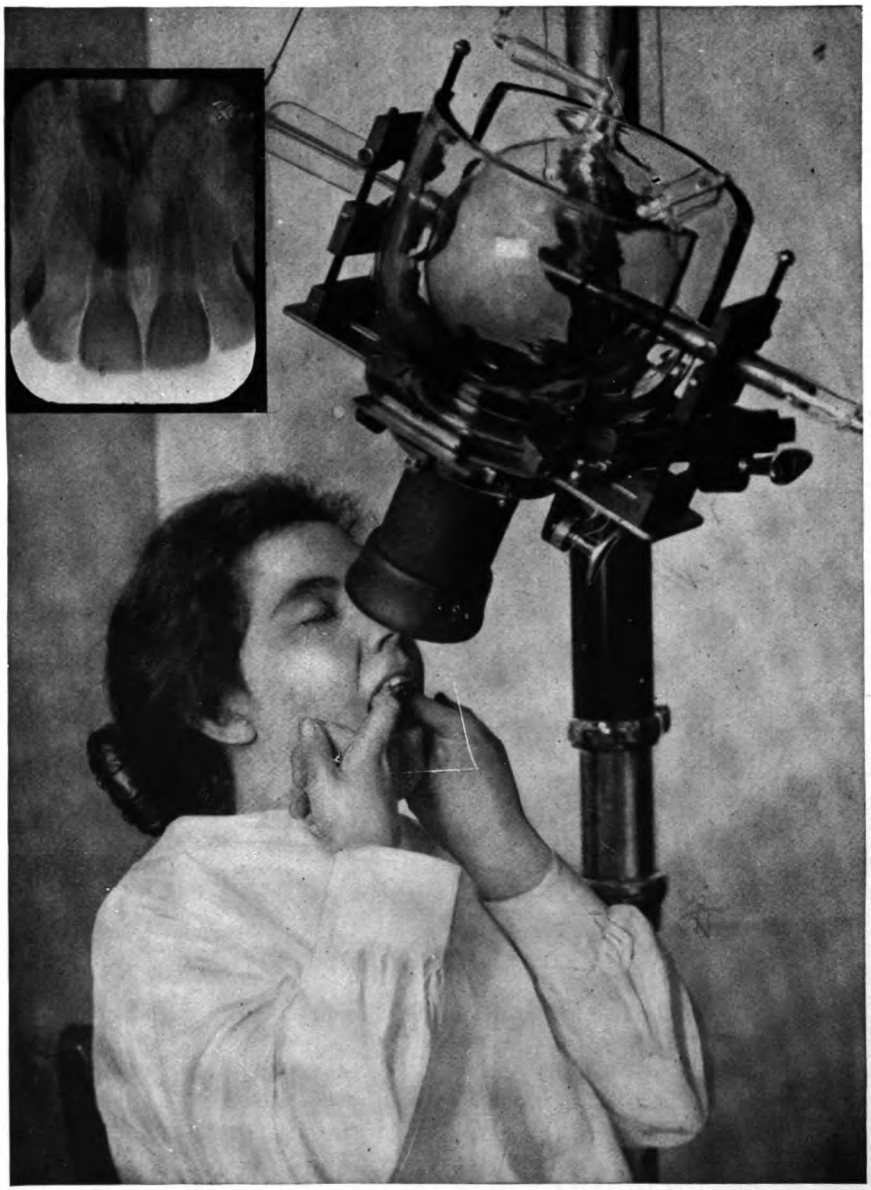

Fig. 94. Correct pose for radiographing upper anterior teeth with film in the mouth as in Fig. 93. Radiograph made from this pose. (It took the writer a long time to learn that, when radiographing upper anterior teeth, it is best to try to radiograph only two teeth at a time, to bend a part of the film deliberately in order to avoid bending all of it (Fig. 101) and to have the patient hold it with the thumb, not the fingers or finger.)

the film is placed in this position it is sometimes unavoidable, especially in a mouth with a V-shaped dental arch. A small ball of cotton under the film, in the palate, will sometimes assist in preventing too much bending, without at the same time holding the film too far away from the teeth.

With the film placed in the mouth as in Fig. 93, the pose for making radiographs of the upper anterior teeth is illustrated in Fig. 94.

Another position for the film when making radiographs of the upper teeth is illustrated in Fig. 95. The sensitive side of the film presents toward the teeth. The film is held in position by having the patient close the mouth. Fig. 96 illustrates the pose with the film in the position shown

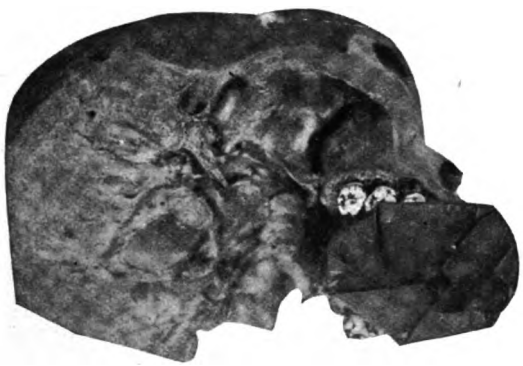

Fig. 95. Position of the film in the mouth for pose and radiograph seen in Fig. 96.

in Fig. 95. A radiograph made in this way is liable to considerable distortion. The radiograph in Fig. 96 was made when radiographers prepared their own film packets, cutting a film of the desired size from a large film and wrapping it in black paper. I quote from the first edition of this book: "After making a radiograph as shown in Fig. 96, it may be trimmed to a more symmetrical form. In other words, the film, as wrapped up in a film packet may be left an indefinite, unsymmetrical form and trimmed to a more pleasing outline after the radiograph is made."

Poses for the Lower Posterior Teeth.

With the film placed in the mouth as shown in Fig. 97, the correct pose for making radiographs of the lower molar region is illustrated in Fig. 98. Note that the rays are directed at the teeth and film at right angles. If the radiograph resulting from this pose does not show the apices of the



Fig. 96. The pose with the film in the mouth as in Fig. 95 and the radiograph made from this pose.

teeth, press the film down farther if possible. If this cannot be done the tube must be tipped, slanting the rays upward, something like the rays are slanted downward for the upper teeth, or the head may be tipped sideways from the tube which accomplishes the same thing.

With the film placed in the mouth as shown in Fig. 99 the pose for making radiographs of the lower cuspids and bicuspids is illustrated in Fig. 100. Note that the rays are directed *disto*-lingually and slightly upward.

Poses for the Lower Anterior Teeth.

Figure 101 shows the film packet placed in position for radiographing the lower anterior teeth. Note that about ten millimeters of the packet is bent abruptly backward. This is done because the packet is too wide for the dental arch and it is better to bend back a part of the film abruptly, and so allow the film to go to place, than to bend the entire film in an effort to get it into a space too narrow for it. A little cotton between the film and inner surface of the dental arch sometimes helps in preventing undue bending of the film.

Figure 102 is the correct pose for making radiographs of the lower anterior teeth with the film in the mouth as per Fig. 101. Owing to the

Fig. 97. Position of the film in the mouth for radiographing the lower molars. See pose Fig. 98.

difficulty in placing the film parallel with the teeth, without bending the surface of the film too much, it is usually necessary to tip the head backward and direct the rays upward and lingually in order to make the apices of the roots show in the radiograph.

With the film placed in the mouth as shown in Fig. 95, except that the sensitive side presents toward the lower teeth, a radiograph may be made from the pose shown in Fig. 103. Such a radiograph is liable to great distortion.

A study of Fig. 104 will assist the operator materially in directing the rays through the parts at the proper angle. From this illustration one can promptly see why the shadow of the mesiobuccal root of upper molars is usually thrown to the mesial of the lingual root, while the shadow of

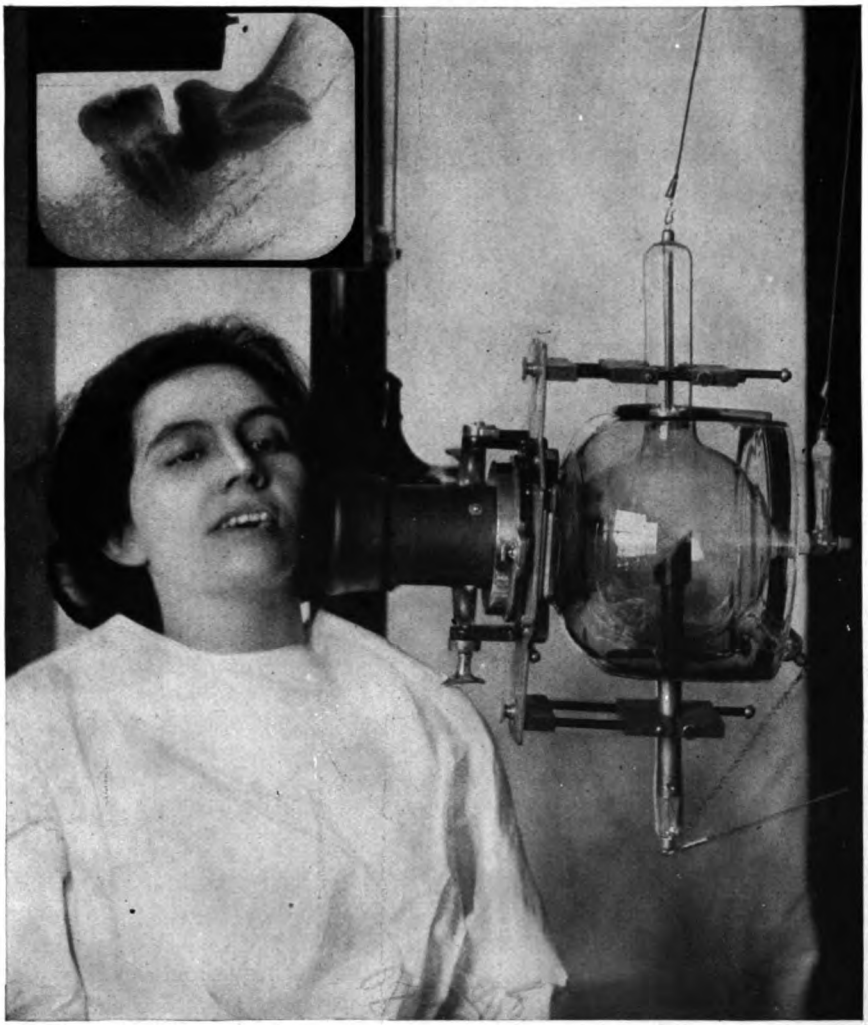

Fig. 98. Pose for radiographing the lower molars with the film in the mouth as in Fig. 97. Radiograph made from this pose. The film holder in use is illustrated in Figs. 331, 332 and 333.

the disto-buccal is superimposed on the lingual root. (Fig. 105.) The shadow of the disto-buccal root can sometimes be thrown to the distal of the lingual root by directing the X-rays through the part in a *disto*-lingual direction.

When radiographing lower molars it is often necessary to direct the rays through the part in a *disto*-lingual direction to obtain a clear outline

of the roots. This sometimes superimposes the two mesial canals one over the other. Observe the roots of the second molar on the reader's left in Fig. 104 and note that directing the rays straight through—*i.e.*, at right angles to the long axis of the tongue—would cast the mesio-buccal canal on the film to the mesial of the mesio-lingual canal.

Methods of Holding Films in the Mouth.

There are various methods of holding the film in the mouth during its exposure to the X-rays. The different poses, already illustrated, show the methods

Fig. 99. Position of film in the mouth for radiographing lower cuspid and bicuspid region. See pose Fig. 100.

now in use by the writer. For the upper teeth, the patient holds the film, with the thumb usually. For the lower posterior teeth the film holder illustrated in Fig. 333 is used. For the lower anterior teeth the patient holds the film with the finger or with the Leach film holder. The set of Leach film holders, designed by Dr. Floyd Leach of Chicago, illustrated in Fig. 106, have been in the hands of the writer only a few days now—

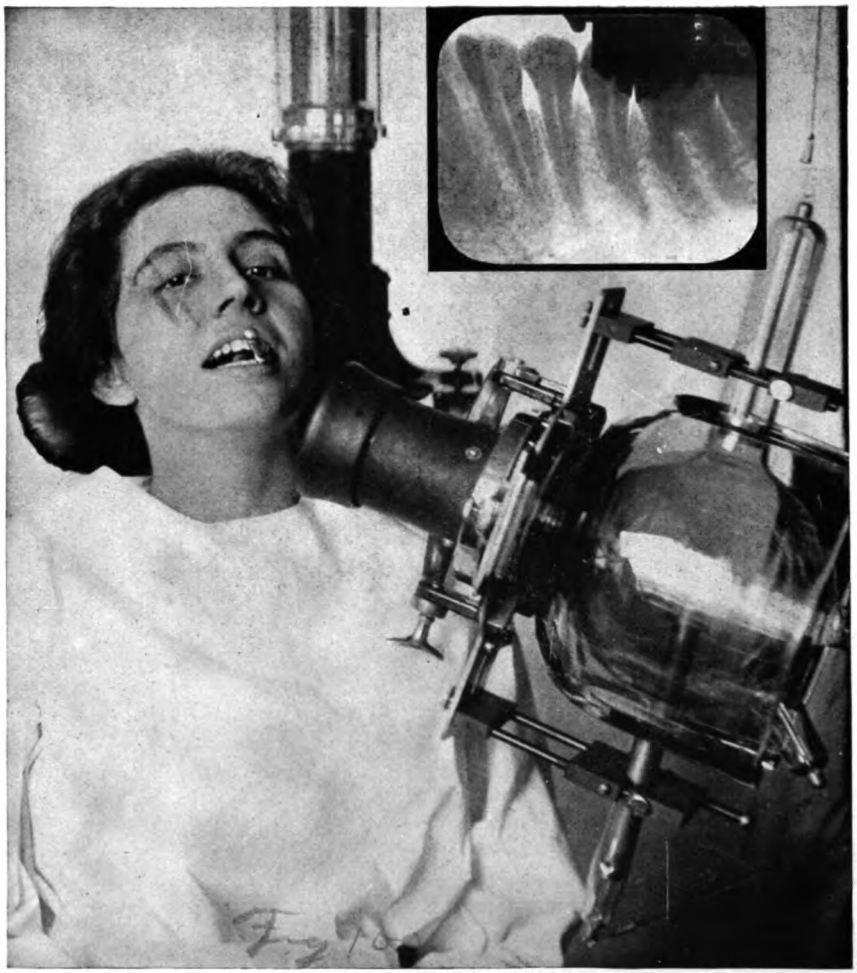

Fig. 100. Pose for radiographing the lower cuspid and bicuspid region with the position of the film as in Fig. 99. Radiograph made from this pose. Tipping the tube is not necessary and not advisable if the film can be placed down far enough.

an insufficient length of time to give them a fair trial. It may, nevertheless, be stated that the Leach film holders will be found very useful, especially to the beginner.

Dr. Tousey, of New York City, and Dr. Ketcham, of Denver, have also designed special dental film holders.

I am not inclined to consider the question of the operator or assistant holding the film, further than to warn you against the practice. (See

chapter VIII.) Do not do it; the repeated exposure is dangerous. Have the patient hold the film.

Some difficulty due to gagging is sometimes experienced when the film is held in position for upper second and third molars. To patients who will not tolerate the film in this location, I sometimes say this: "I know you cannot keep from gagging when something tickles your palate. But, did you know this? you can keep from gagging *as long as you can hold your breath.*" Unless the X-ray machine used is a small one the

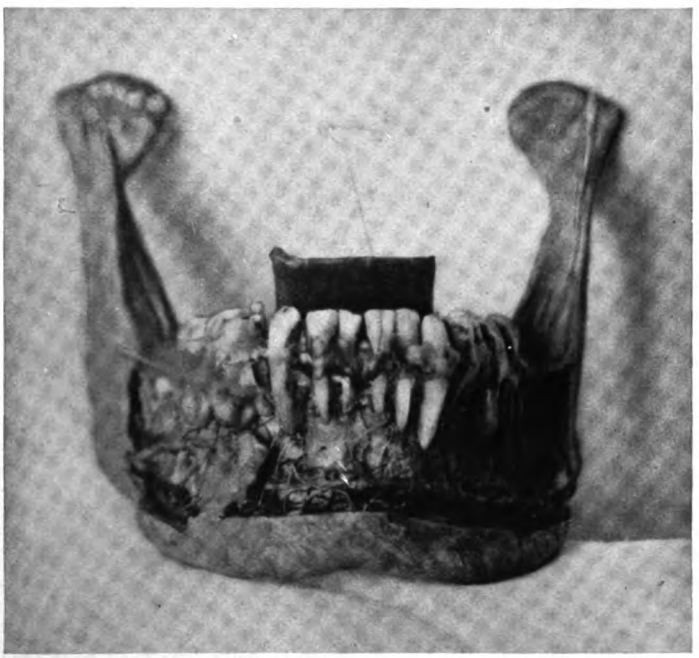

Fig. 101. Position of film for radiographing lower anterior teeth. See pose Fig. 102. The principle, here illustrated, of deliberately bending a part of the film in order to avoid bending all of it, is, perhaps, the most important and fundamental single thing to be learned about the application of films to the mouth. This principle is applicable not only to the lower anterior region, but to other parts of the mouth as well, particularly the upper anterior part. To make the radiograph illustrated in Fig. 102 the film was bent abruptly backward a little on both sides instead of on one side only as illustrated here.

exposure can be made while the patient "holds the breath." (The psycho-therapist may analyze this treatment for gagging to his heart's content.)

Extra-Oral Radiographs.

Plates are usually used in preference to films for extra-oral radiographs because they are easier to handle and cheaper. If the negative is to be sent through the mail it is best to make it on a film. If films are used, two films may be exposed simultaneously and so two negatives made from one exposure. This is always an advantage in that if one film is not developed

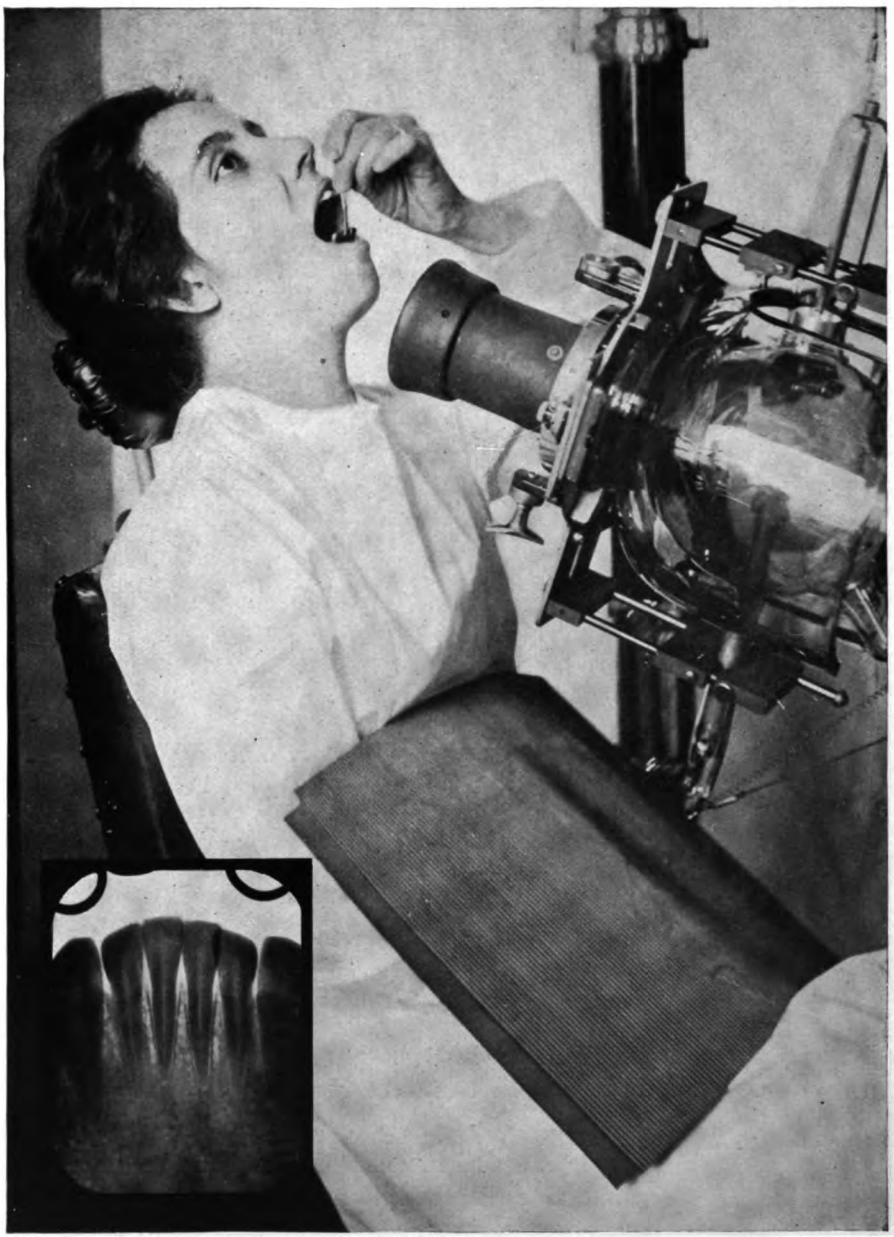

Fig. 102. Pose for radiographing the lower anterior teeth with the position of the film as in Fig. 101. Radiograph made from this pose. (Note the rubber matting covering the patient where one of the terminals of the tube is brought close to the body. The rubber matting acts as an insulation preventing sparking of the current into the patient.)

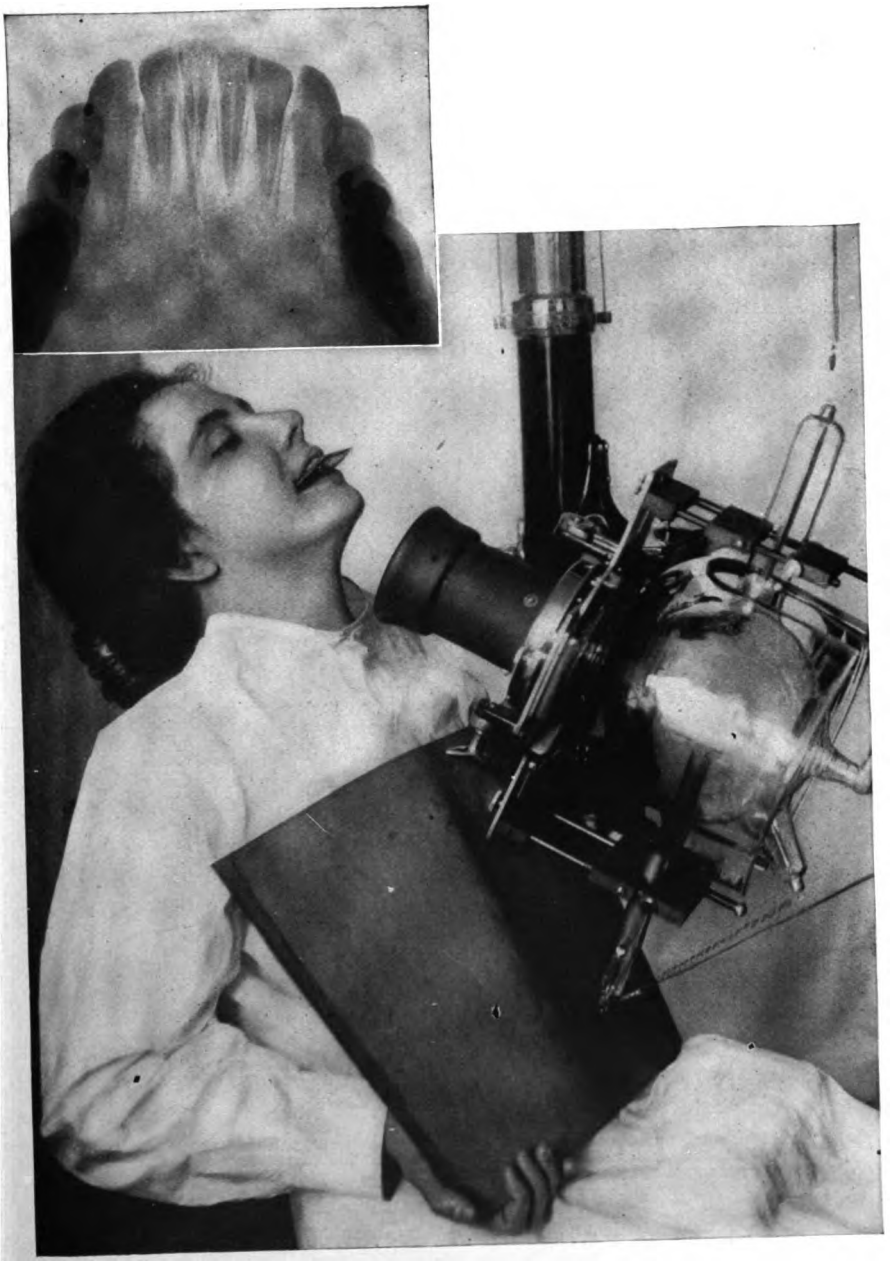

Fig. 103. Pose for radiographing the lower anterior teeth with the film flat against the occlusal surfaces and incisal edges. Radiograph made from this pose. (Note rubber matting insulation again.)

properly or becomes spotted or mutilated in some way the mistake or accident may be corrected when the other film is developed. Also, if the case is a referred one, one negative may be kept on file, and the other

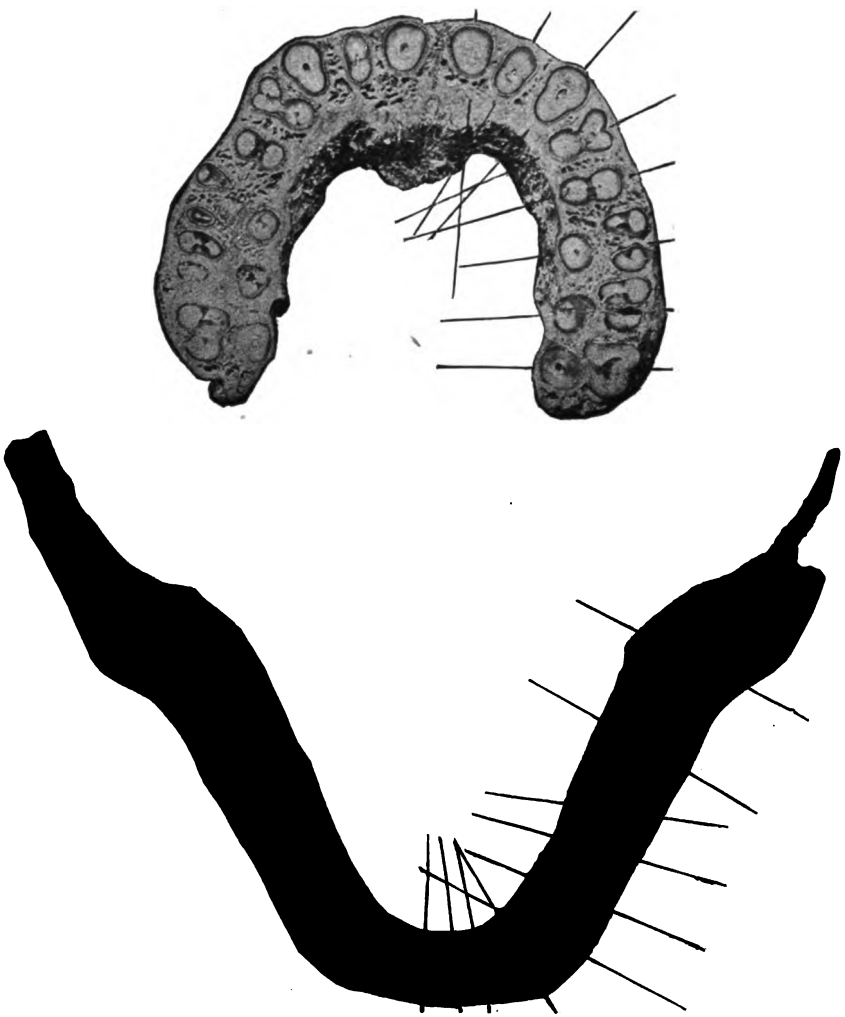

Fig. 104. Horizontal section of the upper and lower jaws cut a little beyond the free margin of the alveolar process, showing the forms and positions of the roots of the various teeth. (From Cryer's "Internal Anatomy of the Face.")

sent to the dentist or physician who referred the patient. The Eastman dental films, No. 3, 4 x 6 inches, and No. 4, 8 x 10 inches are prepared in packets containing "a pair" of films, for extra-oral work.

A number of manufacturers supply special X-ray plates. (See chap-

ter IV, page 66.) The Brady product is particularly worthy of consideration because, when it was first placed on the market it was the "fastest" X-ray plate thus far made, and so it enabled men with small X-ray machines to do extra-oral dental radiographic work, who had hitherto found this work impossible, owing to the limited power of their machines and the insufficient sensitivity of X-ray plates to the action of the X-rays.

The size of the plate used for extra-oral work may be 4 x 5, 5 x 7, 6½ x 8½ or 8 x 10 inches. As the operator learns to pose his patient and adjust his plate and tube with accuracy he will use a smaller plate. The beginner had perhaps better start by using the 8 x 10-inch plate. The size of the plate selected will, of course, depend primarily on the size of the field the operator wishes to place under radiographic observation.

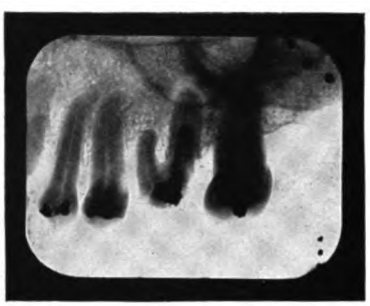

Fig. 105. Radiograph showing three roots of the upper first molar; the mesio-buccal root is to the mesial, the disto-buccal root and the lingual root are superimposed one upon the other.

For the technic of handling the plate preparatory to making the radiograph see Chapter IV, pages 68, 69 and 70.

Pose for the Posterior Teeth.

The best possible advice I can give the man who contemplates doing any amount of extra-oral dental radiographic work is that he obtain a skull and refer to it often to assist him in posing his patient and adjusting the plate and X-ray tube. He should also make many experimental, test radiographs of the skull.

Extra-oral radiographs are made by having the patient lay the head against the plate—which rests on a flat surface—and directing the rays through the parts from above. (Figs. 107 and 108.) The side next to the plate—*i.e.*, the side farthest from the X-ray tube—is the one being radiographed in such a position. The big problem in posing for radiographs of this kind is to so arrange the plate, the patient's head and the tube as to prevent superimposition of the two sides of the mouth.

Superimposition of parts may be avoided, to variable extents, in three ways. (1) By tipping the tube in such a way as to direct the rays through the parts diagonally. (Fig. 107.) (2) By the use of an incline plane—wooden pillow or wedge—23 degrees. (Fig. 108.) (3) By directing the patient, who will first naturally assume the position shown in Fig. 107, to "turn the head until the nose touches, or almost touches, the plate." (By having the patient turn the head farther, until the nose is flattened to one side against the plate, satisfactory radiographs of the lower anterior teeth may be made.)

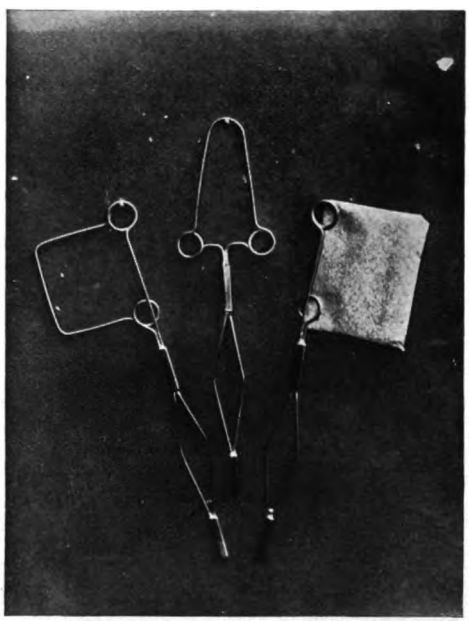

Fig. 106. Leach film holders. The holder in the middle is seen in use in Fig. 102.

The tube should not be tipped as in Fig. 107 when the incline plane is used: When the incline plane is used direct the rays straight downward.

Figure 109 is the radiograph made from the pose shown in Fig. 108.

As has been indicated in Figs. 107 and 108, extra-oral dental radiographs may be made with the patient lying on a table or seated on a chair or stool with the head placed on a stand or table. Figure 110 illustrates a special tube stand attachment on which the head may be placed. Figure

110 also illustrates a device for holding the head immovable. The writer prefers the reclining position, however, when sufficient office space will permit the use of a table.

Pose for the Anterior Teeth.

While satisfactory radiographs of the lower anterior teeth (see above) may be made on plates, placed extra-orally, sufficiently clear radiographs of the upper teeth cannot be obtained by any means thus far devised, on plates so placed.

Fig. 107.

Poses for the Cranial Sinuses and Cells.

There is such similarity in the symptoms caused by dental lesions and those produced by diseases of the cranial sinuses and cells that the radiodontist is not infrequently called upon to make a differential diagnosis. The cranial sinuses and cells are (1) the maxillary sinuses, or antra, (2) the frontal sinuses, (3) the ethmoid cells, (4) the sphenoid cells and (5) the mastoid cells.

With the patient's face placed against the sensitive side of the plate, Fig. 111 illustrates a standard pose for making radiographs to give an

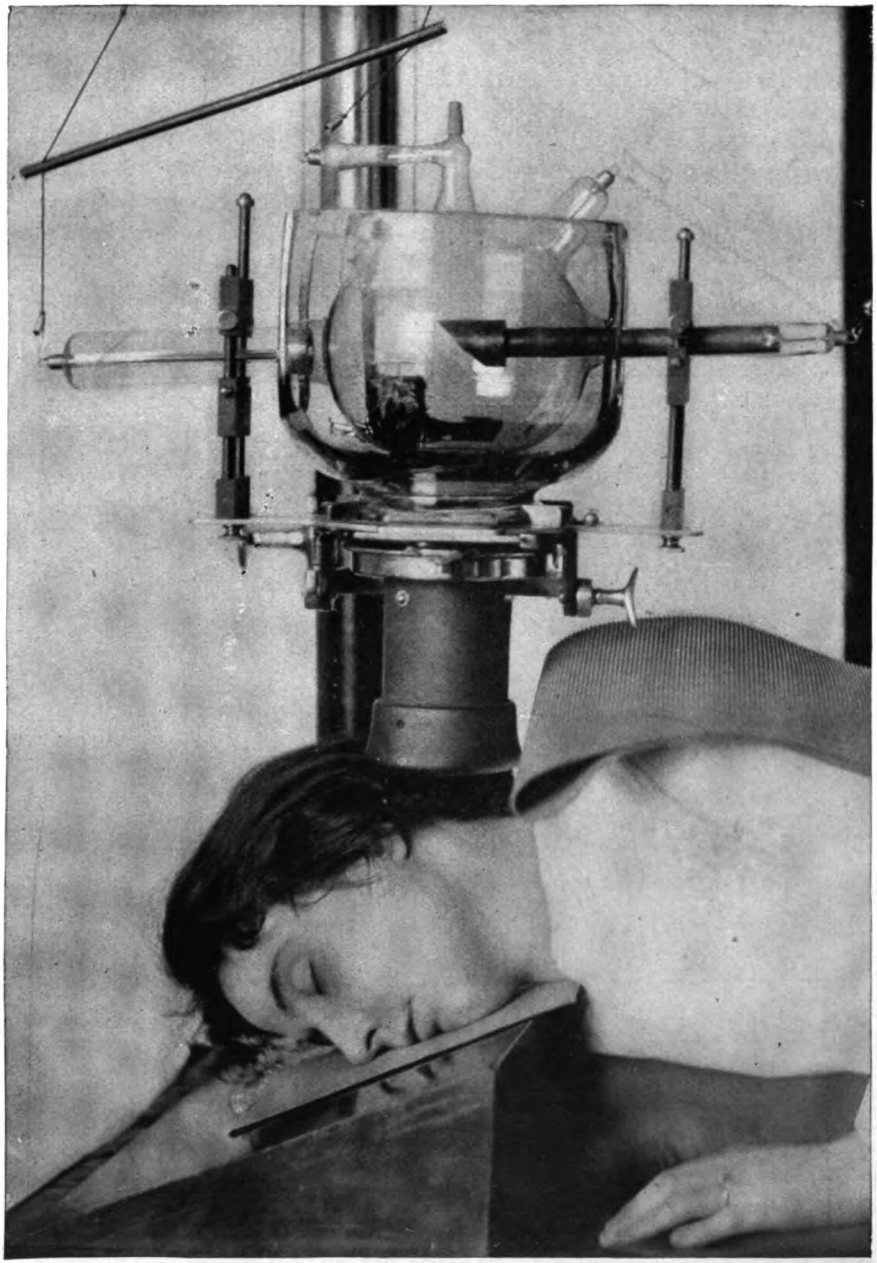

Fig. 108. Pose for making the radiograph seen in Fig. 109. The patient is lying on a table. (Note the little stick which holds apart the wires attached to the regulating chamber and the cathode end of the tube. This very simple "wire spreader" will often be found quite useful.)

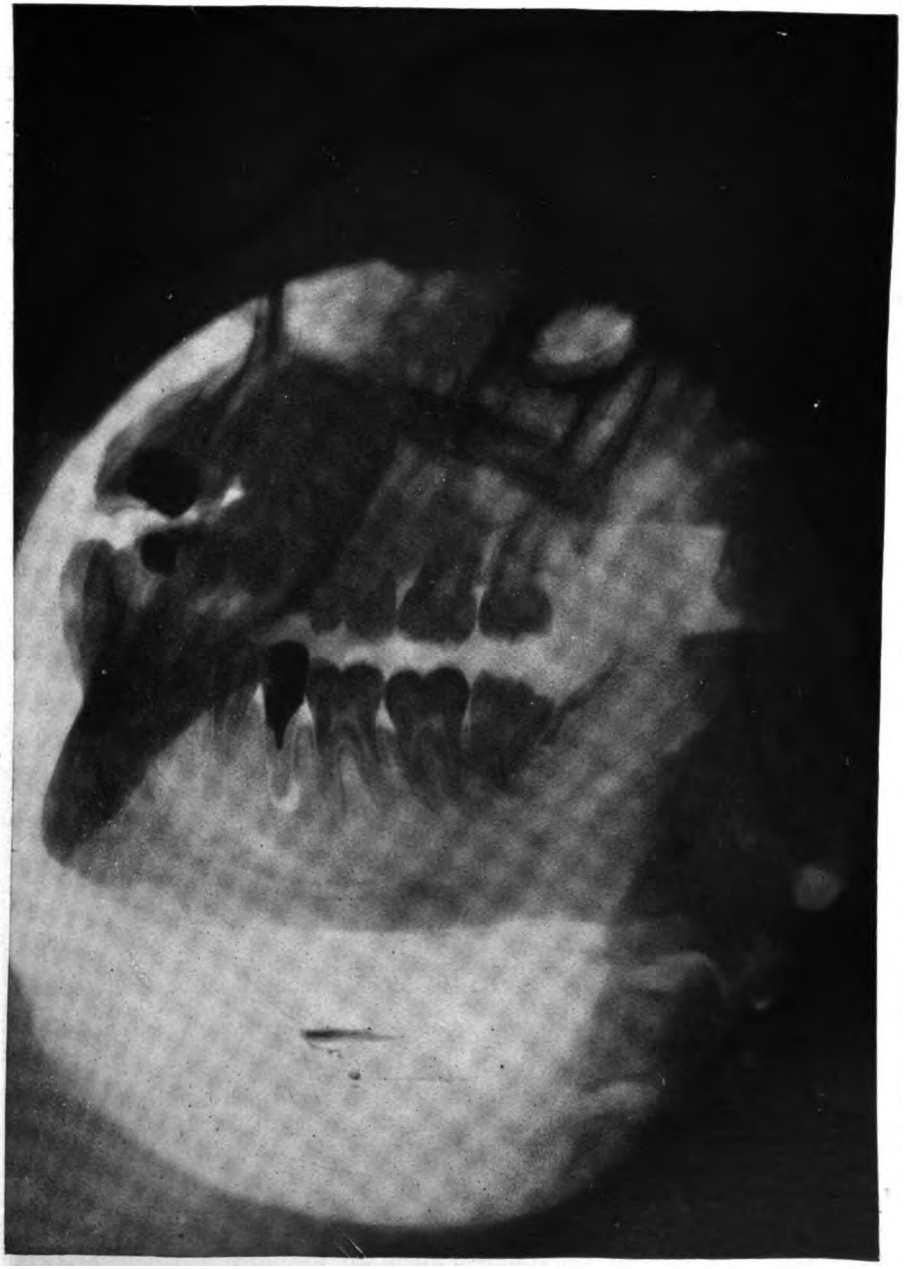

Fig. 109. Radiograph made from pose illustrated in Fig. 108.

anteroposterior view of the frontal sinuses, the ethmoid cells and the antra. (A better pose is illustrated and diagramed in Appendix Chap. V.) Observe Figs. 112 and 113 made from this pose. (Figure 111 shows one end of a small chain attached to the metal of the tube-manipulating apparatus. The other end of the chain is attached to a gas jet or water pipe. This is called " grounding the current " to keep it from jumping a small air gap into the patient. The tube is, of course, insulated from the metal of the tube-manipulating apparatus and cylinder, but, because the electric current in use is of such high potential or pressure,

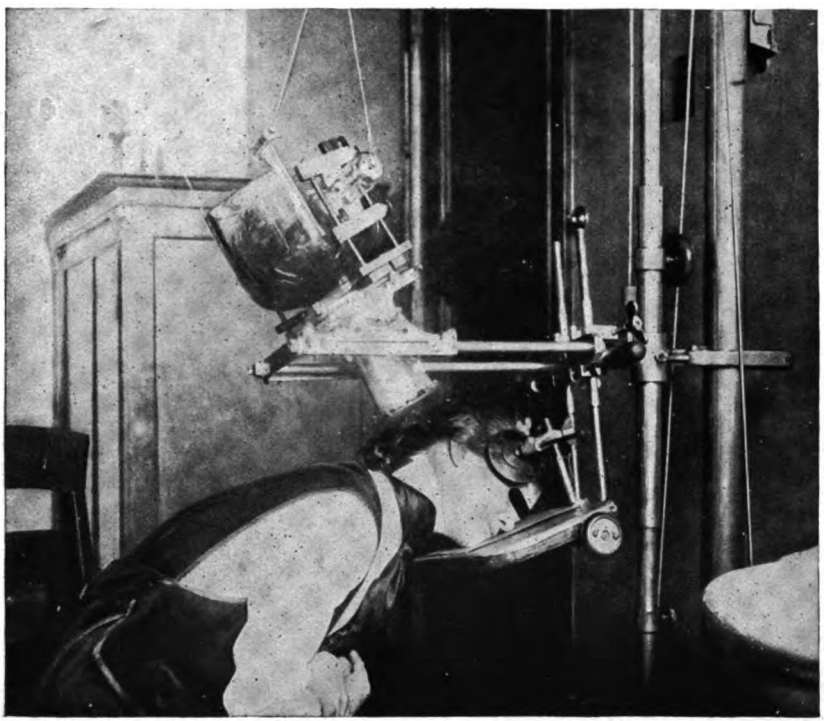

Fig. 110. Tube stand with attachment for making extra-oral radiographs. (Photograph by Dr Eisen.)

some current may, nevertheless, get into the metal parts, and from there to the patient. With a small chain, or any electric conductor, attached to the metal of the tube-manipulating apparatus and the other end attached to a gas jet or water pipe the current will not jump an air gap into the patient but will pass into the chain and through it to the gas or water pipe, eventually reaching the earth *possibly*—hence the name grounding. If the current jumps a small air gap into a patient a spark occurs, due to the atmospheric resistance, and the sensation experienced by the patient is very definitely unpleasant.)

Figure 114 is, in results obtained, the same as the pose illustrated in

Fig. 111. In Fig. 114 an incline plane is used and the rays are directed straight downward.

A studied observation of Fig. 112 will reveal to the reader a horizontal shadow across the antra. If you will remove the skull cap from a skull and look at the floor of the cranial cavity you will see that this shadow represents the petrous portion of the temporal bone. The tube is

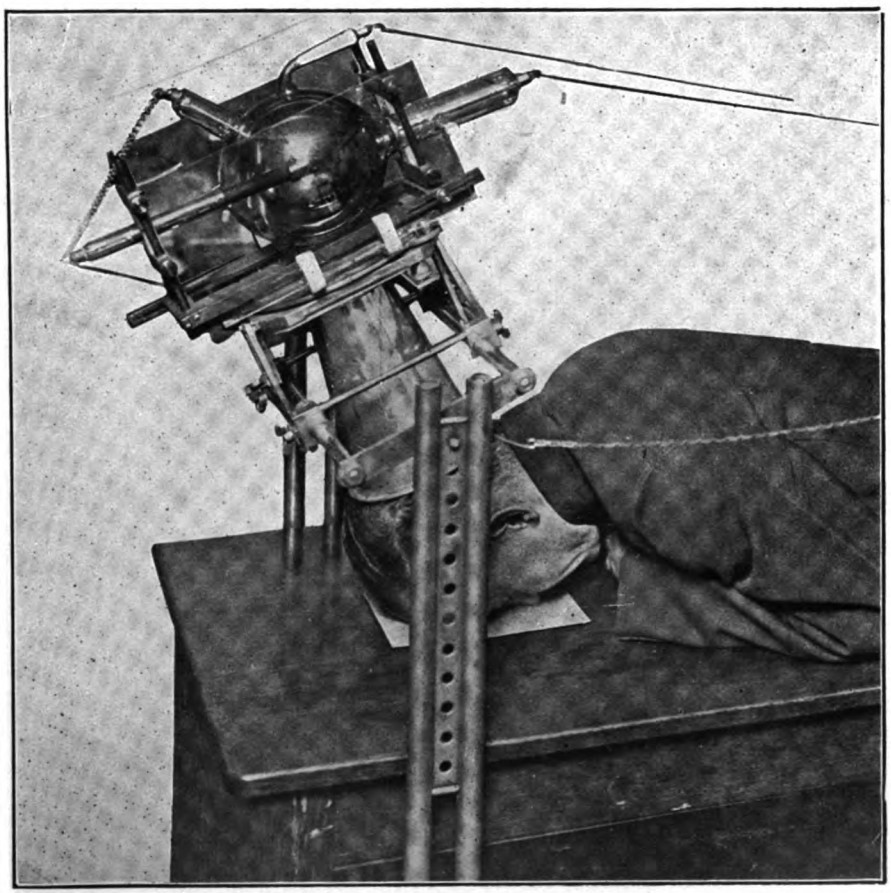

Fig. 111. Pose for making radiographs of the Antra of Highmore.

tipped (Fig. 111) or an incline plane is used (Fig. 114) in order to throw this shadow as far downward toward the teeth as possible.

A straight-through lateral view of the antra may be made to locate foreign bodies in it. (Figs. 277 and 278.)

Intra-oral radiography of the antra is not a success. (See Fig. 275. Text on page 235 and 236.)

Figure 276 was made from a pose similar to Fig. 108. One antrum,

the one closer to the plate, is outlined with the dotted lines, the other may be seen as the light area, to the reader's left and a little above the outlined antrum.

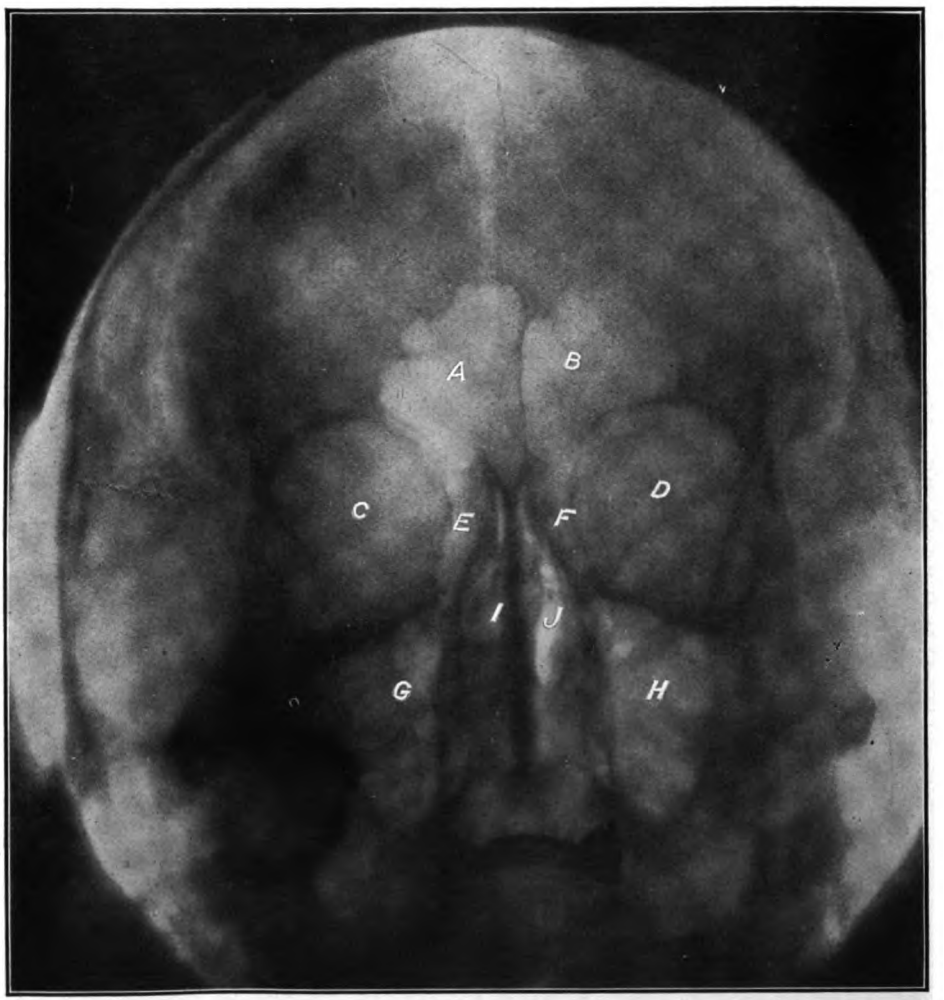

Fig. 112. Radiograph made from the pose illustrated in Fig. 111. A, B, frontal sinuses. C, D, orbits. E. F, ethmoid cells. F does not show as well as E because the cells of this side are full of pus. G, H, Antra of Highmore. I, J, nasal cavity. As an aid in reading the radiograph observe Fig. 113.

The sphenoid cells are situated back of, and a little below, the ethmoid cells. Radiography of these cells is very difficult and in the hands of most operators attended with little success. (See Appendix, Chap. V.)

For a consideration of the radiography of the mastoids see Appendix, Chap. V.

Exposure

When the patient and tube are properly posed, before placing the film or plate in position, flash the current through the tube once or twice so that the patient may become acquainted with the light and noise pro-

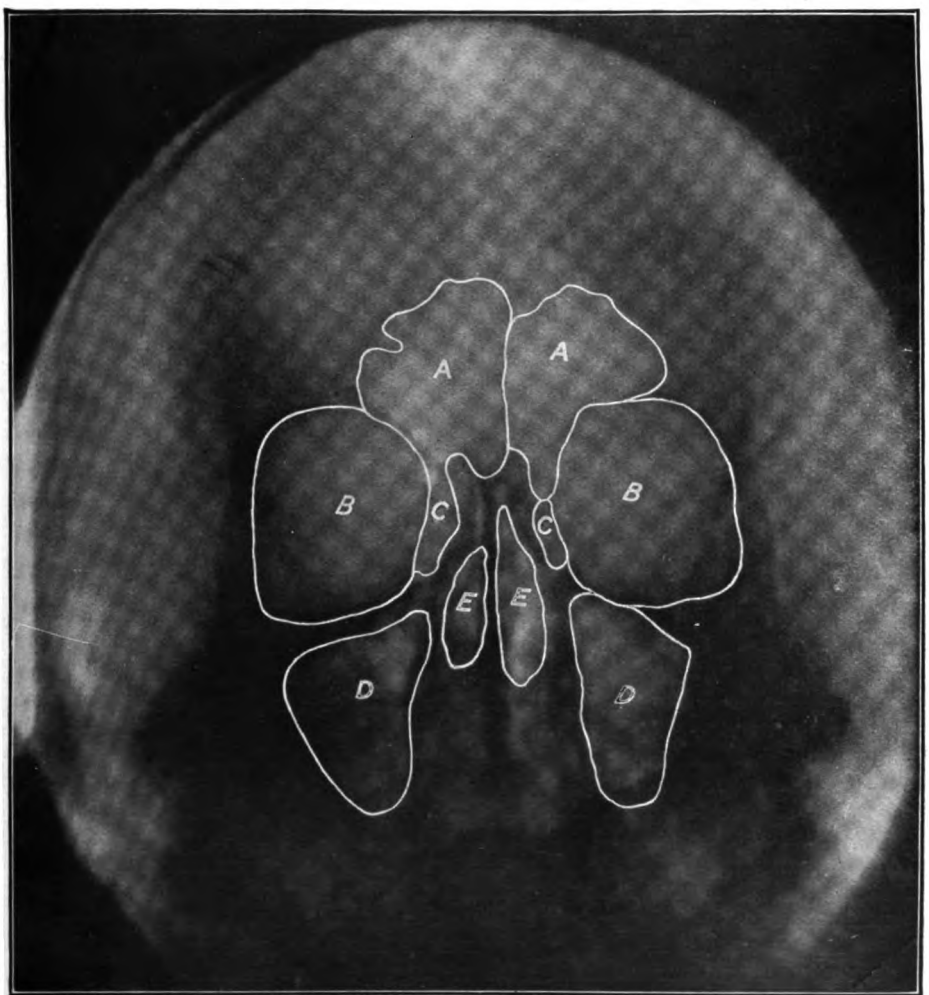

Fig. 113. Same as Fig. 112. A, frontal sinuses. B, orbits. C, ethmoid cells. D, antra. E, nasal cavity.

duced. Otherwise the patient might be startled when the current is first sent through the tube, move, and so spoil the radiograph.

All films, plates and photographic paper should be kept in a lead, X-ray-proof box, except just at the time of exposure. Fig. 115.

When making radiographs of the lower teeth with the film in the

mouth the patient should be warned not to swallow during the exposure. Movement of the tongue in swallowing would move the film.

Time of Exposure. As stated in Chapter IV (see on page 71) a number of things influence the time of exposure necessary. For example, if the exposure necessary when using the slow Eastman film is 4 seconds, all other factors may remain the same, and the exposure necessary for a fast Eastman film will be only *about* 1 second.



Fig. 114. Pose for frontal sinuses, antra and ethmoid cells using incline plane.

Distance Between Target and Film or Plate. The distance between the target of the tube and the emulsion of the plate, or film, exerts a great influence on the time of exposure necessary. This distance varies from about 10 to 20 inches. The time of exposure necessary varies directly with the square of the distance. The square of 10 is 100, the square of 20 is 400. Thus the exposure at 20 inches should be four times as long as at 10 inches. It has been suggested that the distance between the target and the film be standardized at about 20 inches. This is all right for men with large machines but the men who use the smaller machines will find it expedient to have the distance less.

Age increases the density of osseous tissue and so the time of exposure necessary to make dental radiographs varies slightly directly according to the age of the patient.

The time of exposure for the molars, intra-orally is a *little* longer than for the other teeth because the rays must penetrate the malar bone for the upper molars, and the oblique ridges for the lower molars.

Exposure With the Different Types of X-Ray Machines. Since the type and size of X-ray machine used governs the milliamperage sent through the X-ray tube, obviously this governs to a great extent the time of exposure necessary. Taking into account the machines of all

sizes *which are in general use* the time of exposure necessary with INDUCTION COILS, for intra-oral dental radiographs, varies from a fraction of a second to about 15 or 20 seconds, for extra-oral dental radiographs, from about 1 or 2 seconds to about 45 seconds; with HIGH-FREQUENCY COILS, for intra-oral dental radiographs, from about 3 to 30 seconds, for extra-oral dental radiographs, from about 12 seconds to about 1 minute; with TRANSFORMERS, for intra-oral dental radiographs, from a fraction of a second to about 5 seconds, for extra-oral dental radiographs, from a fraction of a second to about 10 seconds.

INDUCTION COILS, of various sizes operating at their full capacity, are capable of forcing from 4 or 5 to about 18 + milliamperes through a tube backing up 5 or 6 inches of parallel spark; HIGH-



Fig. 115. Lead-lined, X-ray-proof box for photographic supplies.

FREQUENCY COILS from about 3 to about 8 milliamperes; TRANSFORMERS from about 12 to about 60 + milliamperes. (The plus mark placed after milliamperage 18 for induction coils and 60 for transformers is put there in recognition of exceptional X-ray machines of these types which are capable of delivering a higher milliamperage. As I say, however, these largest machines are exceptional, *i.e.*, not the type of machine commonly met with.) Ordinary X-ray tubes, gas tubes, as they are called since the advent of the new Coolidge tube, could not take a current of 60 milliamperes for much longer than about 1 second continuously without injury to the tube from overheating.

When the time of exposure is over 5 seconds it is best to make the exposure intermittently: turn the current on for 5 seconds then off for 5 seconds, then on for 5 seconds and so on until the desired time of exposure

is given. This avoids overheating the tube, and so lowering of the vacuum by heating the regulating chamber.

When the time of exposure is 1 or 2 seconds, or less, an automatic time-switch may be used to advantage. Fig. 116.

X-ray tubes should not be used until they become so hot the hand can not be placed on them. Heating takes place particularly in the region of the cathode. If used until hot a tube should be allowed to cool before it is used again. If much radiographic work is being done it is economy to



Fig. 116. Automatic time switch or "timer," by means of which seconds may be split.

have at least three tubes. (The new Coolidge is an exception to this rule as it is to almost all rules regarding X-ray tubes.)

With the milliamperage, the condition of the tube, and the emulsion on the plate remaining the same, it requires an exposure *about* four times as long for an extra-oral dental radiograph as for an intra-oral one. This increase in the length of time necessary for the extra-oral dental radiograph is due to increased distance between the target and film, increased thickness of tissue to be penetrated by the rays and increased distance between the object being radiographed and the plate.

The exposure necessary for frontal sinus and antrum radiographs with the pose as in Figs. 111 and 114, is longer than for radiographs of any other part of the body. To avoid straining tubes for radiographs of this kind it is often expedient, and with small machines necessary, to use an intensifying screen.

Intensifying Screens

An intensifying screen is a piece of paper or card board covered with some such material as calcium tungstate or platino-barium cyanide. By its use exposure may be shortened from ½ to 4/5.

The coated side of an intensifying screen is placed against the coated side of the film, or plate, and both screen and film are placed in the light-proof packet as usual. Thus we get a double action on the film when it is exposed, the action of the X-rays themselves and the action due to the fluorescence of the intensifying screen.

When using an intensifying screen the uncoated side of the film should present toward the object being radiographed. This is contrary to the rule that to obtain the best results the coated side of the plate or film should present toward the object to be radiographed.

The advantages of the intensifying screen are: (1) Just in proportion as it reduces the time of exposure it protects both patient and operator against any ill-effects of the X-rays. (2) By shortening the time of exposure the life of the tube is lengthened. (3) By using an intensifying screen one is able to do tolerably rapid work even with a small coil.

The disadvantages of the intensifying screen are: (1) It causes a granular appearance of the negative, blotting out detail. (2) It is liable to spot the negative, due to unequal fluorescence of its surface. (3) It fluoresces for a minute or so after exposure, and if the plate and screen do not maintain their exact relation to one another blurring of the negative results. (4) For intra-oral dental work unless one owns several screens, so that a number of film packets may be made at a time, their use necessitates the making of a film packet before each exposure, which is discommoding.

Such grosser lesions as an impacted tooth, for example, can be radiographed satisfactorily with the intensifying screen, but when we wish to obtain detail, such as is necessary to observe pulp stones or a necrotic condition, for example, the use of the intensifying screen is contraindicated. An intensifying screen disintegrates with use.

Because, as I have said, the intensifying screen fluoresces for some time after the exposure has been made it has been the practice of radiographers to lay the plate and screen aside for some time before disturbing their relation to one another. Dr. Sidney Lange, however, believing that the continued fluorescence will cause blurring of the negative even though the relation of the screen to the plate be not disturbed, removes the plate from the screen immediately after exposure. His results from this practice are excellent.

Figure 117 is a dental radiograph made with an intensifying screen.

Intensifying screens should be cleaned often by brushing the sensitive side with a very soft brush.

Pertinent Advice. Unless the reader desires to master the method of determining the time of exposure by the milli-ampere-second method (see Appendix to Chap. V, Page 355) the most practical advice I can give is: Learn from the manufacturer of the coil where to set the rheostat and the time he considers right for dental radiographs. Make an exposure, giving the time of exposure advised. Develop the film in Eastman M. Q. tube developer, 6 fluid ounces of water to the tube of developer, for 5 minutes; or use the Brady "four-minute" developer for 4 minutes, or the Brady "6-minute" developer for 6 minutes. Remove from the developer, dip in water and fix in the fixing solution. Now then if the film is too pale, as it probably will be—for most manufacturers seem to think their coils will make dental radiographs in shorter exposures than is really necessary or best—increase the time of exposure, or advance the rheostat, or shorten the distance between the target and film

Fig. 117. Dental radiograph made with an intensifying screen.

and try again. If the negative is too dark, and it has been left in the Eastman developer only 5 minutes or the Brady developer only 4 or 6 minutes, the exposure has been overtimed.

Making the Negative.

The subject of making negatives has already been covered fairly well in Chapter IV.

Choice of Developer. What developer shall we use? I obtained the formulas for the developers used by twelve different radiographers, and they were all different! From this we may conclude that any clean, properly mixed developer will do the work.

However, I would advise the beginner to use one of the developers just referred to in the foregoing, i. e., a developer which will have the desired action in a *known* length of time. When making the developing

Fig. 118. Dark box for use where a dark room is not available.

solution, dissolve the light powder first, then the heavier, white powder. As the operator becomes acquainted with the technic of development he can correct slight mistakes in exposure by leaving the plate, or film, in the developer, say, for example, only 4 minutes in the 5-minute developer for overtimed films, or 7 minutes for undertimed films. It is unnecessary to leave any plate or film in the 5-minute developer longer than 10 minutes. If the image does not appear as it should in 10 minutes it never will; a longer exposure must be made.

If at all possible it is desirable to have a dark room, but if such a room is not available, a dark box may be used. Fig. 118.

Figure 119 illustrates a satisfactory method of hanging film negatives up to dry.

To expedite handling it, when the film negative is dry it may be mounted between 2 pieces of clear glass using passe-partout strips to bind the pieces of glass together or it may be placed in a special radiomount. Figure 120.

If several radiographs are made of the same patient it is best to mount them all between two pieces of glass of suitable size, (Fig. 121) or in a mount of celluloid and card board. (Fig. 121A.)



Film 119. Films hung up to dry.

Summary of Steps in Technic for Making Radiographs. (1) Pose the patient. (2) Test the current through the X-ray tube. (3) Place the film or plate in position. (4) Make the exposure. (5) Make the negative. (6) Prepare the negative for observation and study.

* * * * * * *

Van Woert Daylight Developing Tank. In appearance and size the Van Woert developing tank for dental X-ray films is not unlike the metal box in which we buy Colgate's "shaving stick." In principle it is a light-proof metal box into which a liquid may be poured without opening the box and admitting light.

Technic. Both hands are placed in a light-proof "muff" in which "muff" the film packet is unwrapped, the little tank opened, the films placed in it, and the tank closed. The tank can now be removed from the "muff" and the films inside are protected from light. Pour developing solution in the tank, leave for about 5 minutes, pour out the developing solution. Adjust a screw and water can be washed through the tank. Next pour in the fixing solution and leave 5 or 10 minutes. Pour out the fixer and wash

with water again, when the tank may be opened and the developed film, the negative, observed.

The Van Woert tank is a very practical device for the general practitioner of dentistry who does a limited amount of radiodontic work,

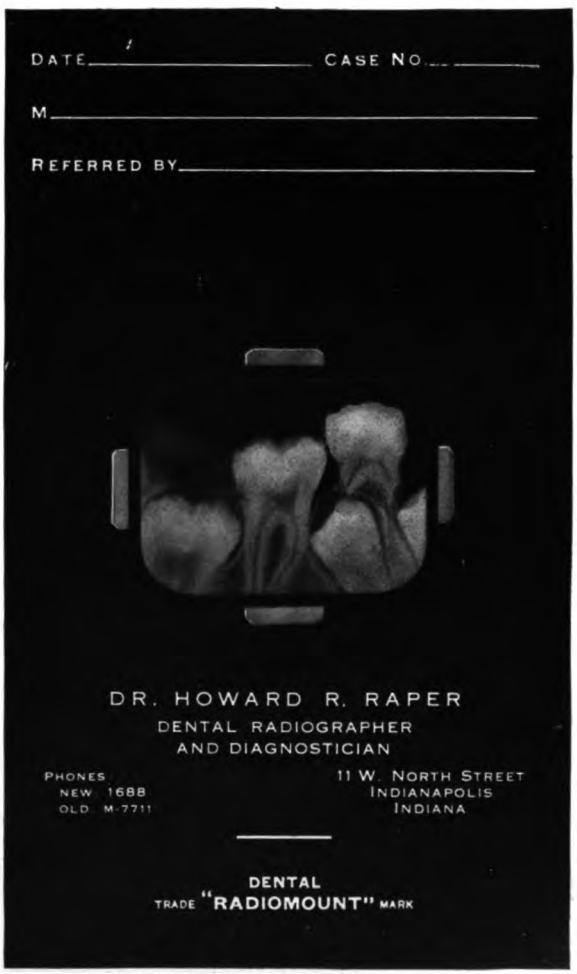

Fig. 120. Radiomount to hold dental X-ray negatives.

on films only; and in offices where there is not sufficient space available for a dark room and where even a daylight developing box (Fig. 118) would be in the way, the little tank will be most welcome. (See Fig. E.)

Fig. 121. Negatives mounted between glass for study and convenience in handling.

Preparation of Negatives for Immediate Use Suggested by Dr. Van Woert.

A hardening solution is made by dissolving 2 oz. of potassium carbonate in 2 oz. of water. This should be filtered and kept in a tightly corked bottle. After removal of the negative from the fixing solution it should be washed in water 5 or 10 minutes before being placed in the hardener. Put enough of the hardening solution in a small beaker or saucer to

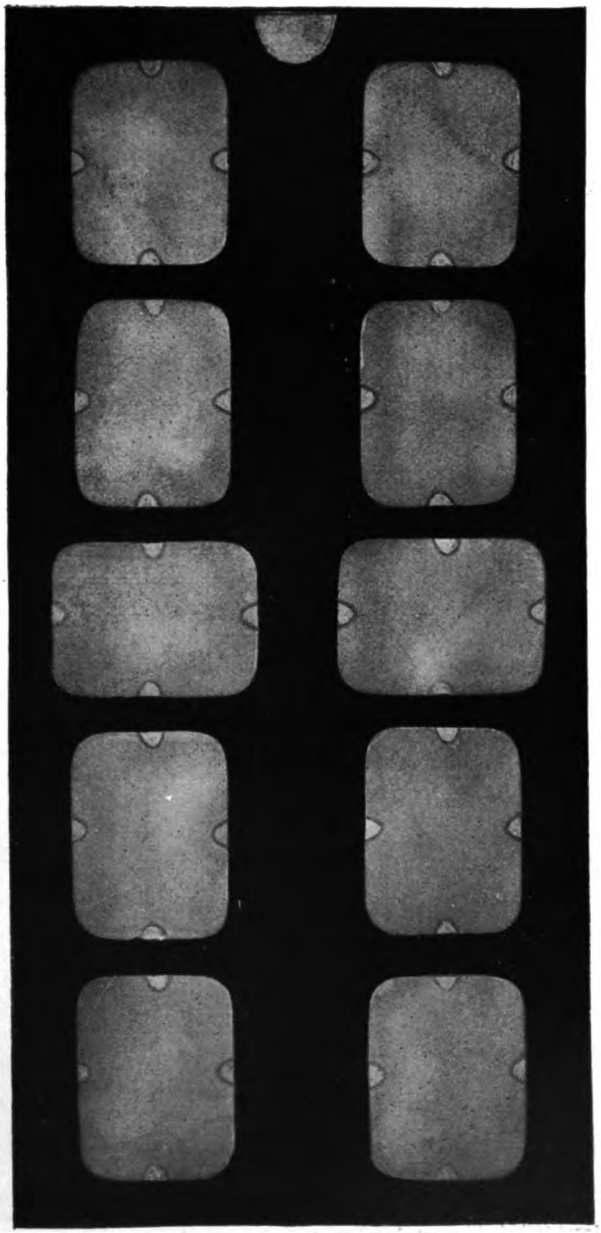

Fig. 121A. Celluloid mounting to hold negatives, for study and convenience in handling.

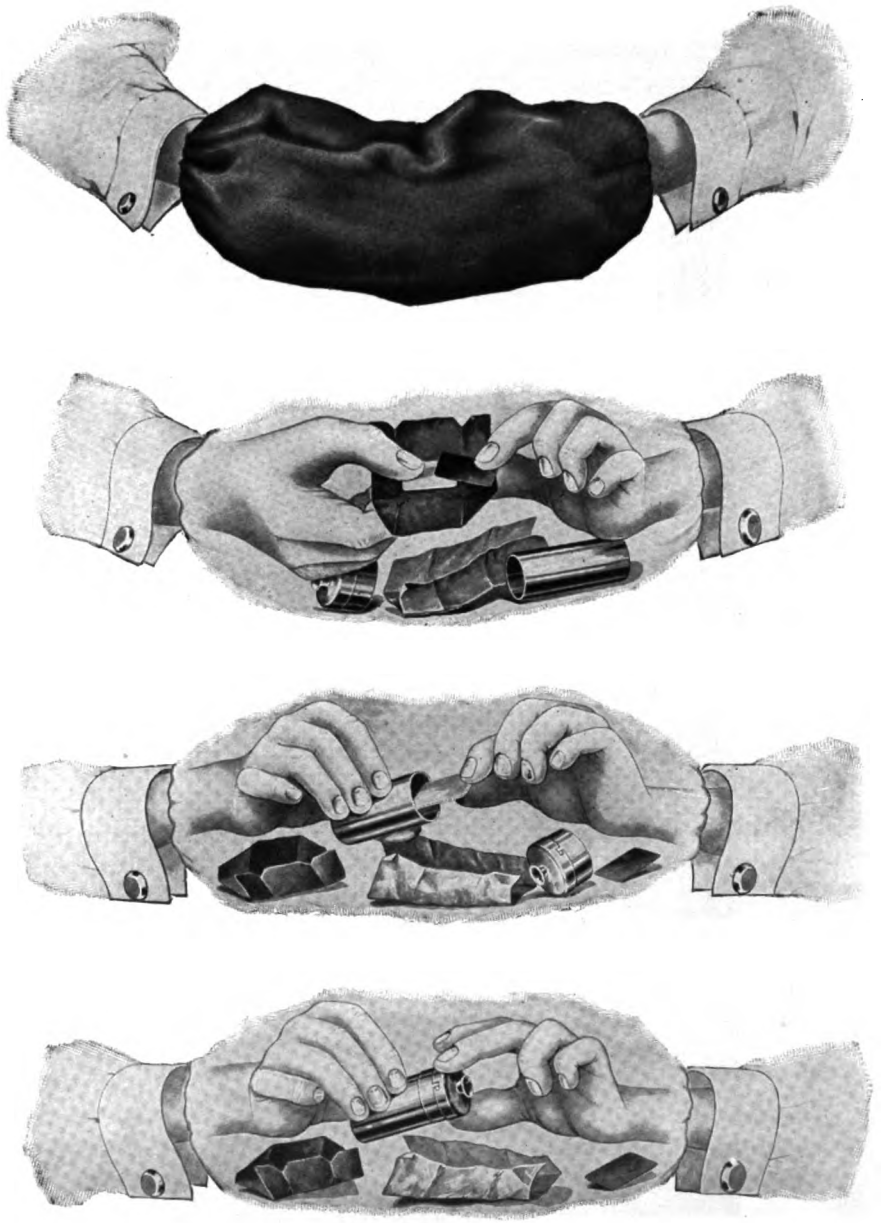

Fig. E. Van Woert technic illustrated. Cut No. 1 shows the hands placed in the muff. Cut No. 2 shows the hands inside of the muff. Cut No. 3 shows the films unwrapped and being placed in the tank. Cut No. 4 shows the tank closed after the films have been placed in it; the tank, with the films in it, may now be removed from the muff.

cover the negative. Leave the negative in the hardener three minutes, when it may be removed and the surplus moisture absorbed by blotting it between pieces of blotting paper. Wipe the emulsion side with a lintless napkin such as the Johnson and Johnson mouth napkin. This process of hardening and immediate drying may be used where the radiograph is required immediately. For such negatives as are to be preserved, they should be washed and dried in the usual way.

* * * * * * *

Advantages of Film Radiographs. The advantages of the small dental radiographs made on films held in the mouth over the large plate radiographs are: (1) There is no superimposition of shadows, and therefore a clearer, better radiograph can be made on the small film. (2) The patient may be seated in the dental chair while the exposure is made when small films are used. (3) The time of exposure is shorter for the small film. (4) Small machines with which it is necessary to make an exposure of one minute or longer for large plate radiographs will make a good dental radiograph on a film held in the mouth in from about 10 to 30 seconds. (5) A compression diaphragm, though always a valuable appliance, is not so essential when small films are used as it is when large plates are used. (6) The negative on celluloid cannot be broken.

* * * * * * *

Advantage of Plate Radiographs. The great advantage of the large plates over the small films is that a larger field can be pictured.

Scratching Film Negatives. As the small dental films lay in the bottom of the trays, during the process of development and fixing it becomes necessary to pick them up repeatedly. As this is done, the finger nail sometimes slips off the edge, across the coated surface of the film, so spoiling the negative or at least mutilating it in a very undesirable manner. With practice one may acquire the knack of picking up film negatives when they lay flat on the bottom of the tray without scratching them, but my assistant has developed a very simple and satisfactory way to pick them up which entirely eliminates the probability of scratching them.

Wash the emulsion off an old negative, or better, take a piece of celluloid thicker than that used to make films and fasten a hook clip, such as is illustrated in Fig. 119 to hang up negatives, to it. This little device my assistant calls a "scooter," which seems to me a very fitting name, for, holding to the metal clip the piece of celluloid may be "scooted" under films, and so they may be lifted from the bottom of trays with great ease. The hooked part of the clip may be placed over the edge of the tray so the "scooter" is not misplaced but is always in position ready for use when needed.

CHAPTER VI.

Reading Radiographs.

Seeing things is truly a mental effort. Though an object or shadow be reflected on the retina of the eye, it is not "seen" unless it has an effect upon the brain. When we say, "train the eye" to see such and such a thing, we mean really, train the mind—the brain.

To correctly read a radiograph, to see all there is in it to be seen, and to understand it to mean what it stands for, requires experience and an intimate knowledge of the anatomy and pathology of the parts under observation. Experience is an important factor. Upon looking over old negatives, I see many things of interest in them now which I did not observe a year ago.

Illuminating Boxes.

It is always advisable to study the negative in preference to the print. Some of the finest details are lost in the print. The negative may be held up to a window or an artificial light, or it may be placed in an illuminating box (Fig. 122) for observation.

While the illuminating boxes on the market are suitable for studying large plate or film negatives, they are needlessly large and poorly adapted for studying the small, dental, film negatives. A small illuminating box can easily be made. A light-proof box, with a window of frosted glass and a light inside, may constitute the illuminating box. It is well to paint the inside of the box white, so increasing the power and uniformity of illumination. With the negative held against the frosted glass of the window on the outside and the light lit inside, one is able to study the negative to great advantage. Little spring steel clips, similar to the ones used to hold a slide or a microscope, may be used to hold the negative against the frosted glass window.

The use of a reading glass in connection with an illuminating box will enable one to observe the negative to the best possible advantage.

The Relative Values of Dense Areas in Negatives.

The denser the part, the deeper will be the shadow thrown on the film, and, consequently, the more transparent the negative in that region. Thus in the negative, metal fillings, posts and metal crowns appear as transparent areas; gutta-percha, cement,

enamel and porcelain a little less transparent; then in the order of their respective densities, dentin, bone, gum tissue, and, last, the cheek appears —when it is shown in the negative at all—as the least transparent part, except that part of the negative on which the X-Rays have fallen directly without anything intervening except the black paper of the packet. The contrast between tooth and bone tissue is very marked. Unfilled canals and pulp chambers appear as dark streaks and areas in the teeth. Filled canals and pulp chambers appear light. Pulp stones appear as lighter



Fig. 122. An Illuminating Box.

spots in the dark of the pulp canal or chamber. Abscess cavities appear as dark areas. It is easy to distinguish enamel from dentin, and the peridental membrane can clearly be seen as a dark streak following the outline of roots. A bit of calculus in the peridental membrane will appear as a light spot. This calculus must be on either the mesial or distal side of a root to be seen. It could not be radiographed if it occurred on the buccal, or labial, or lingual.

Negatives, Prints and Half-tone Reproductions.

All the foregoing may be seen in good negatives, but all this cannot be seen in prints and half-tones. I recall distinctly having read an article on Dental Radiography in which the writer printed a half-tone and told his readers to "observe the enamel, the dentin and the peridental membrane." The writer of this article wrote his

paper with either a negative or a good print before him, and assumed that all he saw there would be reproduced in the half-tone. It was not. The half-tone was so dark that all detail of the picture was lost, and the best that could be done was to distinguish between bone and tooth structure. Let us stop to consider the steps in the making of a half-tone picture and the chance for the loss of detail is apparent. From the negative a new picture is made on photograph paper, the print. From this another picture is made on a half-tone plate, and from this the half-tone picture is printed on paper with ink.

The finest details of a negative cannot be shown in a half-tone, and, though I have seen many prints that seemed to have fully as much detail as the negative, there is usually at least a slight loss of minute detail even in well made prints.

I have stated, that in order to make a half-tone picture it is necessary first to make a photographic print or picture from the negative, then, from this, to make the half-tone picture. Thanks to the efforts of Dr. Ottolengui and his co-workers, I am able to print a half-tone made directly from the negative. The difference in the appearance of a half-tone made from a negative and one made from a photographic print is shown in Fig. 123 (made directly from the negative) and Fig. 124 (made from the photographic print, but reversed in the process for easier comparison).

Relative Values of Shadows in Prints.

Densities—deep shadows—we have seen appear as transparencies in the negative. The print, or positive, is the opposite of the negative. Hence, in prints, and half-tones made from them, we see the deep shadows of metal fillings, crowns and posts appearing very dark, gutta-percha, cement, enamel and porcelain a little less dark, and so on. On the print, filled canals appear dark, unfilled ones light, abscesses appear as light areas, and so on, always the opposite of the negative.

In order to avoid confusion of the right and left sides when studying a negative, bear the following in mind: When looking at the negative from its film side it is as though you observed the part radiographed from the position occupied by the tube during the exposure. When looking at the negative with the film side presenting towards the light, away from the eye, it is as though you observed the part from the position of the film during exposure. This is the case, granting that the sensitive side of the film presented toward the object radiographed at the time of exposure, a condition that should always obtain except when an intensifying screen is used.

If the technic previously given is followed, and the sensitive side of the film or plate be placed so as to present toward the part to be radio-

Fig. 123. The same as Fig. 124, except that the half-tone was made directly from the glass negative instead of from a photographic print. This radiograph is of a dry skull. (Radiograph by Cryer.)

Fig. 124. The same as Fig. 123, except that the half-tone plate was made from a photographic print, but reversed for easier comparison. (Radiograph by Cryer.)

graphed, and then the negative placed in the printing frame with the sensitive side up (this must be done, or there will be a loss of detail) when observing prints, it is as though one looked at the part from the position of the film or plate during exposure.

When observing half-tones made from photographic prints it is the same as when observing the prints themselves, unless special steps have been taken in the process of making the half-tones to reverse the sides, as was done in Fig. 124. When observing half-tones made from negatives it is the same as observing negatives from the film side.

When looking at radiographs made directly on paper, it is as though you observed the part from the position of the tube during exposure.

Marking Negatives.

How to mark negatives is a subject that has caused the use of a great deal of perfectly good paper and ink. After trying several methods, I no longer attempt to mark my negatives, but place them in envelopes and mark the envelopes as desired. The Lumiere Dry Plate Co. print the following outline on the backs of their envelopes:

No. .....
Name.....
Address .....
Date .....
Case .....
Tube used .....
Exposure .....
Distance of Tube from Plate.....
Developer .....
Referred by Doctor.....
Remarks .....

I have lately heard of an "X-Ray ink" for marking negatives, but have been unable to procure any. The desired markings are placed on the envelopes or black paper covering the plate or film, the marking being done on the side of the envelope or black paper presenting toward the sensitive side of the plate or film, so that when the exposure is made the ink markings are between the source of the rays and the sensitive side of the plate or film. This ink must, I think, contain some salt of lead or bismuth, for the X-Rays penetrate it very poorly, and consequently there is a shadow cast on the negative.

My objection to marking small dental films in this manner is that occasionally the shadow of the markings will occur in such a place in the radiograph as to spoil the picture. The older methods of placing wires bent to form the figures or letters for marking, or a stencil of sheet metal, between the source of rays and the plate, is highly unsatisfactory, so far as their application to the marking of small dental radiographs is con-

cerned. After the negative is made, markings may be scratched in the film. But, as I said before, no system of marking the negative itself is as satisfactory as marking the envelope in which it is kept.

Perspective. One of the most unfortunate limitations of the radiograph is that it lacks perspective. For example, though we are able to observe the exact mesio-distal

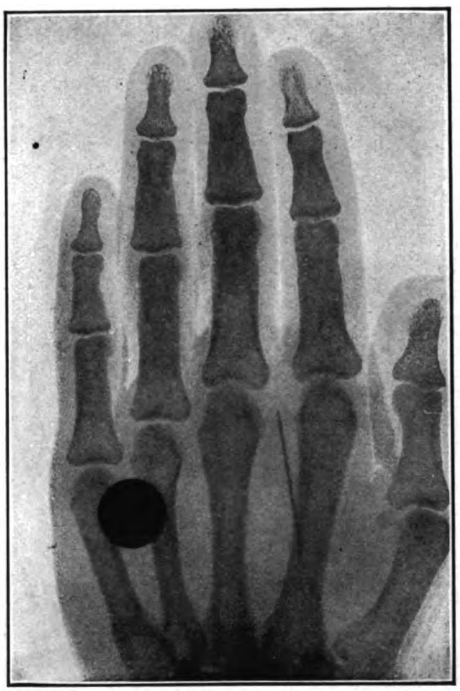

Fig. 125. (Reduced one-half.)

position of an impacted tooth, we are unable to determine its bucco- or labio-lingual position, with any degree of accuracy.

The closer the object, which is being radiographed, is to the film during exposure, the clearer the resulting shadow will be. Thus, for example, if an impacted cuspid lay lingually to the other teeth, and the film were held inside the mouth as usual, the detail in the picture of the cuspid would be a little greater than the detail in the other teeth. If the cuspid lay to the labial,—farther away from the film,—detail in it would be less than in the other teeth. But, on the whole, this method of determining bucco- or labio-lingual location is unreliable.

While I agree with Dr. C. H. Abbot, of Berlin, who has done some writing and experimental work to prove that radiographs are not totally lacking in perspective, yet I do declare, from the standpoint of their practical application to dentistry, that they are simply shadow pictures. And let me here warn you that like all shadows, X-Ray pictures are often extremely misleading; one might say, for the word seems to fit so well, treacherous. To eliminate the chance of misreading, because of distortion of the radiograph, it is often expedient to make several pictures of the same part or field, changing the pose. Even this, however, does not

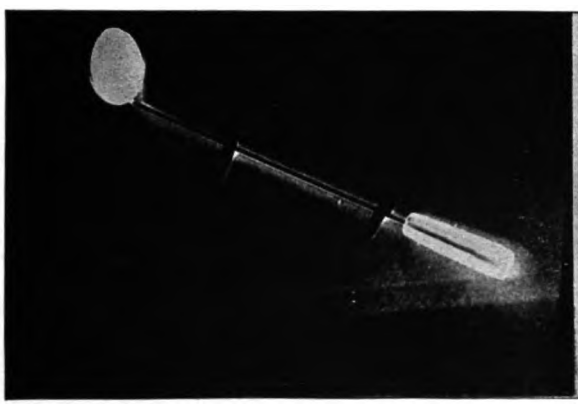

Fig. 126. A dental fluoroscope. Fig. 127. Shadows of teeth cast on the fluoroscope.

preclude the possibility of misinterpretation. To correctly read radiographs, a man must be, not only a student of radiography, anatomy, histology and pathology, but he must have and use that gift of the gods—common sense. He must not jump at conclusions, and he should ever regard the radiograph as a shadow picture, liable to all the apparent misrepresentations of shadows.

A study of Fig. 125 will convince anyone of the lack of perspective in at least some radiographs. One is unable to determine, from observing this radiograph, whether the coin pictured is in the flesh of the hand, on the back of the hand, or in the palm of the hand. Likewise, from simple observation, it is impossible to tell whether the needle is in, on, or under the hand. By deduction, we may come to this conclusion: The coin was nearer the plate, during its exposure, than the needle, because the outline of the coin is much clearer than that of the needle, and other things remaining equal, the closer the object being radiographed is to the plate, the clearer its shadow will be. Still we cannot determine

the exact location of either needle or coin. We know only that the coin was somewhat closer to the plate, during its exposure, than the needle. That is all.

The coin lay under the hand on the envelope holding the plate, the needle on the back of the hand, when the exposure for Fig. 125 was made.

Stereoscopic Radiography.

To overcome the fault of the lack of perspective and, to some extent, the distortion in radiographs, one must resort to stereoscopic radiography.

Stereoscopic radiography is the science and art of making radiographs, which, when observed through a stereoscope, have perspective. The technic of making stereoscopic radiographs, together with a discussion of their value and efficiency, will be dealt with at some length in a subsequent chapter.

Dental Fluoroscope.

A work of this kind would be incomplete without some mention of the dental fluoroscope. The simplest and most efficient dental fluoroscope has been designed by Dr. Tousey (Fig. 126). Like all fluoroscopes, this one depends on calcium tungstate, or platino-barium cyanide, for its action. A disc of cardboard, coated on both sides with either of the above named chemicals, is placed between two discs of transparent glass, and the glasses and cardboard (or fluorescent screen, for the cardboard becomes a fluorescent screen when it is coated with calcium tungstate or platino-barium cyanide) held together by means of a circular band of metal. A handle now, and we have a dental fluoroscope, the screen protected against moisture, and either side of it may be used.

To use the fluoroscope, the operating room should be dark. It is best that the operator remain in this darkened room for some time until his eyes become accustomed to the darkness before making the exposure. Hold the fluoroscope inside of the mouth, and have the tube placed so that the X-rays will pass through the part to be observed, and strike the fluoroscope. Fig. 127 shows the fluoroscope and a shadow of the teeth thrown on it.

The disadvantages of the fluoroscope are:

1. The operator must expose himself to the actions of the X-rays.
2. Either the time for observation must be made very short, or both operator and patient must be exposed to the rays unnecessarily and dangerously long.
3. The picture on the fluoroscope lacks detail.
4. No record of the case, other than a mental picture, can be kept;

while a negative may be referred to as often as expediency or necessity demands.

5. From an educational standpoint, the fact that prints, lantern slides and half-tones can be made from negatives is a great advantage.

To learn to eat olives, one must eat them, so I am told. To learn to read radiographs, one must read them, and so we pass to the next chapter, wherein we shall study, in a practical way, the reading of radiographs.

For further consideration of reading, or interpreting radiographs, see Appendix, Chapter VI.

CHAPTER VII.

The Uses of the Radiograph in Dentistry.

The use of the radiograph in the practice of modern dentistry is almost limitless. Some of the cases hereinafter mentioned are such as the general practitioner of dentistry might not be called upon to diagnose or treat oftener than once or twice in a lifetime, if at all. But by far the greater number of them are such as are met repeatedly in the practice of dentistry.

The radiograph may be used in the following cases: (1) In cases of delayed eruption, to determine the presence or absence of the unerupted teeth. (2) In cases where deciduous teeth are retained long after the time when they should have been shed, to learn if the succedaneous teeth be present. (3) To learn if the roots of children's teeth be fully formed. (4) To determine whether a tooth be one of the primary or secondary set. (5) To determine when to extract temporary teeth. (6) To show the orthodontist when he may move the coming permanent teeth by moving the deciduous teeth. (7) To observe moving teeth. (8) In cases of supernumerary teeth. (9) In cases of impacted teeth as an aid in extraction. (10) To determine the number of canals in some teeth. (11) As an aid in filling the canals of teeth with large apical foramina. (12) To learn if canals are open and enlarged to the apex before filling and to observe the canal filling after the operation. (13) To determine whether an opening leading from a pulp chamber be a canal or a perforation. (14) In cases of pulp stones. (15) In cases of secondary dentine being deposited and pinching the pulp. (16) To learn if the filling in the crown encroaches on the pulp. (17) In cases of teeth with large metal fillings or shell crowns which do not respond to the cold test, to learn if the canals are filled. (18) To learn if apical sensitiveness is due to a large apical foramen or an unremoved, undevitalized remnant of pulp. (19) In cases of chronic pericementitis ("lame tooth"). (20) In cases of alveolar abscess to determine which tooth is responsible for the abscess. (21) In cases of alveolar abscess to determine the extent of the destruction of tissue—bony and tooth. (22) In cases of alveolar abscess to learn how many teeth are involved. (23) In cases of abscess of multi-rooted teeth to learn at the apex of which root the abscess exists. (24) In cases of

abscesses of crowned teeth to learn whether the canals are properly filled. (25) As an aid in differential diagnosis between chronic alveolar abscess and pyorrhea alveolaris. (26) To observe destruction of tissue due to pyorrhea alveolaris. (27) In cases of pericemental abscess. (28) In cases of persistent suppuration which does not yield to the usual treatment. (In fact in all cases that do not yield promptly to the usual course of treatment.) (29) To observe the course of a fistulous tract. (30) To observe the field of operation before and after apicoectomy. (31) To locate foreign bodies, such as a broach in the pulp canal or tissues at the apex of a tooth; a piece of wooden toothpick in the peridental membrane, etc. (32) To determine the presence or absence of a bit of root imbedded in the gum tissue. (33) To diagnose fracture of a root. (34) To observe the size and shape of the roots of teeth to be used in crown and bridgework. (35) As an aid and safeguard when enlarging canals for posts. (36) To examine bridges about which there is an inflammation. (37) To observe the field before constructing a bridge. (38) To observe planted teeth. (39) In cases of cementoma. (40) In cases of bone "whorls." (41) To locate stones (calculi) in the salivary ducts or glands. (42) In cases of bone cysts. (43) In cases of dentigerous cysts. (44) In cases of tumor, benign or malignant. (45) To observe anomalous conditions, such as the fusion of the roots of two teeth for example. (46) To observe the location and extent of a necrotic or carious condition of bone. (47) To diagnose antral empyema. (48) To observe size, shape and location of the antrum as an aid in opening into it. (49) To locate foreign bodies, such as tooth roots or broaches, in the antrum. (50) To observe cases of luxation. (51) In cases of fracture of the jaw before and after reduction. (52) In cases of ankylosis of the temporo-mandibular articulation or the joint formed by the tooth in the jaw. (53) To observe the field of operation before and after resection of the mandible. (54) In all cases of facial neuralgia with an obscure etiology. (55) To observe the inferior dental canal. (56) In cases of Ludwig's angina. (57) In cases of insomnia, neurasthenia, insanity* and kindred nervous disorders. (58) In cases of periodic headaches. (59) In cases of facial gesticulatory tic (spasmodic twitching of a set of the facial muscles). (60) To allay the fears of a hypochondriac. (61) In cases where the patient cannot open the mouth wide enough for an ocular examination. (62) In research work to study osteology, the development of teeth, action of bismuth paste, bone production and destruction, changes occurring in the temporo-mandibular articulation when jumping the bite, blood supply to parts, resorption of

*Dr. Upson—Cleveland.

teeth and the causes for it, etc. (63) As a record of work done. (64) In cases of hidden dental caries.

It is with a mingled feeling of enthusiasm and misgiving that I now attempt to illustrate the above named uses of the radiograph. It is not reasonable to hope that half-tones will show all that can be seen in negatives. As a result, things may be mentioned in the text that cannot be observed in the half-tones; but, be assured, all clinical factors mentioned in the text were observable in the original radiographs.

Thanks to the help rendered by many radiographers, whose names appear beneath the half-tones, and the practitioners, whose names are mentioned in the text, I will be able to illustrate almost all of the above enumerated uses.

In describing cases which have not come under direct personal observation there is, of course, considerable liability to mistakes. I ask my readers to bear this in mind.

It shall be my policy to print as few radiographs as possible to fully demonstrate the different uses. For example, I could print hundreds of different radiographs illustrating the use " in cases of delayed eruption to determine the presence or absence of the unerupted teeth." But only a few will be used, because that is all that is necessary to demonstrate the value of the radiograph in such cases, and to use more would be superfluous in a work of this kind.

1. In Cases of Delayed Eruption to Determine the Presence or Absence of the Unerupted Teeth

Fig. 128

Upper, permanent laterals missing in the mouth of a girl, eighteen years of age. Spaces between the centrals, and the centrals and cuspids. In this case the deformity seemed particularly distressing because, save for the spaces between her teeth, the young lady was positively beautiful.

A radiograph (Fig. 128) was made and shows that the laterals are not impacted in the upper maxilla. It therefore became necessary to move the centrals together and construct a bridge. Had the laterals been present in the maxilla, and space made for them by moving the centrals together, they would probably have erupted into their places. Had they not erupted after space had been made for them the tissues covering them could have been dissected away, holes drilled into the teeth, little hooks cemented into these holes and the teeth elevated orthodontically.

When there seems to be a congenital absence of
Fig. 129. a tooth from the jaw it is expedient—which is expressing it mildly—to use the radiograph before constructing and setting a bridge. Failure to do this might result in what

Fig. 128. Congenital absence of the upper lateral incisors. Age of patient, eighteen years.

Fig. 129.

Fig. 130.

Fig. 129. Bridge from central to first bicuspid. Unerupted cuspid. The arrow points to a bit of tooth root. (Radiograph by Ream of Chicago.)

Fig. 130. An upper cuspid in the place of the lateral. A temporary cuspid in the place which should be occupied by permanent cuspid. The lateral missing from the jaw.

is shown in Fig. 129—an unerupted cuspid covered with a bridge. Such a condition as this may or may not cause local inflammation, neuralgia, or any of a series of inflammatory and nerve disorders. In this case the bridge covers not only an unerupted cuspid, but also a bit of tooth root.

In a case presented to me an upper permanent
Fig. 130. cuspid was seen occupying the place of the lateral incisor, and a temporary cuspid was in the space

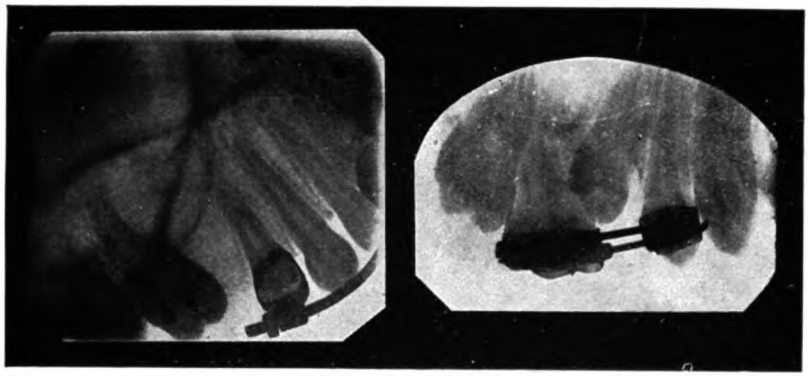

Fig. 131. Fig. 132.

Fig. 131. Congenital absence of the upper second bicuspid. Observe the orthodontia appliance in position. (Radiograph by Lewis of Chicago.)

Fig. 132. Delayed eruption of an upper second bicuspid. The orthodontia appliance in position is being used to make space in the arch for the delayed tooth. (Radiograph by Lewis of Chicago.)

Fig. 133. A badly impacted lower second bicuspid, with no space at all for it in the dental arch. (Radiograph by Pancoast of Philadelphia.)

which should have been occupied by the permanent cuspid. A radiograph was made (Fig. 130) to locate the missing lateral. It was not present in the jaw. Though I am not absolutely sure of this, I nevertheless feel quite certain that the permanent lateral was mistaken for a temporary tooth and extracted when the patient was about seven or eight years old—a mistake which could not have happened had the dentist used radiographs.

Figs. 131 and 132. Fig. 131 proves the absence of a second bicuspid and shows that bridgework must be resorted to, to fill the space. Fig. 132 discloses the presence of a second bicuspid and shows that it will not be necessary to make a bridge. As they appeared before radiographs were taken the cases, from which Figs. 131 and 132 were made, were similar.

Fig. 133. Fig. 133, a case of Dr. Cryer's, shows a badly impacted lower second bicuspid with no space at all for it in the dental arch.

Fig. 134. With the exception of the third molars no teeth are so liable to be delayed in their eruption as the upper cuspids. For this reason, when making a radiograph to determine the presence or absence of an unerupted upper cuspid or an upper or lower third molar, I feel tolerably sure, before I make the picture, that the tooth will be found somewhere in the jaw. When the missing tooth is a central, lateral, bicuspid, or lower cuspid, I am in doubt as to what to expect. My experience teaches me that when these teeth are missing they are just as likely to be entirely absent from the jaw as present in it, and simply unerupted. So far, I have never seen either long delayed eruption or congenital absence of the first or second molars.*

*Since the first publication of the above, Dr. Ottolengui has reported two interesting cases (ITEMS OF INTEREST, February 19, 1913), from which record I quote in part, as follows:

Missing First Molar

"Very shortly after Dr. Raper had published the foregoing statement, that up to that time he had not seen a case wherein first or second molars were congenitally absent, a little girl patient of mine came in for her periodical examination, and I noted that since her previous visit she had erupted three first permanent molars, but the fourth had not appeared. I immediately began to wonder whether or not I was about to discover an authentic case of congenital absence of a first molar. I say authentic, because in records of this

kind it is not always that one may be sure that the history is authentic. But in this particular case there can be no doubt. The child was the sister of another girl in my care and had been under my observation since she was four years of age. I have casts of her mouth at the age of five, which show the primary denture complete. I may add also that there never had nor has been any caries, and consequently there was no possibility that a molar had been extracted, a suspicion always warranted when we find a first molar absent from the mouth of an adult. An ordinary small mouth radiograph was made, and while it did not disclose the shadow of a molar, neither did it satisfactorily show what really existed. I therefore determined to have a large radiograph made, so that we might have a picture of the entire bone.

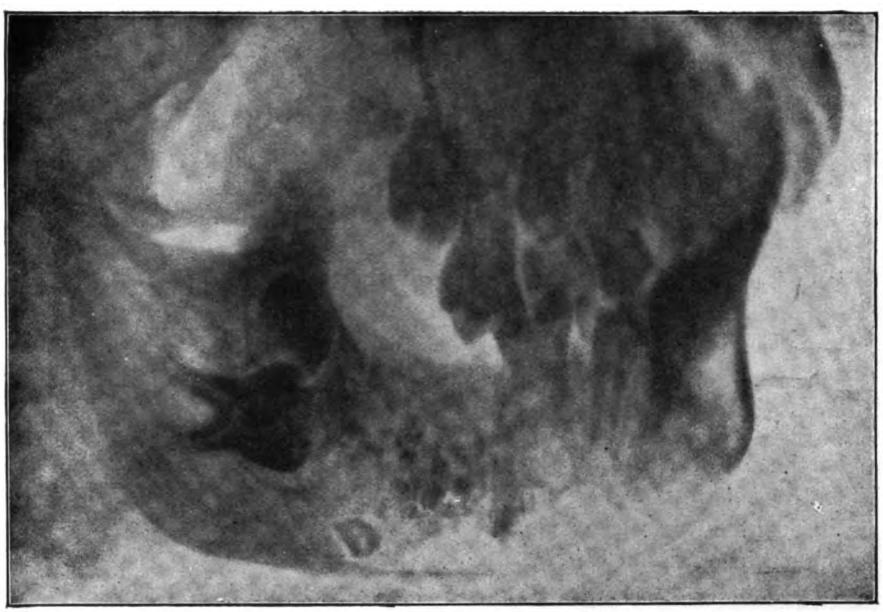

Fig. A.

Odontoma in region which should normally be occupied by lower first molar. Patient 8 years old. Malposed lower second molar. (Radiograph by Schamberg, of New York City.)

"The patient was sent to Dr. M. I. Schamberg, who made radiographs of both sides of the mandible, that we might compare them. The radiographs are reproduced in Figs. A and B. My surprise may be imagined when I found that in the region which should have been occupied by the second bicuspid and the first molar, there was a well-defined composite odontoma. And perhaps even more astonishing is the position of the molar lying distally of the tumor. Whether this tooth, which is seen lying horizontally in the bone, is the first molar or the second molar, is a question that has been raised by an orthodontist of national reputation, a man of

keen judgment and well informed as to tooth forms. While I am willing to admit that this looks more like a first than a second molar, especially when we compare with the normal side (Fig. B), still I very much doubt that it is the first molar. The odontoma is more apt to be a composite of the bicuspid and first molar. But in any event, interesting as this case is, it cannot be entered in the literature as a record of congenital absence of a first permanent molar, because that tooth is either in the bone or else is included in the odontoma, whereas by "congenital absence" I understand to be meant complete non-existence.

Fig. B.

Same patient as for Fig. A, opposite side, conditions normal. (Radiograph by Schamberg, of New York City.)

Missing Second Molars.

"The second case which I am permitted to report is from the practice of Dr. Thaddeus P. Hyat, and is in the hands also of Dr. George B. Palmer for orthodontic treatment. The patient is a boy of fourteen, and we are assured that no permanent teeth have been extracted, yet no less than thirteen permanent teeth are missing. In the upper jaw the absent teeth are: both lateral incisors, three bicuspids, both second molars and both third molars, a total of nine teeth (note that both upper laterals are absent, while both upper cuspids are present). In the lower jaw the following teeth are absent: the first bicuspid and the third molar on the right side and the second bicuspid and the third molar on the left side.

"Figs. C and D are radiographs of the two sides of the head. In the upper the first molars are easily distinguished, but there are no evidences of the second and third molars. In the mandible the third molars are absent, but the other four molars are present, though in one case the crown has been lost by caries. Considering the boy's age, this seems to be an authentic record of congenital absence of two second upper molars, and of all four third molars, as the extraction of any of these teeth could not have been forgotten.

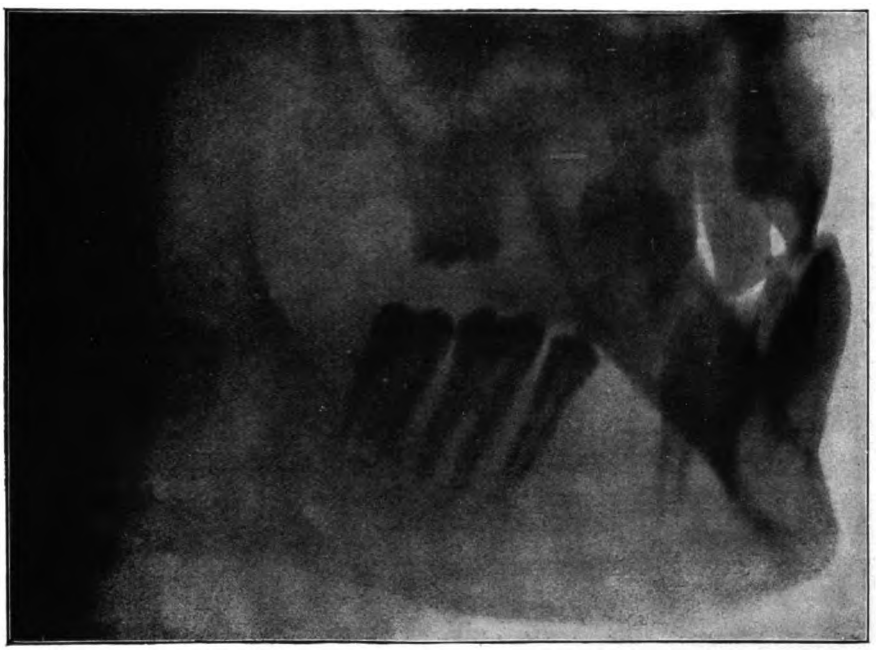

Fig. C.

Patient's age 13. Right side. Missing teeth: Upper bicuspids, second and third molars. Lower first bicuspid and third molar.

Missing First, Second and Third Molars.

"Dr. Hyat has kindly asked another patient of his to call at my office that I might examine a very similar case. In this instance the patient is a woman about thirty-five years of age. She is a highly cultured person engaged in the editorial department of one of our leading magazines. She is quite positive that the only tooth she ever had extracted was one lower first molar. If this be true she has fourteen teeth congenitally absent as follows: In the upper jaw the missing teeth are the two lateral incisors, the first, second and third molars on the left side, and the second and third molars on the right side. In the lower jaw the missing teeth are the second bicuspid and all three

Fig. 134 is representative of a class of delayed eruption that is most common. I could print hundreds of radiographs of such cases. Fig. 123 was a beautiful example. The age of the patient in this particular case (Fig. 134) was some months over fourteen. The radiograph was made for an orthodontist who was just beginning treatment of the case. There was no evidence of the presence of the cuspid and no room for it to erupt. When the arch was broadened and space made for it the

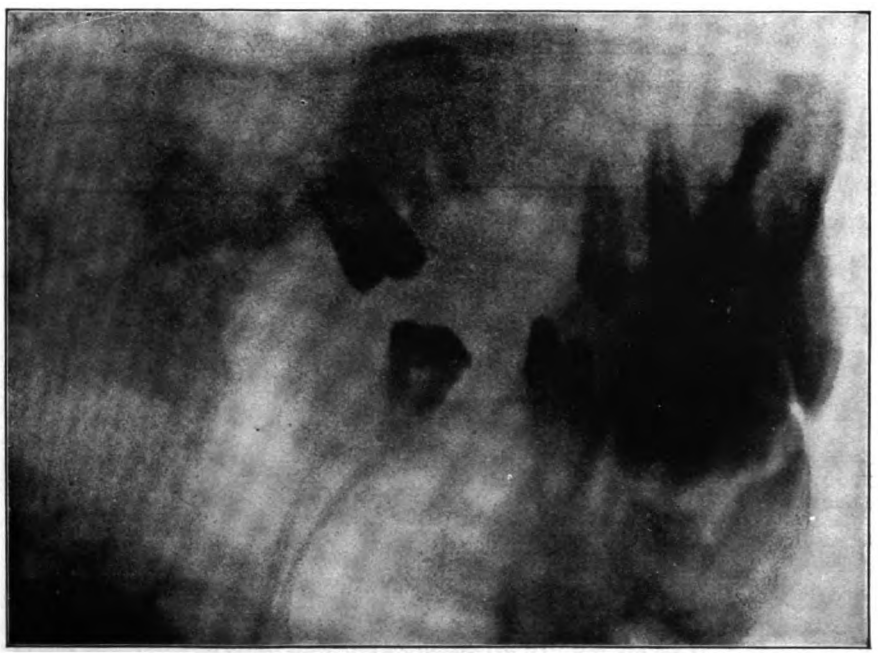

Fig. D.

Same patient as for Fig. C, left side. Missing teeth: Upper second bicuspid, second and third molars. Lower second bicuspid and third molar. The roots only of the lower first molar remain.

cuspid erupted. It required some mechanical guidance to make it come into its exactly proper position.

---

molars on the right side, and both bicuspids and the third molar on the left side Again we have the upper laterals missing, and the upper cuspids present.

"In this mouth we have the strange anomaly of three molars missing from the upper jaw on the right side, and three molars missing from the lower jaw on the left side. Enumerated in full the absent molars were all four of the third molars, three of the second molars and two of the first molars."

The mere making of space for them in the arch will usually result in the eruption of unerupted teeth, unless they are malposed. If, after space is made, the tooth does not move, the gum and process over it should be slit surgically. If this does not suffice to induce eruption, the soft parts and process must be cut away, and sometimes it may be necessary to resort to the use of orthodontia appliances to assist eruption, as formerly suggested.

In handling cases of unerupted teeth it should constantly be borne

Fig. 134. Age of patient, fourteen. An unerupted malposed cuspid. No room for it in the dental arch. Observe the tipping of the lateral, which is probably due to the pressure of the cuspid against the apex of its root.

in mind that it is an almost invariable rule that unerupted teeth move only in the direction in which they point; *i. e.*, "In a line with their long axis." Thus an unerupted tooth must be headed right, or pointed right, to induce it to erupt.

When radiographing cases of delayed eruption we may expect to find (1) the tooth present in the jaw—Fig. 134; (2) the tooth missing from the jaw—Fig. 131; (3) an odontoma in the place of the tooth—Fig. A; (4) an odontoma or supernumerary tooth preventing eruption —Figs. 263 and 264.

2. In Cases Where Deciduous Teeth are Retained Long After the Time When They Should Have Been Shed, to Learn if the Succedaneous Teeth be Present.

Fig. 135. Case—Girl, age seventeen, large cavity in upper, second, deciduous molar. Whether to fill this tooth or extract it depended on whether there was a second bicuspid to take its place in case of extraction. It was not at all loosened and there was no visible evidence of the presence of the suc-

Fig. 135.

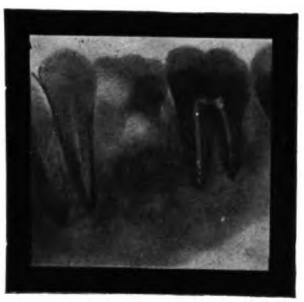

Fig. 136.

Fig. 135. Age of patient, seventeen. Retained upper, second, temporary molar. The radiograph shows that the second bicuspid is present in the jaw.

Fig. 136. Age of patient, twenty-one. Retained lower, second, temporary molar with a large cavity in the crown of the tooth and the roots almost entirely resorbed, despite the fact that there is no oncoming second bicuspid.

ceeding bicuspid. Fig. 135, however, shows the bicuspid to be present. The half-tone may not do so, but the negative now before me has perspective enough for me to see that the bicuspid is being deflected toward the lingual. The deciduous tooth was extracted and the bicuspid erupted promptly.

Fig. 136. Case—young man, age twenty-one, lower, second, deciduous molar with pulp exposed. Question: Should the tooth be treated, filled and retained in the mouth, or extracted to make room for the second bicuspid? Fig. 136 demonstrates the futility of attempting to treat the tooth—its roots are almost entirely resorbed despite the fact that there is no succedaneous tooth in the jaw—and shows also that there is no bicuspid to take its place. Extraction and bridgework are indicated.

Fig. 137. Fig. 137 shows two retained temporary upper cuspids with the permanent cuspids impacted and malposed.

Fig. 138 shows two retained, primary, lower central incisors with no sign of the permanent centrals. Age of patient, seventeen.

Fig. 138.

Case—a young man, age twenty-two; with a retained, temporary, lower, second molar. The temporary tooth was too short to reach its antagonists in occlusion. For this reason the patient, a dental student, wished to have it crowned. Before making the crown, a radiograph was taken (Fig.

Figs. 139 and 140.

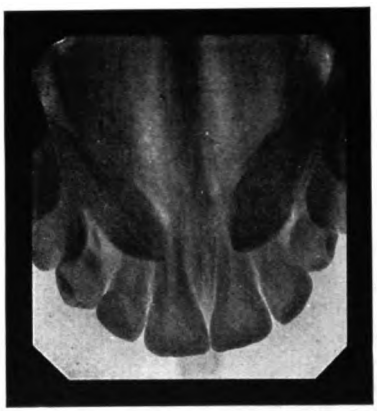

Fig. 137.

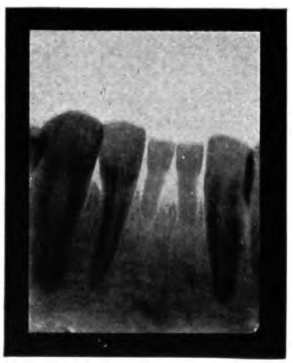

Fig. 138.

Fig. 137. Two retained temporary cuspids, with the permanent cuspids impacted and malposed. (Radiograph by Lewis, of Chicago.)

Fig. 138. Two retained temporary, lower, central incisors. No permanent centrals present. Age of patient, seventeen. (Radiograph by Blum, of New York City.)

139) after the development of which it was seen that the making of a crown was not indicated. From the appearance of the radiograph one might suppose that the temporary tooth was loose—its roots being almost entirely resorbed. But such was not the case.

Fig. 140 is a radiograph of the same case one month after the extraction of the temporary molar. Notice how rapidly the bicuspid is erupting into its place. The force of eruption, which had been held in abeyance for about eleven years, became promptly active upon removal of the abating object.

Case—young man, age twenty-one. A retained, temporary, upper cuspid with no observable sign of the succedaneous cuspid. A radiograph was made (Fig. 141), but, being a poor one, it failed to show the looked-for tooth. Yet from the reading of this radiograph I was able to state with a moderate degree of certainty that the cuspid was present in the jaw. If the

Figs. 141 and 142.

tooth itself cannot be seen, what is there in the picture to lead one to believe that the permanent cuspid is present? The arrow points to the upper end of a dark line. The dark line represents dense bone and such a line almost always is to be noted in radiographs of impacted teeth.

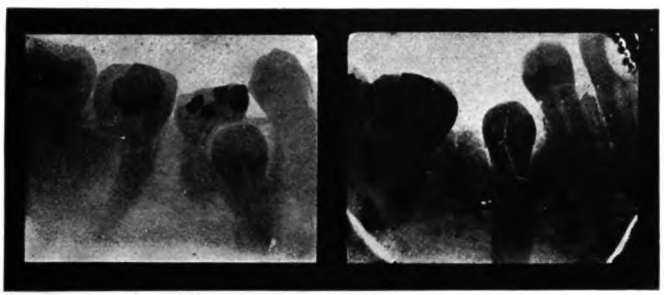

Fig. 139. **Fig. 140.**

Fig. 139. Retained temporary, lower, second molar, with the succedaneous tooth beneath it. Age of patient, twenty-two. The dark spots in the temporary tooth and two permanent molars are metal fillings. All of the mesial root and some of the distal root of the temporary tooth resorbed.

Fig. 140. The same as Fig. 139 one month after extraction of the temporary tooth. Observe how rapidly the bicuspid is erupting. When this picture was made it could be seen in the mouth.

Fig. 141.

Fig. 142.

Fig. 141. Age of patient, twenty-one. A retained temporary upper cuspid. The arrow points to a dark line following along the side of the impacted cuspid. The impacted tooth itself cannot be seen.

Fig. 142. The same as Fig. 141, but taken at a different angle and showing the permanent cuspid.

To verify or disprove my deductions another radiograph was made (Fig. 142), which shows the impacted cuspid clearly.

The question arises naturally, What operative procedure should be

resorted to in such cases as the one just described? Had the patient been younger, or had the root of the temporary cuspid been much resorbed, or had the pressure of the impacted tooth been causing resorption of the permanent lateral root, or central root, or had the patient been suffering from neuralgia, periodic headaches, or any nervous disorder—had any of these conditions existed the temporary tooth should have been extracted immediately, space made in the arch for the permanent tooth and such orthodontic assistance given as might prove necessary to cause it (the permanent cuspid) to erupt into its proper place. As none of

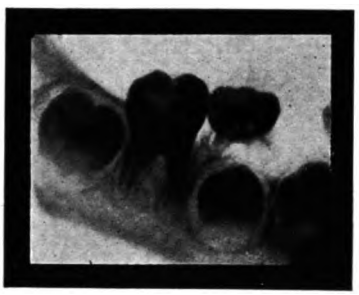

Fig. 143. The roots of a lower, first, permanent molar not quite fully formed. Age of patient, eight years and four months. Only the crowns of the second bicuspid and second molar are formed.

these conditions did exist, and as the patient expressed a definite disinclination to have anything done unless absolutely and imperatively necessary, the case was dismissed with the understanding that the condition should be kept under rigid observation. The man may go through life without trouble, or inside of a year he may be suffering almost any nervous disorder from simple neuralgia to insanity*; or he may lose the temporary cuspid as a result of the resorption of its roots, or he may even lose the lateral or central as a result of absorption of their roots, or suppuration may occur.

3. To Learn if the Roots of Children's Teeth are Fully Formed.

Case—patient, eight years and four months old.

Fig. 143. A large cavity in a lower first, permanent molar. To remove absolutely all of the decalcified dentin meant extensive exposure of the pulp, and, therefore, pulp devitalization, extirpation and canal filling. But should we practice pulp devitalization in such a case? If the roots of the tooth are fully formed, yes;

*Dr. Upson.

if the roots are not fully formed, no. A radiograph (Fig. 143) was made and shows that the roots of the tooth are not quite fully formed. Accordingly exposure of the pulp was avoided, the unremoved, decalcified dentin painted with silver nitrate, a paste of zinc oxide and oil of cloves placed in the bottom of the cavity and the tooth filled with cement, the object of this treatment being to conserve the pulp in the tooth at least until the roots are fully formed.

Often a child meets with some accident which breaks off the angle of a central or lateral incisor. To restore the angle sometimes necessi-

Fig. 144. Post-collar crown on a temporary cuspid root. The permanent cuspid erupted down to the post of the crown. The dark shadows in the region of the temporary cuspid crown are numbers used to mark the negative. (Radiograph by Kells, of New Orleans.)

tates the removal of the pulp and the placing of a post in the canal. The question should always be raised, "is the tooth's root fully formed?" If it is, we may proceed with the devitalization, but if not, some temporary restoration should be made and the pulp conserved until it has fulfilled its function of root development. Whether the root is fully formed or not can be determined only by the use of the X-rays.

In a child's mouth we occasionally find an anterior tooth so badly decayed that crowning is indicated. Again we are confronted with the question, "is the root fully formed?" And whether we should devitalize and crown the tooth or keep it patched with cement for a year or so depends entirely upon the answer which the radiograph may make to this question.

4. To Determine Whether a Tooth be One of the Primary or Secondary Set.

What treatment we give a tooth depends very largely on whether it be of the permanent or deciduous set. If a man knows his dental anatomy as well as he should it is usually easy for him to determine whether a tooth be a primary or secondary one. Occasionally, however, we find a tooth (usually an upper lateral incisor) that looks as

much like a member of one set as the other and the radiograph must be used to arrive at a definite conclusion. To mistake a permanent tooth for a deciduous one and extract it (Fig. 130) is an inexcusable and disastrous blunder.

Sometimes a tooth is so badly decayed (the crown may be entirely destroyed) that it is impossible to determine by simple ocular observation whether it be a temporary or a permanent one. The radiograph can be used to great advantage in such cases. If the carious tooth be one of the temporary set, with the succedaneous tooth ready to take its place, it should be extracted. If the carious tooth be a permanent one, the radiograph shows the size and condition of its roots.

Case—a post-collar cuspid crown became loose.

Fig. 144. A radiograph (Fig. 144) was made and shows that the crown is placed on a temporary cuspid root. Part of the root of the temporary tooth is resorbed and the permanent cuspid has erupted down to the end of the post of the crown. The very dark shadows in the region of the temporary cuspid crown are caused by lead numbers placed against the film packet to mark the negative.

8. To Determine When to Extract Temporary Teeth.

Fig. 145. The best rule ever formulated for the extraction of deciduous teeth reads, "Extract a deciduous tooth only when its successor is ready to take its place." There are many cases where the operator is able to detect the presence of the succedaneous teeth by ocular and digital examination. In about as many cases, however, the only way to determine the presence of such teeth is by the use of the radiograph. Thus the rule just quoted is one which, when followed, necessitates the use of the radiograph. Fig. 145 is of a case where extraction of the temporary first molar is indicated, and extraction of the temporary second molar is contraindicated. The temporary second molar should not be removed for a year or so—not until the second bicuspid is just ready to take its place.

Often in practice we are confronted with abscessed temporary teeth. The age of the patient is such that we cannot decide whether the teeth are loose as a result of the abscessed condition, or because of resorption of the roots and the presence of the succedaneous teeth. A radiograph of the case will enable us to decide, and our treatment will be governed accordingly. Not only will the radiograph show the operator when deciduous teeth should be removed, but will aid him in their removal—especially in cases where the temporary teeth are badly decayed—by showing the exact size and location of the temporary teeth's roots and the position of the succedaneous teeth.

6. To Show the Orthodontist When He May Move the Coming Permanent Teeth by Moving the Deciduous Teeth.

It impressed me very much when I first heard of radiographically observing, and then regulating, teeth before their eruption. I heard of this in a lecture by Dr. Ottolengui. I quote Dr. Ottolengui:

Fig. 146.

"One of the difficult operations which confronts the orthodontist at times is the bodily movement of the bicuspids buccally. Very often in the past at-

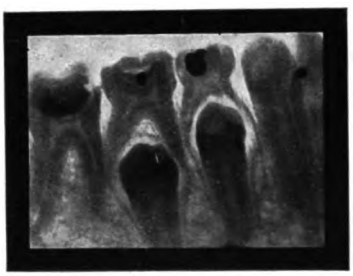

Fig. 145. This picture shows that the temporary first molar may be extracted. The temporary second molar should not be extracted for a year or so, when the second bicuspid will be just ready to take its place. (Radiograph by Lewis, of Chicago.)

tempts to widen the arch, after the eruption of the bicuspids, has resulted in tipping the crowns buccally, the apices of roots remaining in the original apical arch. Hence, one of the chief advantages of early orthodontic interference lies in the fact that the temporary molars may be moved buccally, carrying with them the underlying bicuspids, and this advantage is made more clear if it be recalled that at this period the bicuspid roots are but partly formed. Even when the roots of the temporary molars are already considerably absorbed, still enough may be left to serve to deflect the oncoming bicuspids in the direction desired.

"This slide (Fig. 146), from the collection of Dr. Matthew Cryer (radiograph by Pancoast, of Philadelphia), shows nicely the usual relation of the erupting bicuspids to their predecessors, the temporary molars. It will be noted that the apices of the bicuspids are still unformed, and it is clear that if these teeth can be led into proper positions during eruption, the formation of the apices afterward affords the most permanent 'retention.' A casual glance at the upper temporary molars might create a doubt as to the probability of moving the unerupted bicuspids, but there is an easily overlooked factor, viz., the palatal roots of these molars do

not show in radiographs of this region at this period, because they lie behind the crowns of the bicuspids; that is to say 'behind,' in relation to the source of light, the X-ray tube."

Fig. 146. Radiograph made to show relation of temporary molar roots to advancing bicuspids. (Collection of Dr. Cryer. Radiograph by Pancoast, of Philadelphia.)

7. To Observe Moving Teeth.

Figs. 147, 148 and 149.

Fig. 147 demonstrates the congenital absence of the upper lateral incisors. The orthodontic appliance, seen in the radiograph, is being used to draw the centrals together. It was highly important in this case that the teeth be

moved through the alveolar process *en masse,* and not tipped. The movement desired was one which would make the roots parallel when the crowns of the teeth came together, so that posts could be set in the canals of the central incisors, and a bridge made to restore the lost laterals. Fig. 148 was taken about a month after Fig. 147. It shows that the teeth have been moved together, but there is too much tipping of the

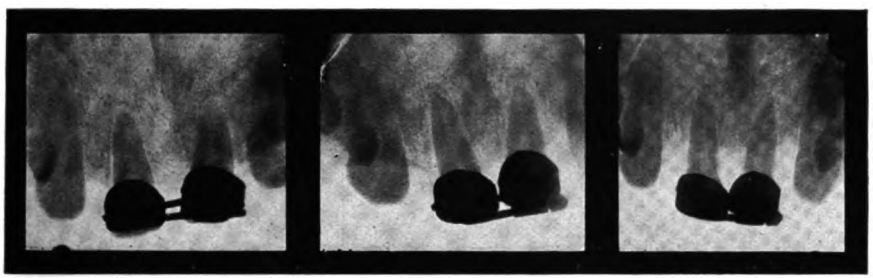

Fig. 147. Fig. 148. Fig. 149.

Fig. 147. Congenital absence of upper lateral incisors. The orthodontic appliance seen is being used to draw the central incisors together.

Fig. 148. This radiograph was made one month after Fig. 147. It will be seen that there has been considerable movement of the teeth. The left central is tipped considerably.

Fig. 149. Made one month after Fig. 148. The central incisors are together and their roots almost parallel.

left incisor—not enough movement of the tooth at the apex of the root, compared to the movement of the crown. It, therefore, became necessary to modify the force which was being used. This was done, and Fig. 149 shows the teeth together and the roots almost parallel.

Figs. 150, 151 and 152. A case in the practice of Dr. C. Edmund Kells, Jr., and reported by him in the May number of ITEMS OF INTEREST, 1911. Fig. 150 shows a malposed permanent cuspid above the temporary cuspid, the root of which is somewhat resorbed. Age of patient, eleven years. Fig. 151 was made one year and seven months after Fig. 150. "Compare this picture with Fig. 150, and it will be seen that the permanent cuspid has migrated in a line with its long axis," causing resorption of the permanent lateral root. The temporary cuspid was extracted, but the permanent tooth did not erupt into its position in the arch. It was, therefore, concluded that the tooth "would have to be brought down by some mechanical means." Accordingly, the gum tissue and overlying process were "slit down to the cuspid and then gently spread apart, and the

cuspid was exposed to view. A piece of iridio-platinum wire was then shaped, as shown in Fig. 152, and the hook was worked supposedly under the mesial prominence of the cuspid, and a rubber ring attached to the loop on the other end, and secured to a lug on the molar band, all as shown in Fig. 152, which is a skiagraph of the case with the appliance

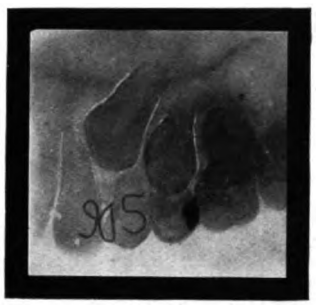

Fig. 150.

Fig. 151.

Fig. 150. Malposed, permanent cuspid above the temporary cuspid, the root of the latter somewhat resorbed.

Fig. 151. Same as Fig. 150 one year and seven months later. Observe that the cuspid has migrated in the line of its long axis. The permanent lateral root is badly resorbed.

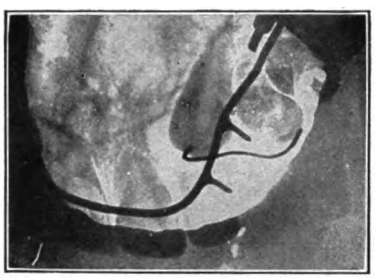

Fig. 152. Same as Figs. 150 and 151 after removal of the temporary cuspid. The wire hooked over the cusp of the tooth was thought to be placed over the mesial prominence until the radiograph was made. (See Fig. 459.)

in position. Imagine my surprise to find by this picture that the hook was not anywhere near where I had thought I put it. Instead of being well up under the mesial prominence, it was merely caught under the point of the tooth, and, of course, it slipped off shortly after the patient left the office. Upon her return a hook ⅜ of an inch longer was fitted in place, and this time, with a radiograph as a guide, there was no mistake about its placement. The appliance was worn for several weeks, at

the end of which time the point of the cuspid having been brought to the surface of the gum, it was removed and the tooth allowed to erupt by its own volition. Despite the great destruction of its root the lateral remains firm and apparently healthy."

8. In Cases of Supernumerary Teeth.

Fig. 153. A case in the practice of Dr. B. S. Partridge, Chicago. Patient's age, twelve years. The teeth were being regulated, and the radiograph, Fig. 153,

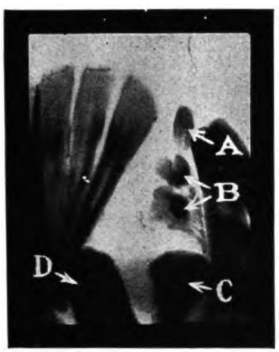

Fig. 153.

Fig. 154.

Fig. 153. A and B, supernumerary tooth bodies. C, the crown of the temporary cuspid. D, the permanent cuspid. (Radiograph by Lewis, of Chicago.)

Fig. 154. A and B are supernumerary teeth. (Radiograph by Lewis, of Chicago.)

was taken to determine the presence or absence of the permanent lower cuspid. A little supernumerary tooth (A) could be seen in the mouth occupying a part of the space which should have been occupied by the permanent cuspid. The two shadows marked "B" are two more supernumerary tooth bodies. The larger shadow marked "C" is the crown of the temporary cuspid, which had never erupted. The large shadow to the left, marked "D," is the permanent cuspid pressing against the side of the lateral at the apex of its root. The three supernumerary bodies and the crown of the temporary cuspid (the root was resorbed) were removed, allowing the permanent cuspid to erupt.

Fig. 154. Just lingually to each central incisor is a supernumerary tooth. One (A) could be seen in the mouth, but there was no evidence of the other. Neither central nor lateral incisor roots are as yet fully formed, and the

laterals have not yet erupted. Indeed, before the picture was made, it seemed that a peg-shaped lateral was erupting just lingually to the central. The radiograph shows this tooth to be supernumerary.

Dr. T. W. Brophy, of Chicago, reports a case of insistent suppuration due to an impacted supernumerary tooth, which was found by the use of the radiograph. Dr. Brophy calls attention to the fact that a correct and definite diagnosis could not have been made by any means at our command except the X-rays. The case recovered promptly upon removal of the supernumerary tooth. I regret that I have been unable to obtain radiographs of this case.

Fig. 155. An impacted upper fourth molar.

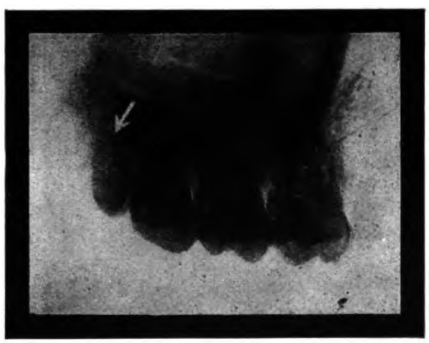

Fig. 155.

Fig. 156.

Fig. 155. An impacted upper fourth molar.
Fig. 156. A supernumerary tooth in the canal of a cuspid tooth. (Radiograph by Clarence Van Woert, of New York City.)

Fig. 156. To me this is a most remarkable case—a supernumerary tooth in the canal of a cuspid tooth—a tooth inside of a tooth. The supernumerary tooth has a root canal, and the crown is covered with enamel. There is no doubt of the fact stated, because Dr. Van Woert, after radiographing the case, drilled into the permanent cuspid and found the enamel-covered supernumerary within. The radiograph is not as good as I wish it were. The upper two-thirds of the roots of the teeth shows fairly well but there is a confusion of shadows in the lower third and in the crown.

9. In Cases of Impacted Teeth as an Aid in Extraction.

Fig. 157. Impacted, lower, third molar tipped to the mesial. The picture shows that in this case a knife-edge stone in the dental engine could be used to advantage, cutting away the mesio-occlusal portion of the third molar, and

so greatly facilitating the removal of the tooth. Observe the absorption of the distal surface of the second molar (the light area), due to pressure against it; and the large abscessed cavity (light area) between the second and third molars, extending down to the apex of the second molar. This radiograph is of particular interest, because it shows so clearly an abscess caused by impaction.

Figs. 158 and 159. That the pressure of an impacted tooth may cause absorption of the tooth against which the pressure is brought to bear, is further illustrated in Figs. 158 and 159.



Fig. 157.

Fig. 158.

Fig. 157. An impacted lower third molar. The light area between the second and third molars represents a destruction of bony tissue, arrow A. Arrow B points to a light area, which represents the absorption of the second molar. (Radiograph by Blum, of New York City.)

Fig. 158. An impacted upper third molar. The arrow points to a light area representing absorption of the upper second molar. Notice the very poor filling in the first molar; it fills the interproximal space between the first and second molars. (Radiograph by Ream, of Chicago.)

In Fig. 158 the arrow points to a light area representing absorption of the upper second molar, due to the pressure of the third molar against it. A study of this radiograph gives the dental surgeon a good idea of how he should apply his force in extraction.

Fig. 159 is a case of Dr. Cryer's. I quote Dr. Cryer: Fig. 159 "shows an impacted, lower, third molar resting against the posterior root of the second molar. It will be seen that the root of the second molar is much absorbed, which caused considerable trouble. Removal of the second molar gave relief to the patient. . . . The upper third molar is in an awkward position."

Figs. 160 and 161. Figs. 160 and 161 show impacted upper third molars. The unerupted teeth lie in the jaws at entirely different angles. The value of such knowledge to the operator, about to extract, is apparent.

Fig. 162. This radiograph (Fig. 162) shows the surgeon just how much bone must be dissected away before the malposed tooth can be removed. Patients seldom

know that the removal of a tooth is not always a simple operation. They are therefore inclined to blame the operator if the tooth is not quickly removed, instead of crediting him with working dexterously on a difficult operation. They are likewise unwilling to pay a fee in proportion to the

Fig. 159. Impacted upper and lower third molar. Absorption of the distal root of the lower second molar. (Radiograph by Pancoast, of Philadelphia.)

difficulty of the operation, as compared to other operations. The removal of the third molar, shown in Fig. 162, is a more difficult operation than the removal of a vermiform appendix. By showing patients radiographs of such cases the dentist will gain their earnest, intelligent co-operation. They will know just what is done for them, and for the first time in their

lives they will understand that the extraction of a tooth may be a serious, difficult and expensive operation.

The following report of this case is by Dr. F. K. Ream, of Chicago. "Patient's age, seventy-two years. Symptoms: Swelling near symphysis thought to be the result of wearing an artificial denture. Considerable pain. Diagnosed

Fig. 163.

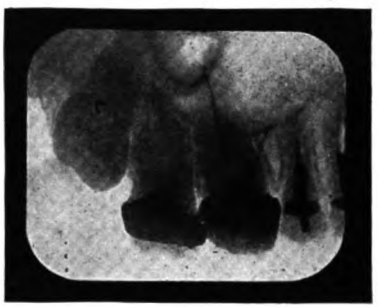

Fig. 160. Fig. 161.

Fig. 160. Impacted upper third molar.

Fig. 161. Impacted upper third molar. Notice the difference in the position of the impacted tooth shown in this case and in Fig. 160.

Fig. 162. Fig. 163.

Fig. 162. Impacted lower third molar with its occlusal surface presenting mesially. The radiograph shows the dental surgeon how much bone must be burred or chiseled away before the tooth can be removed. (Radiograph by Ream, of Chicago.)

Fig. 163. Impacted bicuspid in an otherwise edentulous mouth. Age of patient, 72 years. (Radiograph by Ream, of Chicago.)

cancerous by surgeons, and patient advised to go to the hospital for operation. The radiograph (Fig. 163) shows an impacted bicuspid in the otherwise edentulous jaw. Operation: Alveolar process burred away and tooth removed. Result: Immediate and complete recovery."

Fig. 164. Fig. 164 is a case of Dr. Cryer's. I quote Dr. Cryer: Fig. 164 "shows a lower third molar passing under the second molar and becoming lodged between the first and second molar, the crown of the third molar pushing against the root of the first molar. The first molar was extracted, which cleared up the neuralgia, and the third molar pushed up into the place of the first molar."

Fig. 164. Lower third molar lodged between the first and second molars. (Radiograph by Pancoast, of Philadelphia.)

Fig. 165. Fig. 165 is also a case of Dr. Cryer's. The radiograph shows an impacted upper third molar, with the occlusal surface presenting upwards. Dr. Cryer's remarks concerning this case are interesting. I quote Dr. Cryer: Fig. 165 "shows the occluding surface of the upper third molar pointing upward towards the posterior portion of the orbit. The patient had been suffering from disturbance of the eye for a long time. Considerable improvement took place in the eye soon after extraction of the inverted tooth."

10. To Determine the Number of Canals in Some Teeth.

It will be noticed that I say "to determine the number of canals in *some* teeth." Of course, it is not necessary to use the radiograph each

time we open into a tooth to learn how many canals that tooth may have. But occasionally I do find it necessary or expedient to use the radiograph to verify or disprove the existence of some unusual condition suspected.

Fig. 165. Impacted upper third molar with the occlusal surface pointing upward. (Radiograph by Pancoast, of Philadelphia.)

Fig. 166.

Case: An upper first (?) molar in which but one small canal could be found. After searching for the other two canals for a few minutes, the one canal was filled with gutta-percha, and a radiograph made (Fig. 166); this shows that the tooth has but one canal. In this case the radiograph saved considerable work and worry on the part of the operator. The tooth is probably a second molar moved forward in the place of an extracted first molar, judging from the manner in which it is tipped and from the fact that it has only one canal.

Fig. 167.

This case was in the hands of one of the most expert operators in Indianapolis. The lower first bicuspid had been devitalized, and the pulp removed,

but the tooth remained sore. Radiography was resorted to to learn, if possible, the cause of the persistent pericementitis. A piece of ligature wire, such as is used by orthodontists, was placed in the canal and radiograph Fig. 167 made. The wire follows the enlarged canal. But this particular tooth happens to have two canals. The unopened canal is seen to the distal of the wire. If a man, having the skill of the operator who handled this case, misses a canal, as this man did, then I firmly believe that the mistake is one that any man, however skillful, is liable to make.

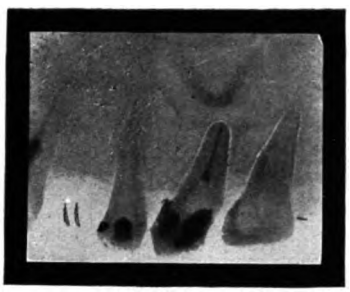

Fig. 166.

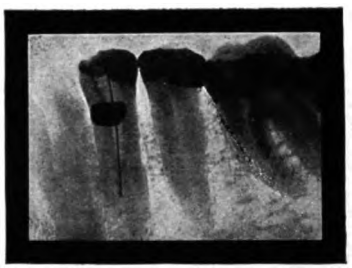

Fig. 167.

Fig. 166. Upper first (?) molar with but one canal which is filled.
Fig. 167. The dark streak in the first bicuspid is a wire passing into the canal. This tooth has another canal, which can be seen as a light streak distally to the wire. The more or less oval dark spot at the neck of the first bicuspid is a buccal cervical filling. The cavity in the crown of the tooth is stopped up with gutta-percha.

Let me say here that a lower bicuspid, or cuspid with two canals, is not such an unusual occurrence, as it is generally believed to be. Men have shown me such teeth, and spoken of them as though they were rare anomalies. As a teacher of operative technic, I devote a part of my time to the dissection of teeth. In this work I handle thousands of disassociated human teeth. In my work of last year, for example, I estimate that I observed six to eight thousand teeth. And among these I noticed not less than seven lower cuspids and five lower bicuspids with two canals each.

Without printing the radiograph, which is not a very good one, I quote the legend which appears beneath it in the last edition of Buckley's "Modern Dental Materia Medica, Pharmacology and Therapeutics." "In this case the author desires to insert a bridge. On opening into the third molar and second bicuspid, which teeth were to be used for the abutments, we were unable to find any canals in the bicuspid, and only a small canal in the molar. The skiagraph confirms the clinical findings."

II. As an Aid in Filling the Canals of Teeth with Large Apical Foramina.

Fig. 168. To demonstrate this use of the radiograph a central incisor with a large apical foramen was chosen, and an orthodontic ligature wire passed into the canal until the patient received sensation. The worthlessness of the "sensation test," as a guide in filling to the apex of canals is demonstrated by Fig. 168, which shows the wire penetrating the tissues four or five millimeters beyond the apex of the tooth. After the radiograph (Fig. 168) was made, the wire was removed, and that part of it penetrating the apex cut off, or as nearly as could be judged from the appearance of the radiograph.

Fig. 168.

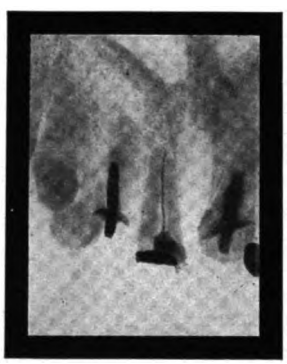

Fig. 169.

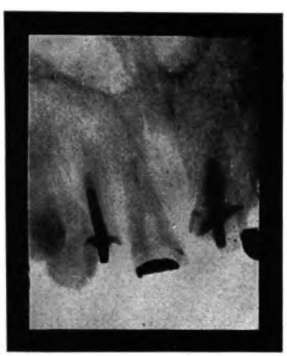

Fig. 170.

Fig. 168. A wire passing through a large apical foramen in an upper, central incisor, extending several millimeters into the tissues above the apex of the root.

Fig. 169. The same case as Fig. 168, after the wire has been removed, a part of it cut off and reinserted into the canal. The wire reaches just to the apical foramen.

Fig. 170. The same case as Figs. 168 and 169, showing a canal filling of gutta-percha closing the apical foramen, not penetrating through it, and not leaving a little of the canal unfilled at the apex of the root. The entire canal is not filled, because there is to be a post set in it.

Fig. 169. Next the shortened wire was reinserted and another radiograph (Fig. 169) made. This shows that my judgment in cutting off the wire in this particular case was unusually good. The wire reaches just to the apex. It may be necessary to make two or three trials before the wire is placed just to the apex.

Fig. 170. With the length of the wire as a guide to the length of the root, the proper distance was measured on a canal plugger, and the distance marked on the plugger by passing it through a little piece of base-plate gutta-percha, stopping the gutta-percha on the plugger at a distance from its end equivalent to the length of the wire. The end of the canal plugger was then

warmed slightly, and brought in contact with a small piece of gutta-percha canal point. With the piece of gutta-percha so fastened on the canal plugger, it was carried into the canal a sufficient distance to reach, but not pass, beyond the apex. (Fig. 170.) A slight twist of the plugger will disengage it from the gutta-percha, when the latter may be tamped firmly, but not too forcibly, to place. No further filling of the canal was done in this case, the canal being left open to receive a post.

What will happen if the canal filling either fails to reach the apex or passes a little beyond it? An abscess may result. If the canal filling fails to reach the apical foramen, in such cases as the one just described, an abscess is very likely to occur. If perfectly aseptic gutta-percha is used as a

Fig. 171

Fig. 172

Fig. 171. The dark streaks in the lower molar are wires in the canals. (Operator, Dr. Moag, Indianapolis.) Fig. 172. The same as Fig. 171 after canal filling.

canal filling, and the tissues above the apex are not infected, then the passage of a little gutta-percha into the apical tissues will probably not result in suppuration or even inflammation, so well do tissues tolerate gutta-percha. But the fact remains: *The ideal canal filling is one which fills the canals, neither falling short of the end of the root nor passing beyond it.* (For further consideration see Appendix Chap. XI.)

12. To Learn if Canals Are Open and Enlarged to the Apex Before Filling, and to Observe the Canal Filling After the Operation.

A radiograph of the tooth before attempting to open its canals will often be found of great value to the operator. This is particularly true in cases where the shape or size of the roots is unusual.

At any time during the process of opening canals the operator may insert wires and make a radiograph to see how far he has penetrated.

Fig. 171 is the first radiograph made of the particular case it illustrates, and shows the wires (in this case old broaches) reaching the ends of the canals.

A wire with a flat end does not enter canals readily. Engage the wire—orthodontia ligature wire for example—in the broach holder, for the dental engine suggested by Dr. Gallie, hold the end of the wire with emery cloth between the thumb and finger, and revolve the engine. In this way the wire may be pointed and reduced to any desired size.

It is not always a physical possibility to reach the ends of the canals in molar teeth. It is very often necessary to devote from five to ten hours on a molar to open its canals to the end.

Fig. 173. Canals in an upper first molar well filled. (Operator, Dr. Emmert, Indianapolis.)

Fig. 174. Wire passing to the mesial through a perforation in the mesial side of the mesio-buccal root of an upper first molar.

Even after the canals are open to the end, the fact having been demonstrated with diagnostic wires and radiographs, it is not at all uncommon for the operator to fail to fill the canals the first time he tries.

Dr. M. L. Rhein, of New York City, was, as far as I am able to learn, the first man to make routine use of the radiograph in pulp canal work.

The advantages in using the radiograph in this connection are as follows: Much guesswork is eliminated—we know what we are doing. If the canal is tortuous, and we start through the side of the root, the radiograph shows us the mistake, keeps us from making a perforation, and, in many cases, enables us to follow the canal to the true apex. If the root is unusually short the radiograph keeps us from going through the apex, and if it is unusually long it keeps us from making the error of not penetrating the canal far enough. The radiograph shows patients just what is being done for them.

Fig. 175. The arrow points to a pulp stone in the pulp chamber of an upper second molar. The blacks and whites in this half-tone are as they appear in the negative, the pulp stone a light area more or less surrounded by dark.

Fig. 176.

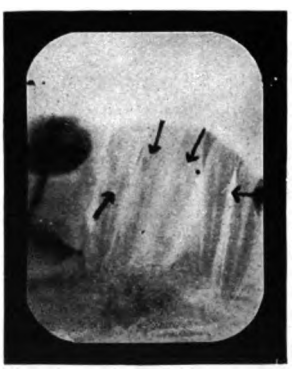

Fig. 177.

Fig. 176. The arrow points to a small pulp stone in the pulp chamber of a lower first molar.
Fig. 177. Pulp stones throughout the canals in the lower central incisors. Also small stones in the lateral incisors.

Having observed quite a large number of radiographs in the last few years, allow me to state that many, altogether too many in our profession, fail to enlarge and fill to their apices all canals which really could, and should, be so treated. There are, perhaps, some cases where the buccal canals of upper molars and the mesial canals of lower molars simply cannot be enlarged to their apices. But this fact is no excuse for enlarging and filling only the upper third of such canals. The stock excuse for poor canal work is "our patients will not pay a fee sufficiently large to enable us to give the necessary time to the work." But do those who thus excuse themselves really give their patients any choice in the matter? If one should show a patient a radiograph demonstrating the fact that he had only penetrated the canals about one-third their length, then explain why he should go farther, and why it would take time to do so, would the patient say, "Oh! let 'er go," or would he or she say, "I want done whatever is best?"

It is difficult to radiograph the buccal roots of upper molars, particularly second and third molars.

13. To Determine Whether an Opening Leading from a Pulp Chamber Be a Canal or a Perforation.

When one opens the tooth himself, and does not use a small, round bur on the floor of the pulp chamber, he may feel certain that any opening found must be a canal. But in cases where the pulp chamber has been opened by another operator, it is often impossible to decide whether an opening leading from the pulp chamber be the mouth of a canal or a perforation through the tooth. Likewise in cases where decay has attacked the walls and floors of the pulp chamber, almost destroying them, it is sometimes difficult to differentiate between a canal and a perforation. Pass a wire through the opening and make a radiograph.

Fig. 174. A wire passing to the mesial through a perforation in the upper first molar.

14. In Cases of Pulp Stones (Nodules).

There has been a great deal of dispute as to whether or not pulp stones can be shown radiographically. The right answer is in the affirmative

Fig. 175. The appearance of the pulp stone in the upper second molar is typical. Though it can be seen clearly in the print now before me I can only hope that it will appear in the halftone.

Fig. 176. Case one of neuralgia. The radiograph shows a pulp stone in the lower first molar at the mouth of the mesial canal.

Experience in the practice of radiodontia has taught me that there are many more pulp stones in teeth than I had thought. Indeed I find myself wondering, after observing great numbers of them which are not causing pain, if pulp stones ever cause pain. And then I see a case of neuralgia, or earache, in which the radiograph reveals the presence of a pulp stone which is removed on suspicion and lo! the patient gets well.

Fig. 178

Fig. 179

Fig. 178. The arrow points to what might be mistaken for a pulp nodule. The shadow is, however, a filling on the buccal at the cervical.
Fig. 179. Simple occlusal filling in the molar, encroaching on the pulp.

Considering the common occurrence of pulp stones it is certainly unwise to remove them whenever found. On the other hand it is sometimes imperative that they be removed in cases of obscure neuralgias and neuritises.

Fig. 177. Intermittent, intense pain in region of chin extending backward to temporo-mandibular articulation. In this case the pulp stones had caused death of the pulp in the two central incisors. Efforts to remove the stones from these teeth met with failure and the teeth were extracted. The pulp stones in the lateral incisors were removed. Result: A cure.

Fig. 178. In this radiograph the arrow points to a shadow which was mistaken for a pulp stone. The shadow is, however, not a pulp stone, it is a small filling on the buccal surface at the cervical.

Fig. 178 is indistinct, not because the detail of the original negative has been lost in the process of making the half-tone, as frequently occurs, but in this case because the original negative was not well made. It was made many years ago when the art of radiodontia was so young we scarcely had an idea of what constituted a good radiograph. It is, to put it mildly, an unnecessary risk to make a diagnosis from a radiograph as lacking in detail as Fig. 178.

15. In Cases of Secondary Dentin Being Deposited and Pinching the Pulp

This use was recently suggested in a dental magazine by Dr. Cryer. Such a condition as the one referred to might exist and be responsible for neuralgia or other nerve disorders. Likewise it could probably be ob-

served radiographically. At the present time, however, I am unable to show a radiograph of such a case.

16. To Learn if the Filling in the Crown of a Tooth Encroaches on the Pulp.

Fig. 179

Case: Neuralgic pains in the lower left side of face. Thought to be due to a necrotic condition of the bone in the region of the lower first molar, which had recently been extracted. A radiograph (Fig. 179) shows the bone healthy. The simple occlusal filling in the second molar penetrates into the pulp chamber. This filling was removed, and the semi-vital pulp devitalized, removed, and the canals filled. The result was an immediate and complete recovery.

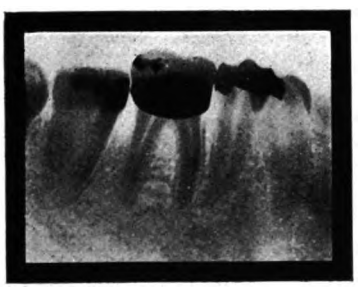

Fig. 180

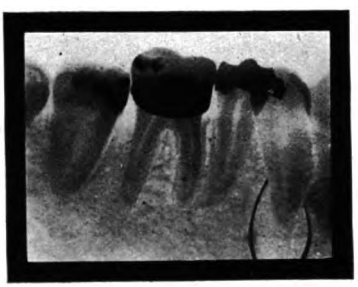

Fig. 181

Fig. 180. The first bicuspid seems to hold a disto-occlusal filling. This appearance is due to a slight irregularity—a slight lapping of the teeth. The filling which appears to be in the distal of the first bicuspid is in the mesial of the second bicuspid. The simple occlusal filling in the first bicuspid encroaches into the pulp chamber slightly.

Fig. 181. The same as Fig. 180 with the diseased area at the apex of the first bicuspid outlined, to enable the reader to see it better in Fig. 180.

17. In Cases of Teeth with Large Metal Fillings or Shell Crowns Which Do Not Respond to the Cold Test, to Learn if the Canals Are Filled.

Figs. 180 and 181

Case: Slight swelling and pain in the lower bicuspid and first molar region. The patient stated that this condition had occurred and recurred many times in the past five years. At no time had the swelling been great, and the pain was never severe. The slight swelling and an annoying pain would last for a few days, then disappear for a month or so. There was no discharging sinus. The first molar bore a gold shell crown, the second bicuspid held a large mesio-occluso-distal amalgam filling, and the first bicuspid had a small filling of amalgam in the occlusal surface. The three teeth—the first molar and the two bicuspids—were isolated one at a

time and tested with cold water. The patient was uncertain as to whether he received any sensation when the cold was applied to the shell-crowned molar, but thought that he did. The second bicuspid responded well, and the first bicuspid did not respond at all. This seemed to indicate a vital pulp in the molar and second bicuspid, and a devitalized one in the first bicuspid. But, when looking for a dead pulp, one would naturally suspect either the molar with the shell crown, or the second bicuspid with the large filling, instead of the first bicuspid with the small occlusal filling.

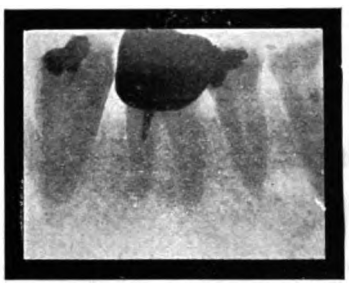

Fig. 182. The roots of the shell crowned first molar are not properly filled. Only the upper third of the distal canal is filled and the mesial canals are not filled at all. The tooth was sore and caused annoying neuralgic pains.

The temperature test is a valuable one, but it cannot be depended upon absolutely. A radiograph (Fig. 180) was made. It shows the canals of the molar and second bicuspid unfilled. The tissues at the apices of the roots of these teeth are healthy, which, together with the positive reaction to the cold tests indicates that their pulps are vital and healthy. The simple occlusal filling in the first bicuspid enters the pulp chamber slightly, the canals of the tooth are unfilled, and the light area at the apex of the root indicates disease (inflammation) of the bone in that region. These things, together with the fact that the tooth did not react to the cold test, indicate a putrescent pulp in the first bicuspid. The tooth was opened, and the diagnosis confirmed.

Fig. 182.

In practice, case after case presents, the patient complaining of a slight soreness or annoying pain in the region of a shell-crowned tooth, or a tooth with a large metal filling in it. The tooth fails to respond to the cold test, and we suspect that the canals are poorly filled, or perhaps not filled at all. Are we justified in removing the crown or filling to examine the canals? Before the radiograph came into use we were, but not to-day. It is not fair to your patient nor yourself to remove a canal filling unless you can improve on the operation. Fig. 182 is a radiograph of a case of the

class just alluded to. The canal filling in the shell crowned lower, first molar is so imperfect, it should not be difficult to improve the operation. Let me give a word of warning, however: Goodness knows it is hard enough to open canals to the end when you are the one who opens the tooth for the first time, but, when there has been a previous unsuccessful effort at canal filling, your difficulties may be multiplied a hundred-fold. Make no promise of success. Note the slight cervical bone destruction between first and second molars, due to poorly contoured, poorly fitting shell crown.

Fig. 183

Fig. 184

Fig. 183. Wire just penetrating the apical foramen. Showing that the apical sensitiveness is not due to an unremoved, undevitalized remnant of pulpal tissue.

Fig. 184. The wire in the canal of the lateral fails to reach the apex, proving that the apical sensitiveness is due to an unremoved, undevitalized remnant of pulpal tissue.

18. To Learn if Apical Sensitiveness Is Due to a Large Apical Foramen or an Unremoved, Undevitalized Remnant of Pulp.

Figs. 183 and 184.

In the treatment of teeth we often pass the broach into the canal until we reach what we know must be the neighborhood of the apex, when pain is produced. It is often difficult to decide whether this pain is due to some remaining vital pulp tissue in the canal, or the penetration of the broach through the apex. Fig. 183 is from such a case. The wire passing to the point of sensitiveness goes through the apical foramen, and so proves that the sensitiveness is not due to unremoved, undevitalized pulp tissue. In Fig. 184 the wire reaching the point of sensitiveness fails to reach the apex, proving that the sensitiveness is caused by an unremoved, undevitalized remnant of pulp.

Let us stop to consider how this question of whether or not we are penetrating the apex is decided when radiographs are not used. We pump phenol or some other obtundent into the canal, working our broach farther

and farther until we strike the end of the canal ending in a blind alley, or go so far into the apical tissues we know that no tooth root could be as long as the distance we are penetrating. The use of the radiograph saves all this guesswork, obviates the necessity of causing considerable pain and is a time-saver.

19. In Cases of Chronic Pericementitis (Lame Tooth).

A putrescent pulp is the most common cause for pericementitis, either chronic or acute. Therefore, when the affected tooth is crowned or filled, as it almost always is in chronic pericementitis, radiographs should be

Fig. 185

Fig. 186

Fig. 185. Gutta-percha canal filling in the upper lateral passing through the side of the root to the distal. The canal filling also penetrates the apical foramen. The light area to the mesial along the apical third of the root indicates an abscess. The mesial surface of the root is roughened in the region of the abscess. (Radiograph by Lewis of Chicago.)

Fig. 186. Canal filling penetrating the tissues between the roots of the lower first molar. (Radiograph by Kells, Jr. of New Orleans.)

made to learn whether the canals are properly filled, and treatment may be rendered accordingly. Fillings and crowns without contact points, or fillings with bad gingival margins, or crowns which do not fit well at the cervix or penetrate beneath the gum margin into the peridental membrane, are sometimes the causative factors in chronic pericementitis. These things may be detected usually without the aid of the radiograph. Often, however, a radiograph will demonstrate the fault in a very convincing manner.

Figs. 185 and 186.

Figs. 185 and 186 demonstrate lesions that might be responsible for chronic pericementitis, which could not be detected by any means other than the use of the radiograph.

Fig. 187. The arrows point to a small abscess (the light area) at the apex of a lower central incisor. None of the lower anterior teeth have cavities in them.

Fig. 188

Fig. 189

Fig. 188. Evidence of bone change at apex and downward along distal side of cuspid—the tooth with the post in the otherwise unfilled canal. Piece of root in first bicuspid region. Suspicious spot in apical region of second bicuspid.

Fig. 189. Abscess of central incisor with considerable bone destruction in apical region of missing approximating lateral incisor.

20. In Cases of Alveolar Abscess to Determine Which Tooth is Responsible for the Abscess.

Fig. 187.

Case: A pus sinus opening on the labial between the lower central incisors near their apices. All of the lower anterior teeth sound and apparently

healthy. Fig. 187 shows which tooth is responsible for the abscess. This tooth was treated and the abscess cured. The light area to which the arrow points, about the apex of the central, represents the abscess cavity. Acute abscesses cannot always be shown in radiographs, because there may not be sufficient destruction of bony tissue. Chronic abscesses, which have become acute, can, of course, be shown radiographically.

Take for example such a common case in the practice of dentistry as a bridge with a fistula pointing above a dummy. One does not know before a raidiographic examination is made whether there is a piece

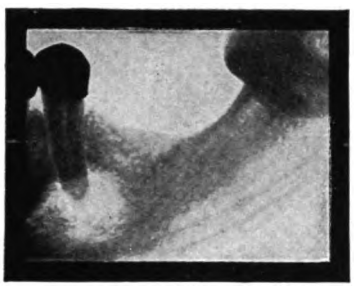

Fig. 190. Abscess at apex of lower second bicuspid. The tooth carries a gold shell crown. Canal is not filled. The inferior dental canal can be seen plainly in this radiograph—light streak between two dark lines along the lower border of the mandible.

of tooth root above the dummy, whether one abutment tooth is abscessed or the other, or, for that matter, whether or not all of these things exist. Thus one does not know how to treat the case at all and must depend upon raidiographic examination before any intelligent action can be taken.

Fig. 188. Case: Fistula pointing above upper first bicuspid dummy. The radiograph shows a piece of the root of the first bicuspid, an abscess area at the apical and to distal of the cuspid, and a suspicious area in the apical region of the second bicuspid.

Treatment indicated: Removal of bridge. Removal of piece of tooth root. Treatment of cuspid: Testing of second bicuspid for vitality.

Fig. 189. Case: Fistula pointing above lateral dummy. The radiograph shows a rarified area above the dummy communicating with the crowned central incisor. The cuspid is not involved in the abscess; it has a vital pulp. The missing lateral was probably abscessed. Its extraction did not eradicate the pus sinus at its apex because the central fed infection to this sinus.

Treatment: Disinfection and filling of canal of central. Curettement of pus sinus.

Fig. 190. Fistula just in front of lower third molar. The third molar free of carious cavities. I suspected a piece of unremoved root of the missing second molar to be responsible for the suppuration. A radiograph (Fig.

190) was made. It demonstrates the absence of any piece of tooth root, and shows a large abscess at the apex of the shell-crowned second bicuspid. The bicuspid was opened and an antiseptic solution forced through the tooth and out through the fistulous opening in front of the third molar.

The radiograph does not show the fistulous tract leading from the bicuspid backward toward the third molar. The probable reason for this is that the tract passes along between the bone and periosteum. Therefore, there is very little destruction of bony tissue throughout its course.

Recently the following case presented: Fistulous opening on the labial over the apex of a perfectly sound upper cuspid. The first bicuspid apparently healthy save for a small, faulty, amalgam filling. The proximating lateral shell crowned. I suspected the crowned lateral to be the seat of the trouble. A radiograph was made, and showed, to my surprise, that the lateral was perfectly healthy and its canal well filled. A radiograph of the first bicuspid was made and showed an abscess and unfilled canals. I do not print radiographs of this case, because one of them, the one showing the abscess, has been mislaid. I record the case because it is one the like of which a person may run across any day in practice.

21. In Cases of Alveolar Abscess to Determine the Extent of the Destruction of Tissue—Bony and Tooth

Fig. 191. Case: Shell-crowned, lower first molar. Chronic abscess of several years' standing. The crown was removed, and the tooth treated. The flow of pus stopped. The canals were filled and the crown reset. In about a month there was a recurrence of pus production. A radiograph (Fig. 191) was made, and shows both roots, especially the mesial, badly absorbed. The canal fillings penetrate into the area of diseased bone. I advised extraction. A most peculiar fact in this case is the great destruction of tooth structure, and the comparatively slight destruction of the alveolar bone; the reverse of what is usually found. Not only is there little destruction of bone, but bony tissue seems actually to have filled in the space formerly occupied by the tooth roots.

Fig. 192. One of the most perfectly circumscribed alveolar abscesses I have ever seen. The abscess occurs at the apices of the roots of the upper first bicuspid. Notice how the two roots extend into the abscess cavity. The very light shade of bone to the distal of the bicuspid is diseased, somewhat carious, but will regain normal vitality in all probability when thorough drainage

of the abscess is obtained. A case like this should yield to treatment without extraction. Root resection is indicated.

Fig. 193. A very large abscess involving the upper central and lateral incisors of one side. I am unable to learn what treatment was given in this case. Basing my judgment on the appearance of the radiograph, without any clinical knowl-

Fig. 191

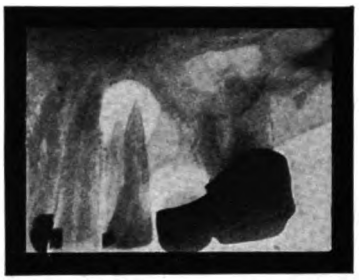

Fig. 192

Fig. 191. Both roots of the shell-crowned, lower, first molar badly absorbed, especially the mesial. Canal fillings extend beyond the ends of the roots.
Fig. 192. An almost perfectly circumscribed abscess about the roots of an upper first bicuspid. Note how the roots extend into the abscess cavity. (Radiograph by Blum, of New York City.)

edge of the case, I would say that the lateral should be extracted, and the opening so made into the abscess cavity enlarged to the distal to such an extent as to permit a thorough curettement of the suppurating sinus. (This would necessitate removal of the bridge from first bicuspid to cuspid.) Or, perhaps an opening sufficiently large to permit thorough curettement and drainage could be made through the external alveolar plate and the lateral conserved. At any rate, knowing that the opening into a pus sinus to drain and curette it thoroughly must vary directly according to the size of the sinus, we can see that, in this case, the opening must be quite large. Such an abscess could not be drained sufficiently well through pulp canals.

Fig. 194. Fig. 194 shows how utterly futile it would be to attempt to treat, and retain in the mouth, such a tooth as is shown in the radiograph. Such a condition could not have been diagnosed by means other than the use of the X-rays. The small, dark streak through the tooth is a wire. Note the great destruction of the tooth root and the carious condition of the surrounding bone.

Fig. 195. Case: Sinus opening near the apex of an upper central incisor. The tooth did not yield to treatment. It was treated on the assumption that there was con-

siderable destruction of bone, and powerful stimulating corrosives, like phenolsulphonic acid, were forced beyond the apex. That such treatment was improper is demonstrated by the radiograph (Fig. 195), which shows that there is very little bone destruction. Accordingly the more radical line of treatment was dropped, the sinus injected with bismuth subnitrate paste, a mild antiseptic sealed in the canal, and the tooth allowed to rest unmolested for ten days, at the end of which time all pathological symptoms had disappeared.

Fig. 193

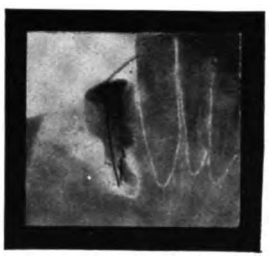

Fig. 194

Fig. 195

Fig. 193. Very large abscess involving the lateral and central, and extending almost to the apex of the first bicuspid. (Radiograph by Peabody, of South Orange, N. J.)

Fig. 194. Absorption of the root and surrounding bony tissue. A wire is seen passing into the canal. (Radiograph by Blum, of New York City.)

Fig. 195. A *very small* abscess cavity at the apex of the central with the wire in it.

22. In Cases of Alveolar Abscess to Learn How Many Teeth are Involved.

Fig. 196.

I recall having treated an abscessed central incisor for a month without effecting a cure, or even much improvement. The apical foramen was well opened, and antiseptic and stimulant washes could easily be forced through the tooth and out through the fistulous opening on the gum, assuring me that I had good drainage. The lateral at the side of the central did not respond to the cold test, but neither did any other tooth in the patient's mouth. Despite the fact that it was a sound tooth, I opened into the lateral, removed the pulp, which, while devitalized, was not badly putrescent, enlarged the apical foramen, and found that washes forced into the lateral came out both the fistula and central. While the case is not the same, the conditions which I then combated in the dark (I did not use the X-rays in my practice at this time), are shown in Fig. 196. An abscess, involving both central and lateral, is shown by the light area

about and above their apices. In this case the canal of the central is only partially filled, and the lateral canal not filled at all.

Fig. 197. An abscess pointing in the palate. A radiograph (Fig. 197) was made to determine which tooth was responsible. The central, lateral, cuspid and first bicuspid were suspected. The radiograph shows that all of these teeth

Fig. 196

Fig. 197

Fig. 196. Abscess involving the central and lateral incisors. The canal of the central is partially filled. (Radiograph by Lewis, of Chicago.)

Fig. 197. A large abscess involving the central, lateral and cuspid.

except the first bicuspid—*i.e.*, the central, lateral and cuspid—are involved. The abscess was treated through all three teeth, but did not yield to this treatment. It was deemed necessary to curette the sinus. An opening through which the sinus could be curetted was made by extracting the lateral root. Perhaps there are those who will condemn my surgery, saying the tooth should have been conserved and the opening made into the sinus through the external alveolar plate.

The foregoing was written five years ago. It is unlikely that I would be criticised to-day for extracting the lateral, though I might be criticised for not removing all three teeth or at least for not removing the ends of the roots of the teeth not extracted.

23. In Cases of Abscess of Multirooted Teeth, to Learn at the Apex of Which Root the Abscess Exists.

Fig. 198. This radiograph shows an abscess at the apex of the mesial root of a shell-crowned, lower first molar. The canals of the tooth are not filled.

There is so much definite evidence of extensive infection about the mesial root that its removal is indicated; the distal root can be con-

served. Perhaps disinfection of the area about the mesial root could be accomplished by ionization. The ionization method of disinfection is comparatively untried but it seems to the writer to hold great possibilities.

Fig. 198

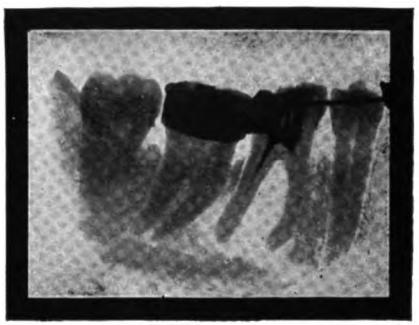

Fig. 199

Fig. 198. Abscess at the apex of the mesial root of the shell-crowned, lower, first molar. The canals of the tooth are not filled. (Radiograph by Blum, of New York City.)

Fig. 199. Large abscess involving both roots of the lower first molar and probably both roots of the second molar. The distal canal of the first molar is partially filled. (Radiograph by Ream, of Chicago.)

Fig. 199. A large abscess involving both roots of the lower first molar and probably both roots of the second molar. Without a history of the case to guide me, I should say, judging from the appearance of the radiograph, the first molar should be extracted and diagnostic exploration of the second molar should be made to learn whether or not its pulp is vital.

24. In Cases of Abscess of Crowned Teeth to Learn if the Canals are Properly Filled.

It is a common occurrence in practice to have a patient present with a pus sinus, discharging in the region of the apex of a tooth carrying a crown. If the canals of the tooth are properly filled, we should treat the sinus through the external alveolar plate; if the canals are not properly filled, then the crown should be removed and the case treated through the tooth—perhaps through the external alveolar plate also, depending on the extent of the destruction of tissue. Whether or not the crown should be removed is determined by the use of the radiograph.

Fig. 200.

In the third edition of his *Modern Dental Materia Medica, Pharmacology and Therapeutics,* Dr. Buckley prints Fig. 200, and the following description: Fig. 200 "shows the involvement of the upper central and lateral

Fig. 200

Fig. 201

Fig. 200. Abscess involving the upper central and lateral incisors. There was but one fistulous opening on the labial. Since the canals of central and lateral are both properly filled the treatment should consist simply of curettement of the affected area, which, of course, does not necessitate the removal of the post-porcelain crowns from the teeth. (Radiograph by Ream, of Chicago.)

Fig. 201. Dr. Rhein says of Fig. 201: "This is a typical case of chronic alveolar abscess, which for years had been erroneously treated for pyorrhea."

Fig. 202. Alveolar abscess wrongly diagnosed as pyorrhea. (Radiograph by Rhein, of New York.)

incisors in an abscess. Both teeth carried perfectly adjusted porcelain crowns. The skiagraph not only shows the involvement of both teeth, but also that the roots are properly filled. The treatment here is purely surgical, and means the curettement of the affected area." Had the radiograph not been used the operator would, in all probability, have made the laborious and foolish mistake of removing the crowns on the assumption that the canals were not properly filled.

25. As an Aid in Differential Diagnosis Between Chronic Alveolar Abscess and Pyorrhea Alveolaris.

When a chronic alveolar abscess discharges about the neck of a tooth the case so closely simulates calcic pyorrhea alveolaris that, without using the radiograph or opening into the affected tooth, the operator cannot make a definite diagnosis.

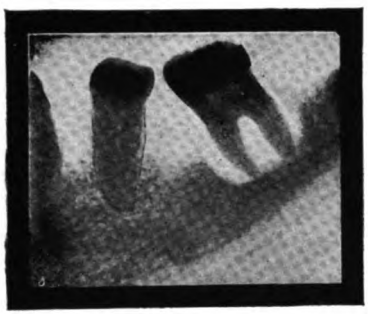

Fig. 203

Fig. 204

Fig. 203. Absorption of the bone around the molar due to pyorrhea alveolaris. The tooth has no bony attachment at all. (Radiograph by Ream, of Chicago.)

Fig. 204. Absorption of the bony tissue due to pyorrhea alveolaris.

Fig. 201. This is a case from the practice of Dr. M. L. Rhein, of New York City. Dr. Rhein says: "This is a typical example of a chronic alveolar abscess, which for years had been erroneously treated for pyorrhea."

Fig. 202. Fig. 202 represents another case from the practice of Dr. Rhein, which had been wrongly diagnosticated as pyorrhea. The lateral incisor was supposed to be affected by pyorrhea, but after making a radiograph, Fig. 202, it was seen that the real trouble was an apical abscess, the infection arising from the death of the pulp.

26. To Observe Destruction of Tissue Due to Pyorrhea Alveolaris.

Fig. 203. Other factors being equal, our chances of curing pyorrhea alveolaris vary inversely according to the amount of destruction of alveolar process surrounding the affected teeth. Fig. 203 demonstrates the futility of treating and attempting to conserve the molar tooth. All of the bone immediately surrounding the tooth is destroyed.

Fig. 204. A typical case of extensive loss of osseous tissue about the upper anterior teeth due to pyorrhea alveolaris. More than half of the normal attachment of the teeth is destroyed due to the loss of bone. Compare Fig.

Fig. 205

Fig. 206

Fig. 205. Loss of osseous tissue about a lower first molar due to pyorrhea. The distal root has no bone attachment at all and the mesial root an attachment only near the apex. The mesial root seems to be necrotic or carious, but it is not. (See Fig. 436C.)

Fig. 206. The arrow points to bit of calculus on the distal of a second bicuspid. The light area above the calculus denotes the destruction of bone and represents a pyorrhea pocket.

204 with Fig. 207 in which latter case the osseous tissue in the cervical region is healthy.

In this connection it should be borne in mind that the extremely sharp points of alveolar process between the teeth, which can be seen clearly in Fig. 207 about the lateral incisor, are lost with age. Thus care should be taken not to confuse age changes with the disease pyorrhea alveolaris.

Fig. 205. A lower first molar affected with pyorrhea. The distal root is entirely denuded of pericemental membrane and bone and the mesial root also, save just at the apical fourth. (See Fig. 436C.) Extraction imperative.

Fig. 206. A pyorrhea pocket on the distal of an upper second bicuspid. There is but slight destruction of bone. The most remarkable thing about this picture is that it shows a bit of calculus on the distal of the second bicuspid.

27. In Cases of Pericemental Abscess.

"Pericemental abscesses have been described by numerous writers, one of the best papers on the subject being that by Dr. E. C. Kirk, published in the *Dental Cosmos* for November, 1900. There are various views as to the etiology of this condition, but the main point of interest lies in the fact that pericemental abscess occurs on the root of a tooth in which the

Fig. 207

Fig. 208

Fig. 207. Pericemental abscess at apex of upper cuspid. The crowned first bicuspid was suspected, but the radiograph shows an abscess at apex of the cuspid, which was sound and alive. (See Fig. 459A.)

Fig. 208. The light area to which the arrow points is a pericemental abscess.

pulp is still alive, a fact which renders a true diagnosis sometimes quite complex. For example, a patient might present with a well defined fistula appearing between the roots of two teeth, one of which may be perfectly sound, whereas the other might be just as certainly pulpless. It would be quite reasonable for the operator to conclude that an abscess originated from infection coming from the root of the pulpless tooth, and to treat such a tooth, it might be necessary to remove important and well constructed work, such as an inlay or a bridge abutment. A radiograph, however, will disclose that the abscess involves the pericementum of the living tooth, and thus the dentist would be saved the mortification of unnecessarily destroying the inlay or abutment attached to the pulpless tooth, and the patient would be saved the annoyance and expense involved in such a misconstruction of symptoms.

Fig. 207.

"From the practice of Dr. M. L. Rhein is a case of this character. The bicuspid is crowned and might have been suspected as the cause of the abscess, especially as in the radiograph only one root canal filling is seen, but the history of the case made this impossible. The tooth was treated

twelve years ago for an abscess, and both canals were perfectly filled, as can be seen in other radiographs of the case in the possession of Dr. Rhein, these radiographs being taken at a slightly different angle. The tooth having remained perfectly comfortable during all of these years, the well defined abscess disclosed at the apex of the cuspid tooth was diagnosed as a pericemental abscess. The tooth in question was absolutely sound, having no filling or cavity of any kind, and when opened the pulp was found to be alive. Also there was no taint of pyorrhea in this mouth. This diagnosis was confirmed by the fact that the removal of the pulp from the cuspid and subsequent treatment through the canal effected a perfect cure.*"

Fig. 208. Case: A sinus discharging near the apex of an upper cuspid. The cuspid had no carious cavity in its crown, and responded to the cold test. A radiograph (Fig. 208) was made and shows a pericemental abscess on the distal side near the apex of the cuspid, but not involving the apex, and hence was not involving the pulp.

It would have been a mistake to remove the pulp from the cuspid because it was not involved. An incision was made through the external alveolar plate, the pus sinus was thoroughly curetted and then filled with bismuth paste. The result was a prompt and complete cure.

Buckley, in his last edition of his *Modern Dental Materia Medica, Pharmacology and Therapeutics,* prints a radiograph similar to Fig. 208. Before the radiograph was used, in the case reported by Dr. Buckley, the pericemental abscess was diagnosed as an alveolar abscess, due to a dead pulp. The tooth thought to contain a dead pulp was opened, and a vital pulp found. The operators who handled the case experienced a great deal of difficulty in removing the pulp, nitrous oxygen anesthesia being resorted to finally to accomplish it. After removal of the pulp "the tooth (a central incisor) became dark blue in color." In concluding the report of this case, Dr. Buckley says: "The patient in this instance was a lady. and when we recall that the tooth involved was an anterior one, the seriousness of the mistaken diagnosis becomes all the more apparent."

Compared to the occurrence of alveolar abscesses, caused by infection from dead pulps, pericemental abscesses are extremely rare.

28. In Cases of Persistent Suppuration Which Do Not Yield to the Usual Treatment.

Fig. 209. Case: Girl eighteen years old, had had a lower second molar extracted two months previous to the time when she presented to me for treatment. The socket from which the second molar had been extracted was an open

*By Dr. R. Ottolengui.

suppurating sore. The patient was poor, and, wishing to spare her the expense of having a radiograph made, a diagnosis was made to the best of my ability by other means—by symptoms and instrumental examination. The diagnosis was infection by some particularly virulent pyogenic organisms and a slight caries of the bone. I was unable to locate any unremoved piece of tooth root. The socket was vigorously curetted and cauterized with phenolsulphonic acid, a mouth-wash prescribed, and the patient instructed to return in three days. When next seen there was

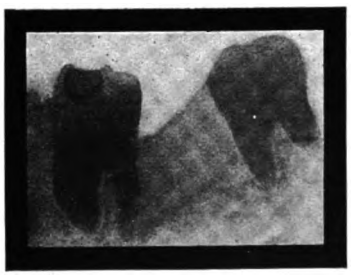

Fig. 209

Fig. 210

Fig. 209. An unerupted third molar which caused sufficient irritation to sustain a suppurating wound from where a second molar was extracted.

Fig. 210. A case of persistent suppuration of several years' standing. The radiograph shows the cause—an impacted, malposed upper cuspid. (Radiograph by Lewis, of Chicago.)

but slight improvement in the objective symptoms, and the patient reported that there had been no abatement in pain and soreness. The lesion was washed thoroughly with an antiseptic solution, and the patient instructed to return in three days. When seen again there was no improvement over what had existed before the operation. Wishing to get a more complete and reliable history of the case, I consulted with the patient's physician. He had treated the oral lesion before the case came to me, and was of the opinion that it was tubercular. He suggested the tuberculin treatment. A radiograph (Fig. 209) was made to make sure that there was not a piece of the second molar still in the jaw. As can be seen, there is no piece of tooth root present, but what we do see is an erupting third molar. Perhaps I should have thought of the third molar as a cause for the trouble. But I did not until the radiograph was before me. Believing this tooth, in its effort to erupt, to be responsible for a slight irritation and the consequent suppuration, the soft tissues and the

bone covering it were dissected away. The result was immediate improvement. I regret that I cannot definitely report a complete recovery, but I am sure it occurred. The patient left the city about a week after the last operation, and I have not seen nor heard from her since.

Fig. 210.

I have already referred to a case of persistent suppuration, reported by Dr. T. W. Brophy, which did not yield to treatment until a radiograph disclosed the presence of a supernumerary tooth, and it was removed. In answer to a letter of mine, asking for a radiograph of the case, Dr. Brophy

Fig. 211

Fig. 212

Fig. 211. Abscess at the apex of the shell-crowned, second bicuspid. It is very difficult to observe either the abscess or the unfilled canal in the bicuspid in the print, though both show clearly in the negative. The arrow A points to the abscess at the apex of the tooth. The arrow B points to an abscess on the side of the root, caused by the ill-fitting shell-crown.

Fig. 212. Same case as Fig. 211. The dark shadow is bismuth paste. It passes from the apex of the upper second bicuspid downward and towards the second molar.

informed me that it could not be found, and enclosed Fig. 210, saying it was a similar case, *i.e.*, a case of persistent suppuration, which did not yield to treatment until the radiograph showed the exciting cause, and it was removed. The history of the case, illustrated in Fig. 210, is about as follows: The upper lateral became abscessed. It was treated, and the canals filled. Pus continued to flow from a fistulous opening on the labial. The abscess was treated through the alveolar plate, but without success. A radiograph was made. I quote Dr. Brophy. "It (the radiograph) exhibits a cavity in the bone, absorption of the apex of the root of the lateral, as well as the apex of the root of the adjacent central tooth. Above is an impacted cuspid lying in a nearly horizontal position. To cure a case of this character calls for most careful study, deliberation and action. The course to pursue is largely dependent upon the condition of the other teeth forming the upper denture. In a young person, the removal of the lateral incisor root, which is crownless and diseased, and the gradual moving downward into its place of the cuspid would be the most desirable procedure. If the patient is in middle life, and the teeth

badly diseased and loose, as the teeth here represented are, I would recommend the removal of the diseased teeth, diseased bone, and impacted tooth. The history of this case, with suppuration extending over a period of several years, so beautifully and clearly illustrated by the use of the Roentgen photograph, impresses us with the inestimable value of this means of reaching a diagnosis."

29. To Observe the Course of the Fistulous Tract.

Dr. Emil Beck, of Chicago, was the first to use bismuth paste* in radiography. The paste is opaque to X-rays. Thus Dr. Beck would inject a fistula and abscess cavity, then, with the paste injected, make a

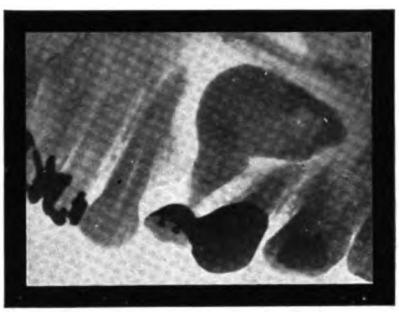

Fig. 213. Bismuth paste injected into fistulous opening just above the first bicuspid dummy and nearly filling a very large abscess cavity. (Radiograph by Ream, of Chicago.)

radiograph. Deep shadows would be cast onto the film or plate by the subnitrate of bismuth, showing distinctly the course of the fistula and the extent of the abscess cavity.

The curative property of bismuth paste was discovered truly by accident. After using the paste to enable him to make better radiographs, Dr. Beck noticed that some bad pus cases recovered.

"Cargentos," a colloidal silver oxid, made by Mulford & Company, can be used as bismuth paste is used, for either radiographic purposes or as a remedy.

When the use "to observe the course of a fistulous tract" suggested itself to me, I had in mind a case which I treated some years ago. It was a case in which a fistula pointed externally at the symphysis. Without going into a detailed history of the case, let it suffice to say that a sound and not very badly impacted lower third molar was finally extracted and the case recovered. Probing to the seat of the trouble was impossible, but had the fistula been injected with bismuth paste and a radiograph made, the connection between the third molar and the fistulous opening

*Bismuth subnitrate, vaseline, paraffine and white wax.

at the symphysis would have been clearly shown. I regret that I have not been able to obtain a radiograph of such a case. I have not, however, and must, therefore, content myself with a report of the only case I have in which bismuth paste was used to trace a fistulous tract.

Figs. 211 and 212. Case: A fistulous opening on the buccal near the apex of an upper second bicuspid; the first molar missing. Another fistulous opening on the buccal just above the gingival line of the second molar. A probe entering the fistula above the bicuspid led to its apex. A probe entering the fistula of the molar seemed to lead to the bifurcation of the roots of the molar. Having at a previous date treated the molar, and so knowing the condition of the canals, I was reluctant to believe that the tooth was abscessed.

Fig. 214

Fig. 215

Fig. 214. Before apicoectomy. Notice the considerable canal filling forced through the apical foramen. (Radiograph by Blum, of New York City.)

Fig. 215. Same case as Fig. 214. After apicoectomy. (Radiograph by Blum, of New York City.)

I entertained the belief that both fistulous openings led to an abscess at the apex of the bicuspid, but I could not verify this belief by probing. A radiograph (Fig. 211) shows the canals unfilled, and an abscess at the apex of the bicuspid. It shows also that there is no abscess at the apex of the molar roots. But it does not show a fistula leading from the bicuspid to the molar. The shell-crown on the bicuspid was removed and phenolsulphonic acid pumped through the tooth and out of the fistula over the bicuspid, but the acid could not be forced through the bicuspid and out at the opening over the molar. The tooth and both fistulous openings were injected with bismuth paste and a radiograph made. (Fig. 212.) I was then able to see that, as I had suspected, the seat of the trouble was at the apex of the bicuspid. The molar did not need treatment. The phenolsulphonic acid could not be forced through the bicuspid and out at the molar fistulous opening, because it traveled the path of least resistance out the nearer opening. The fistulous tract could not be

seen without injection with bismuth paste, because there was so little bone destruction. Throughout most of its course the fistula traveled between bone and periosteum.

Fig. 213. A large abscess arising at the apex of the second bicuspid, and discharging above the artificial first bicuspid. Bismuth paste injected into the fistulous tract. Perhaps the cuspid is involved also. It should be tested for vitality of its pulp.

Fig. 216

Fig. 217

Fig. 218

Fig. 216. The apex of the lateral was cut off, then lost. The radiograph shows its location, so aiding materially in its removal. (Radiograph by Ream, of Chicago.)

Fig. 217. A chronic abscess at the apex of an upper central incisor. The tooth carries a post-porcelain crown and the canal is filled almost to the apex. (Radiograph by Lewis, of Chicago.)

Fig. 218. The same as Fig. 217 four days after the amputation of the apex of the central and curettement of the pus sinus. (Radiograph by Lewis, of Chicago.)

30. To Observe the Field of Operation Before and After Apicoectomy (Root Amputation).

Figs. 214 and 215. When a tooth fails to respond to less radical treatment, and it is deemed necessary to amputate a portion of the apex of the root, the question naturally arises, how much of the root shall be cut off? A good radiograph will answer this question. Observe that a great amount of canal filling penetrates the apical foramen. Fig. 215 is of the same case illustrated in Fig. 214 immediately after the operation.

Fig. 216. In his work on *Materia Medica and Therapeutics,* Dr. Buckley reports an interesting case of apicoectomy, in which the apex was amputated, then lost. A radiograph was made. (Fig. 216.) Dr. Buckley says: "This radiograph aided materially, as it verified the presence of the root-end and its location."

Figs. 217 and 218. Radiographs from Dr. Buckley's *Modern Dental Materia Medica, Pharmacology and Therapeutics.* They are exceptionally good pictures taken before and after amputation of the apex.

31. To Locate Foreign Bodies, Such as a Broach in the Pulp Canal or Tissue at the Apex of a Tooth; A Piece of Wooden Toothpick in the Peridental Membrane, Etc.

Fig. 219. Case: A young lady about twenty-five years of age. Abscess pointing near the apex of an upper central incisor carrying a post porcelain crown. I suspected that the canal of the central was not filled properly, and made a

Fig. 219

Fig. 220

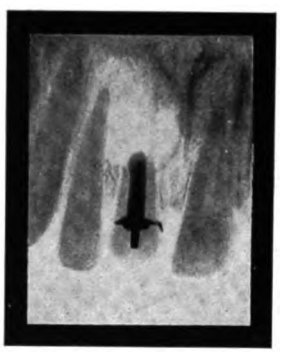

Fig. 221

Fig. 219. Cement and gutta-percha—mostly cement—in an abscess cavity at the apex of a post-porcelain crowned central incisor.

Fig. 220. Same as Fig. 219, after what was thought to be all of the cement and gutta-percha was removed. The radiograph shows both some cement (the larger shadow) and some gutta-percha (the small shadow) still remaining in the abscess cavity.

Fig. 221. The same as Fig. 219, showing the abscess cavity clear of all foreign bodies.

radiograph (Fig. 219) to learn if in this surmise I was correct. The radiograph shows the canal filled. At the apex of the root can be seen a large abscess cavity, with foreign bodies of some nature in it.

Fig. 220. An incision was made on the labial aspect, and what was thought to be all of the foreign material, which proved to be cement and gutta-percha—mostly cement—was removed through the external alveolar plate. A radiograph (Fig. 220) was made, and shows some cement (the larger shadow) and some gutta-percha (the small shadow) still in the abscess cavity.

Fig. 221. These bodies were removed and another radiograph (Fig. 221) made to prove that no foreign irritating body remained in the abscess cavity.

Fig. 222. The pus sinus was then curetted, washed, cauterized, injected with bismuth paste, and another radiograph (Fig. 222) made. All of this work was done at one sitting, and consumed about two hours time. The radiograph (Fig. 222) shows that the bismuth paste does not entirely fill the abscess sinus. It has been my experience that the most vigorous and earnest efforts often fail to "completely fill" an abscess cavity with bismuth paste. The manufacturers of the paste tell us that "every crevice" must be filled

Fig. 222

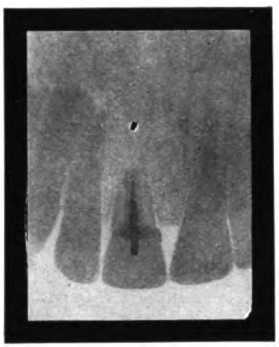

Fig. 223

Fig. 222. Same as Fig. 219. The abscess cavity filled with bismuth subnitrate paste.

Fig. 223. Same as Fig. 219, three and one-half months after the operation. The abscess cavity is entirely filled with new bone. The new bone is as yet not quite as dense as the surrounding bone.

or the paste will not have the desired curative effect. Every crevice that can be filled should be, I concede. But I am showing you a case now in which the sinus was not quite filled, and, as we shall see presently, the results obtained were ideal. Three days after the operation another injection of bismuth paste was made. At this sitting the paste was not injected under as much force as the previous injection, for I did not wish to break up and destroy any granulation tissue that had formed along the walls of the sinus. Another injection under even less pressure than the second was made at the end of four days. The patient returned one week after the third injection with no symptoms of her former trouble.

Fig. 223. Three and one-half months after the operation Fig. 223 was made. It shows a most remarkable and gratifying condition. The abscess cavity is entirely filled with new bone. This new bone is as yet not quite as dense as the surrounding bone.

Fig. 224. Case: Man of middle age had suffered obscure neuralgic pains for about a month. None of the teeth on the affected side were tender to percussion

or pressure. A radiograph (Fig. 224) was made to learn whether or not the canals of the upper second molar were filled. There was a very large amalgam filling in this tooth. The radiograph does not show the roots of the molar well, but it *does* show a dark shadow between the second and third molars just above the cervical margin of the filling in the distal of the second molar. On inquiry it was learned that the patient was in the

Fig. 224

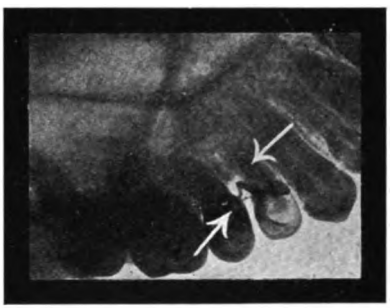

Fig. 225

Fig. 224. The arrow points into a piece of wooden toothpick between the second and third molars.

Fig. 225. The upper arrow points to a piece of broach in the canal of the upper first bicuspid. The lower arrow points to a piece of gutta-percha passing through a perforation to the distal.

habit of using wooden toothpicks. Suspecting the shadow to be a piece of toothpick, an attempt was made to remove it with explorers, canal pluggers and silk floss. The effort met with failure, but, feeling sure that my diagnosis was correct, the third molar was extracted. The piece of toothpick adhered to the extracted tooth. There was an immediate and complete recovery from pain.*

*Immediately after Fig. 224 appeared in the May, 1912, issue of ITEMS OF INTEREST, Dr. C. Edmund Kells, Jr., wrote to me saying there must be some mistake, that wood was "absolutely transparent" to the X-rays, and that according to the halftone, Fig. 224, the piece of toothpick cast a denser shadow than the amalgam filling in the molar tooth. I replied, insisting that wood was not "absolutely transparent" to X-rays, explaining that it had been necessary to retouch the print to make the shadow of the pick show at all in the halftone, and enclosing the original negative of the case. I then received two disassociated molar teeth stuck together, side by side, with pink paraffin and wax, and a piece of toothpick in the wax, parallel to the long axis of the teeth. Also a radiographic negative of the teeth and a letter from Dr. Kells, saying he had tried to make a radiograph of the pick and had failed. I glanced at the negative and could see only the teeth—neither the wax nor the piece of pick between them. I made a radiograph of the test specimen Dr. Kells had sent me and succeeded in showing both the wax and that part of the ends of the piece of toothpick which extended beyond the wax. That part of the pick covered with paraffin and wax could not be seen.

I was talking of the experiment and showing my own radiographs to a dental student. The student asked to see Dr. Kells' negative, he examined it and said, "Why, I can see the same thing in this that I see in your picture." And so he could. When examined closely Dr. Kells' negative showed the ends of the piece of toothpick extending beyond the wax. I had not examined it carefully enough before —neither had Dr. Kells.

I appreciate the interest Dr. Kells takes in my work, and I thank him most earnestly for calling my attention to what seemed to be a mistake, but having radiographed a piece of toothpick experimentally, I shall not retract anything said regarding Fig. 224.

Fig. 225. Case: Young woman, had been in the hands of an incompetent dentist, who had treated an upper first bicuspid for several weeks, and had finally advised its extraction, whereupon the patient left him, presenting to me, and asking if the tooth could not be saved. A radiograph (Fig. 225) was made, and shows a piece of broach in the canal and a perforation to the distal through which passes a gutta-percha point. About the end of the point is an abscess. Owing to the position of the tube, which was placed

Fig. 226

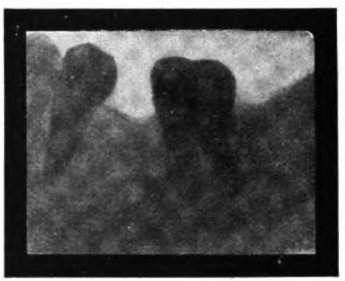

Fig. 227

Fig. 226. Unremoved mesial root of a lower second molar.

Fig. 227. The radiograph proves the absence of an unremoved root of the lower first molar.

too high, the teeth in the picture are too short, and the perforation, which was well above the gum line—too far to be detected—seems to be just at the neck of the tooth.

I agreed with the "incompetent dentist" that the tooth could not be saved. The condition revealed by the radiograph could not have been learned by any other means save extraction and dissection of the tooth.

32. To Determine the Presence or Absence of a Bit of Root Imbedded in the Gum Tissue.

After the extraction of a great number of teeth, or after having been operated upon by some other dentist, a patient will present with the gum tissue highly inflamed and, pointing to the inflamed area, say, "Isn't there a piece of tooth there yet?" Unless the X-rays are used it is necessary to anesthetize the parts and dissect away some of the soft tissues to determine whether the inflammation may be due to an unremoved bit of tooth root, an unresorbed spicula of process, or a bit of process fractured from the jaw. This requires a great deal of time and work, and causes the patient unnecessary pain. The radiograph should be used.

Fig. 226. Case: Much swelling of the face on the affected side. The patient was unable to open the mouth to any extent without considerable pain. Two weeks

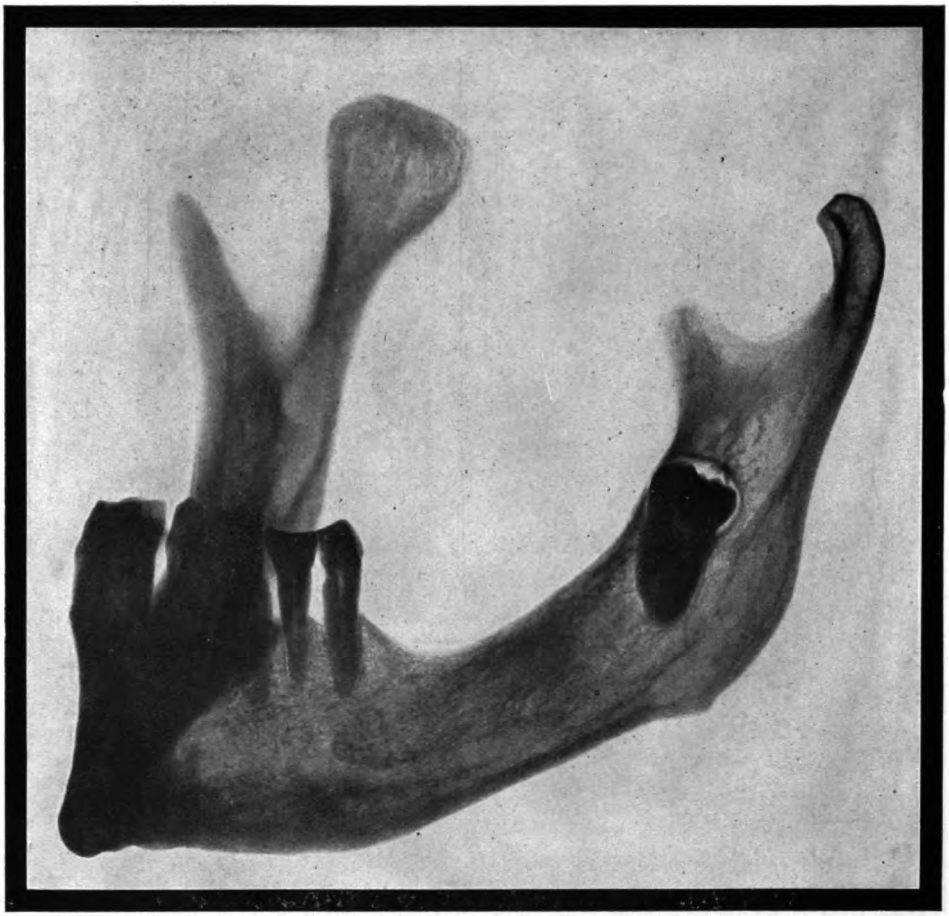

Fig. 228. This radiograph is of a dry subject. Pictures of dry bones show clearly because there are no soft tissues to penetrate. The third molar is badly impacted in the ramus. (Radiograph by Cryer, of Philadelphia.)

previously the lower second molar on the affected side had been extracted (?) by a quack dentist. The question naturally arose, "Has all of the second molar been removed?" A radiograph (Fig. 226) was made, and shows that the mesial root still remains. It was taken out, and the case recovered promptly. The advantages derived from using the radiograph in this case were as follows: It saved the patient the pain of opening the mouth for a prolonged instrumental and ocular examination; and also the pain caused by lancing, dissecting, and probing incident to such an examination. It saved both the patient and the operator time. It showed clearly and exactly how much of the tooth was left, and illustrated its

exact location. It made the extraction of the piece of root decidedly easier for both patient and operator.

Figs. 227 and 228. Fig. *227* is of a case similar to that shown in Fig. *226*. In this case, however, the second molar had been extracted a year previously, and the radiograph shows no unremoved bit of tooth root. The radiograph fails to disclose a cause for the clinical signs. But let me impress you with this fact: it does show that an unremoved bit of tooth root is *not* the cause, and so aids us very greatly in a diagnosis by elimination. The patient did

Fig. 229. A piece of tooth root and an impacted cuspid in an otherwise edentulous upper jaw. (Radiograph by Lewis, of Chicago.)

not return after his first visit, so the case was never diagnosed. There may have been a third molar impacted in the ramus. (See Fig. *228*.) No one can deny the possibility. We took only the first step toward diagnosis—we eliminated a possible cause.

Fig. 229. Though I have been unable to obtain a definite history of this case, it is, in all probability, about as follows: After the extraction of the upper teeth the patient returned with a localized inflammation of the gum tissue in the cuspid region. A radiograph was made to learn if this inflammation was caused by an unresorbed bit of process or a piece of tooth root. The picture shows not only a piece of tooth root, but also an impacted cuspid tooth. It is not unlikely that this patient suffered from obscure neuralgic pains, headache, or other nerve affections.

Fig. 230. Notice the bit of root imbedded in the process. My chief reason for exhibiting this picture is because it shows so clearly the gum tissue overlying the process.

Fig. 231. A piece of root, one end of which rests on the edge of an ill-fitting shell crown, the other against the cuspid tooth. The inflammation caused by this root extends up to the apex and to the mesial of the cuspid. In such a position the root could never have dropped down to where it could be seen in the mouth.

Fig. 230

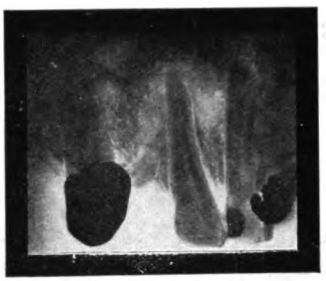

Fig. 231

Fig. 230. The arrow points to a bit of tooth root. Notice how clearly the gum tissue shows in this radiograph. (Radiograph by Ream, of Chicago.)

Fig. 231. A bit of tooth root, one end resting on the edge of an ill-fitting shell crown, the other against the cuspid. The abscess caused by this piece of root extends to the apex and to the mesial of the cuspid. (Radiograph by Blum, of New York City.)

33. To Diagnose Fracture of a Root.

Figs. 232 and 233. Within the same week two cases in which the upper anterior teeth had sustained a severe blow presented at the college clinic for treatment. In one case a lateral incisor (Fig. 232), and in the other case both centrals (Fig. 233) were very loose. Radiograph Fig. 232 shows the root of the lateral fractured. Extraction is indicated. Radiograph Fig. 233 shows that the roots of the centrals are not fractured. Extraction is contraindicated. (As can be seen in the radiograph, both central crowns are broken off, and one lateral is knocked out completely.) It will be appreciated that the radiographic findings in these cases governed completely our course of treatment. I would suggest it as a most rational expedient that radiographs be taken in all cases of traumatism, before treatment is begun.

Fig. 234. Case: Young lady fell on dance hall floor striking the upper centrals and loosening them. Her dentist treated both teeth, removing inflamed pulps. One tooth progressed promptly to recovery, but the other remained loose and sore. After several weeks of treatment the patient presented to Dr. F. B. Moorehead, of Chicago, who had a radiograph made before commencing treatment. The radiograph shows the root of the loose tooth fractured

near the apex. Dr. Moorehead removed the apex of the root through the external alveolar plate, smoothed the end of the broken root, and the case recovered promptly. It is almost superfluous to do so, yet I want to call your attention to the fact that this case, like very many others I have reported, could not have been diagnosed and treated properly without using the radiograph.

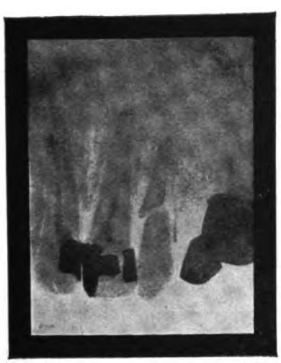

Fig. 232

Fig. 233

Fig. 234

Fig. 232. Fractured upper lateral incisor. Because of the location of the break extraction is indicated.

Fig. 233. It was thought that the roots of the centrals were fractured. The radiograph shows they are not.

Fig. 234. Left central fractured near the apex. The case had been treated for alveolar abscess without success for several weeks. The removal of the piece of fractured root-end through the external alveolar plate effected a cure. (Radiographed by Lewis, of Chicago.)

34. To Observe the Size and Shape of Roots of Teeth to be Used in Crown and Bridgework.

Fig. 235.

Malformed upper laterals—"peg laterals"—occur quite frequently. Their appearance is bad, and, for esthetic reasons, we often crown them. The porcelain jacket crown is difficult to construct and, at best, fragile. If the root of the peg lateral is long enough the operator may elect to use a post porcelain crown of some kind instead of the porcelain jacket. Fig. 235 shows a peg-shaped lateral. In this case the root is *long* enough but it is bent, which increases the risk attending devitalization and canal work.

Before using teeth as abutments for large bridges, it would not be unwise to make radiographs to note the size of the roots. It would be a mistake, I believe, to use such a tooth as the malformed one shown in Fig. 236 as an abutment for a bridge of any extent. It should be borne in mind that unless the pose is exactly right—and we seldom have it so—the teeth, as they appear on the radiograph, do not represent definitely the exact length of the teeth themselves. Nevertheless, the radiograph does give us a fairly definite idea of the relative length of the teeth.

Fig. 236.

Fig. 235 Fig. 236

Fig. 235. A peg lateral, the root of which is somewhat tortuous. (Radiograph by Blum, of New York City.)

Fig. 236. A malformed cuspid tooth. It would be a mistake to use such a tooth as an abutment for a large bridge.

35. As an Aid and Safeguard When Enlarging Canals for Posts.

There are times while enlarging canals for posts when we lose the course of the canal and are much disturbed to know if we are making our enlargement in the proper direction. Place a wire in the canal and make a radiograph. If the enlargement is being made to the mesial or distal, with danger of a perforation, this can be seen in the picture. One might completely penetrate the side of the root towards the labial, or buccal, or lingual, without being warned of the danger by a radiograph, but, bear in mind, perforations made through the side of a root are usually either to the mesial or distal.

In Fig. 237, observe the central carrying a post porcelain crown. The post does not follow the canal. Had the enlargement for it continued in the same direction as was started, the dentist would have penetrated the side of the root. A radiograph of this case would have enabled the operator to see his mistake and correct it.

Fig. 237.

Fig. 238. This radiograph shows a perforation through the side of the root, to the distal, in an upper second bicuspid. The perforation was made when enlarging the canal for a post. A probe passes through the side of the root, up into an abscess cavity at the apex of the tooth.

The radiograph is an aid not only when we are enlarging canals for posts, but also when we are removing posts from canals. It shows us how long the post is, and how much tissue we can cut away from the sides of it in safety.

Fig. 237

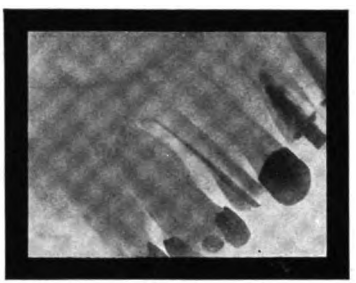

Fig. 238

Fig. 237. The post in the post-porcelain crowned central does not follow the canal. It almost penetrates the side of the root. (Radiograph by Graham, of Detroit.)

Fig. 238. Perforation through the side of the root of an upper second bicuspid. A probe passes through the perforation. (Radiograph by Graham, of Detroit.)

36. To Examine Bridges About Which There Is An Inflammation.

Figs. 239 and 240. At best fixed bridges are not sanitary. For this reason we often find an intense inflammation about them. Thorough depletion by scarifying and the use of an astringent, antiseptic mouthwash will usually give prompt relief. There may be causes for the inflammation other than the simple fact that the bridge is a foreign body in the mouth, making thorough cleanliness impossible. Observe Figs. 129, 239 and 240 as examples. It would be extremely difficult to remove the bit of root shown beneath the bridge in Fig. 239 without removing the bridge. The piece of root shown in Fig. 240 can easily be removed through the external alveolar plate without removing the bridge. Such treatment, however, is not indicated in this particular case.

I have recently heard of a case in which a very severe inflammation existed about a bridge which had only been set for about a week. The case was treated for several days, and finally the bridge removed when it was seen that, at the time the bridge was set, a considerable quantity of

cement had been forced into the tissues near a shell crown abutment. Removal of this cement effected a prompt cure. Had a radiograph been made, the cause of the trouble would have been seen immediately, and, depending on the exact location of the cement, removal of the bridge may have been avoided.

Fig. 239

Fig. 240

Fig. 239. A piece of tooth root in the tissues beneath a bridge. (Radiograph by Lewis, of Chicago.)

Fig. 240. A piece of tooth root in the tissues above a very large bridge. (Radiograph by Lewis, of Chicago.)

37. To Observe the Field Before Constructing a Bridge.

This use of the radiograph has already been illustrated—Figs. 129, 239, and 240. The radiograph will not only disclose the presence of unerupted teeth, and unremoved pieces of tooth roots, but, as has been suggested under another heading, it will also show the operator the size, shape and health of the roots of the teeth he is using for abutments.

38. To Observe Planted Teeth.

Figs. 241 and 242. Case: One in the practice of Dr. C. Edmund Kells, Jr., Fig. 241, shows a fracture of the root of a lateral, the result of a fall. After the two pieces of the lateral were extracted they were united and held together with an iridio-platinum screw set in cement, and the repaired root then replanted. The radiograph (Fig. 242) was made immediately after the operation. A gold splint is seen covering the crown of the cuspid, lateral and both centrals.

Fig. 243. A case of replantation of a lower second bicuspid two years and four months after the operation. The root is almost entirely absorbed. Notice how plainly the pericemental membrane can be seen about the roots of the first bicuspid and first molar, appearing as a light line. Notice also the absence of this line about the remaining portion of the root of the replanted tooth.

The theory of the attachment of planted teeth is as follows: The roots of the planted teeth are absorbed at different points, and bone

Fig. 241.

Fig. 242.

Fig. 241. Fracture of upper lateral incisor. (Radiograph by Kells, of New Orleans.)
Fig. 242. Same as Fig. 241 after the removal of the lateral and its replantation. (Radiograph by Kells, of New Orleans.)

immediately fills into these places, so holding the tooth. Hence, planted teeth do not have a pericemental membrane. Radiographic findings bear out this theory.

Fig. 244. Fig. 244 shows an implanted porcelain root. Observe that the root has practically no bony attachment at all, and would drop out save for the manner in which it is splinted to the other central.

Fig. 245. Dr. E. G. Greenfield, Wichita, Kas., has designed and manufactured a sort of cage-like root of iridioplatinum wire to be used for implantation. So far all forms of artificial roots for teeth have proven failures, but this one bids fair to be a success. Whether it will be a success or not depends on whether or not bony tissue will build in and about the wires. The radiograph (Fig. 245) is introduced more for the purpose of showing the artificial roots than for any other reason. The radiograph has not been made in such a way as to enable us to see whether there is an osseous deposit within the wires or not.

39. In Cases of Cementoma.

Cementomata (or cases of hypercementosis, as they are often called) are sometimes the cause of neuralgia. There are no means at our disposal whereby they (cementomata) can be diagnosed save by the use of the radiograph.

Fig. 243.

Fig. 244.

Fig. 243. A case of replantation of the lower second bicuspid two years and four months after the operation. The root is almost entirely absorbed. (Radiograph by Kells, of New Orleans.)
Fig. 244. Artificial porcelain root with no bony attachment. (Radiograph by Ream, of Chicago.)

Figs. 246 and 247. These radiographs illustrate cementomata. Extraction was necessary in both cases. Experience is teaching me that when hypercementosis occurs it is usually on a pulpless tooth.

40. In Cases of Bone "Whorls."

The term bone whorl is used to designate particularly dense areas of bone occurring in bone Bone whorls may be caused by a prolonged, mild irritation, like that produced by an impacted tooth, for example. They are sometimes responsible for facial neuralgia. In answer to a letter asking him if he ever found it necessary, or ever expected to find it necessary, to open into the bone and surgically break up whorls to relieve neuralgia, Dr. Cryer replies, "I have found it necessary in several cases to open into the bone and remove the whorls, or hard bone, and I fully expect to do so again." From the nature and location of whorls, it is obvious that they can be found only by the use of the radiograph.

Fig. 248. Fig. 248 illustrates the radiographic appearance of a bone "whorl."

Fig. 249. The spot indicated by the arrows has the appearance of a bone "whorl." It is not, however, it is a piece of the third molar. Under a general anesthetic the second molar was removed in an effort to extract the third

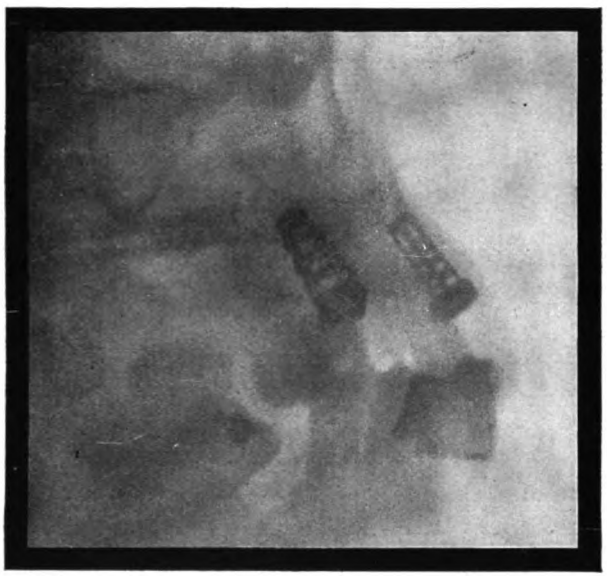

Fig. 245. Two artificial roots implanted in the upper jaw. (Radiographer not known.)

Fig. 246.

Fig. 247.

Fig. 246. Cementoma on lower, second, shell-crowned molar. (Radiograph by Ream, of Chicago.)
Fig. 247. Cementoma. (Radiograph by Ream, of Chicago.)

molar. Another effort was made to remove the third molar when, unknown to the operator, a piece of the third molar was broken off and dropped in the alveolus of the second molar. The second molar was then replanted.

The following report is of a case from the practice of Dr. Cryer. The patient was suffering from pain on one side of the face. A radiograph of the affected side showed an impacted third molar. Removal

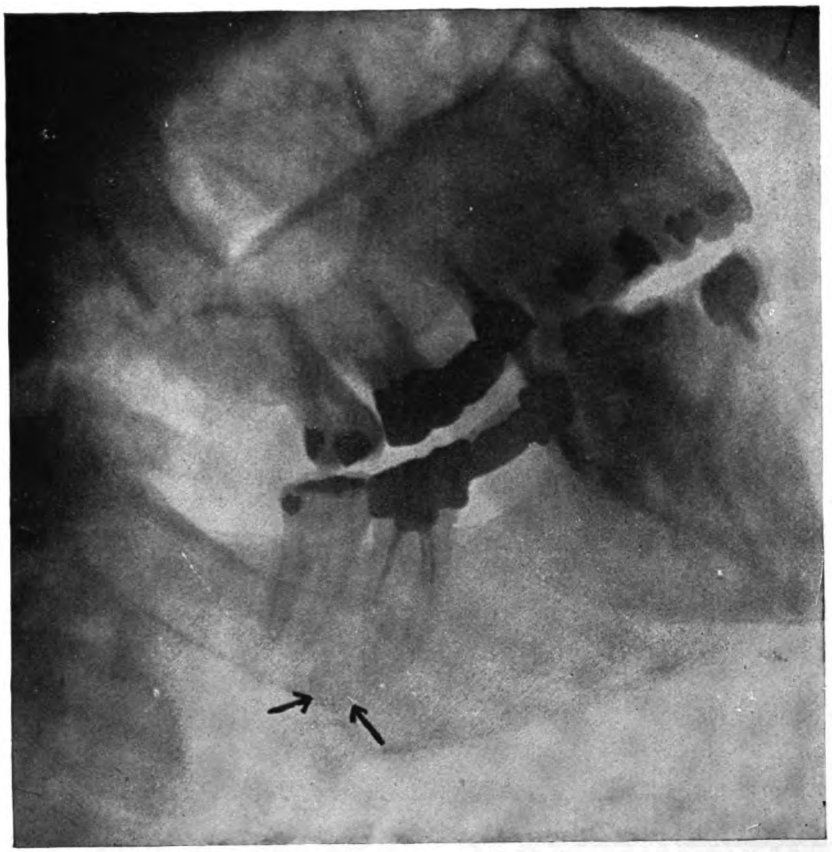

Fig. 248. The arrows point to a bone "whorl."

of this tooth gave relief for about ten days when there was a recurrence of pain. Another radiograph was made which revealed the presence of a bone "whorl." Another operation was done removing the "whorl," after which neuralgia disappeared altogether.

Fig. 250

Case in the practice of Dr. Robert H. Ivy, of Philadelphia. "The patient had suffered from neuralgia of the mandibular division of the fifth nerve on the right side, for two years. In February, 1911, she was treated by an alcohol injection of this division, which gave relief from pain for six months, after which the trouble returned, but not so severely as before. In January, 1912, a skiagram was made, showing a dense spot in the

region of the first molar tooth, and in close relation to the inferior dental nerve. This is so dense as to appear like a piece of tooth root, but when cut down upon with the surgical engine, nothing but dense bone was found. The patient has been without neuralgia since the operation, though it is too soon yet to say whether the relief will be permanent."

41. To Locate Stones (Calculi) in the Salivary Ducts or Glands.

Fig. 251.

The history of this case given me by Dr. Sidney Lange, of Cincinnati, Ohio, is as follows: Patient, female, age about forty, suffered recurrent attacks of swelling and pain in the region of the submaxillary gland on one side.

Fig. 249. The arrows point to a spot having the appearance of a bone "whorl." It is not a bone "whorl," however.

The attacks seemed to follow the taking of sour foods. A radiograph (Fig. 251) was made. The arrow points to a stone in the submaxillary duct. Because the patient had had a stone removed from the same duct several years previously, and because the gland was considerably thickened, simple removal of the stone was thought to be contraindicated, and a more radical operation involving the removal of the entire gland was performed.

42. In Cases of Bone Cysts.

"A cyst is an organized structure consisting of a sac-like wall together with its contents, especially one of pathological formation or abnormal development."—*Appleton's Medical Dictionary.*

Fig. 250. The dark shadow to which the arrow points is a bone "whorl." (Radiograph by Pancoast, of Philadelphia.)

According to this definition all chronic alveolar abscesses are cysts—bone cysts, because they occur in bone. But the name cyst is usually not applied until the abscess sac assumes a great size. The abscess in Fig. 193 is large enough to be called a cyst, in the generally used sense of the term.

Fig. 252. This radiograph shows a large cyst in the lower jaw. The two roots of the lower first molar are doubtless responsible for the cyst formation.

In cyst cases there is often considerable and disfiguring enlargement of the bone, and such cases are spoken of as cystic tumors, a tumor, of course, being simply an abnormal enlargement or growth.

Fig. 253

A man, age about thirty-seven, was referred to the college clinic "to have a growth on the lower jaw cut off." There was no "growth" to "cut off." There was a definite enlargement of the bone in the lower first molar region,

Fig. 251. The arrow points to a stone in the submaxillary duct. (Radiograph by Lange, of Cincinnati.)

giving the man the appearance of carrying a large lump of tobacco in the vestibule of the mouth. The patient suffered local pain, and the involved area was tender to palpation. The first molar tooth was missing from the jaw. A radiograph was made and showed a cyst involving the second bicuspid and second molar. (I regret that the radiograph has been lost.) Neither the second bicuspid nor the second molar had cavities nor fillings in them. Considering the evidence of neglect of the mouth and teeth, it was not deemed worth while to try to conserve the teeth. Accordingly the second bicuspid was extracted, which permitted the escape of considerable watery, brown pus. A doubt then arose as to whether the radiograph showed an involvement of the molar or not. Another radiograph (Fig. 253) was made. It shows that the molar is involved. It was extracted and more serous pus evacuated. Antiseptic solutions

could now be washed from one tooth socket, through the cyst, and out at the other tooth socket. The cyst was curetted, cauterized and packed with sterile gauze. Healing except from within outward was prevented by the use of gauze, and the case recovered. Relief from pain and soreness was

Fig. 252. Large cyst in the lower jaw. The more or less oval-shaped light area represents the cyst. (Radiograph by Lewis, of Chicago.)

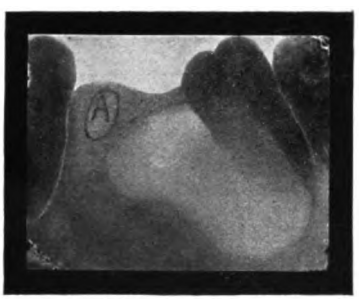

Fig. 253.

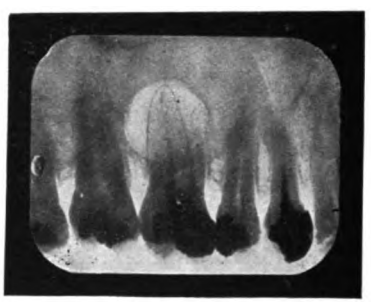

Fig. 254.

Fig. 253. Cyst in lower jaw. The circle A is the alveolus from which the second bicuspid was extracted. Fig. 254. Cyst in upper jaw, in apical region of pulpless upper first molar. Enlargement, as seen in mouth above first molar, about the size and shape of one-half hazelnut.

immediate. It required two or three months for all of the enlargement of the jaw to disappear.

In my experience as a radiographer I have observed that the general practitioner of dentistry shows great reluctance to extract a tooth, no matter what the condition he is treating may be. On the other hand, the

specialist in oral surgery extracts teeth sometimes without making the slightest effort to conserve them. I believe, however, that the oral surgeon is less often mistaken. A man may make a greater mistake than the extraction of a tooth. For example: failure to extract a tooth which is causing otherwise incurable suppuration, general sepsis, nervous disorders, necrosis or distracting pain.

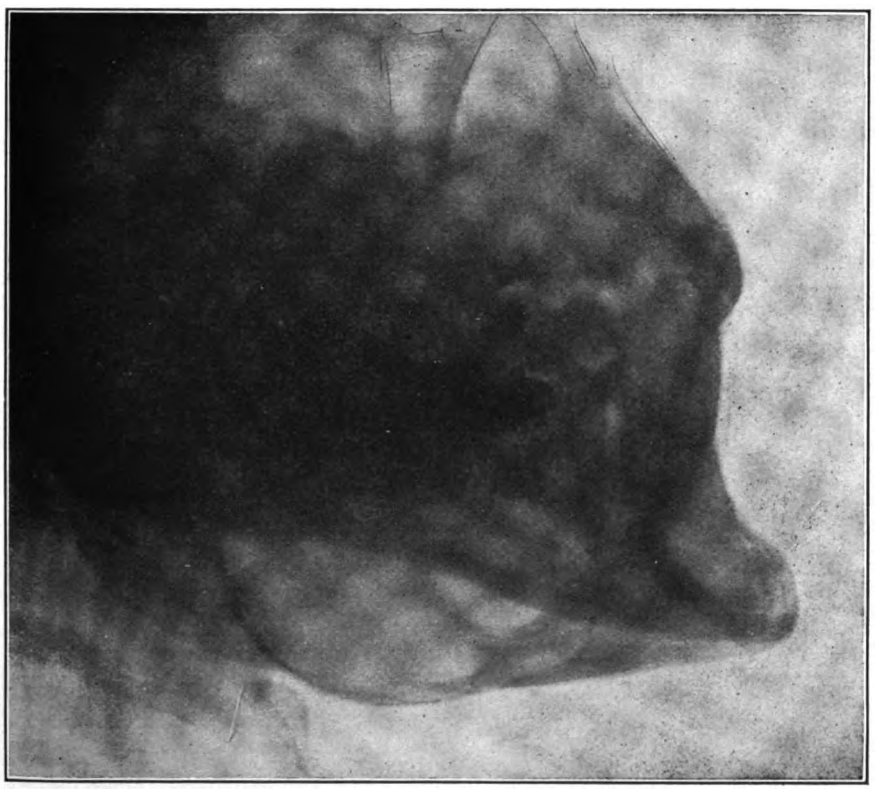

Fig. 255. A very large cyst of the lower jaw. The light area represents the cyst. This radiograph shows the hyoid bone. (Radiograph by Lange, of Cincinnati.)

Fig. 255.

Dr. Sidney Lange, of Cincinnati, made the radiograph shown in Fig. 255, but did not treat the case. Dr. Lange was, however, able to furnish the following history: Patient, boy, about eighteen. Very large swelling in the lower jaw. No pain or tenderness in the region of enlargement. A radiograph (Fig. 255) was made, and the case diagnosed as a "benign bone cyst." The boy was taken to a hospital and the cyst drained of a straw-

colored fluid, curetted and packed with gauze, through an opening made inside of the mouth to the buccal. The patient left the hospital in a week or two after the operation.

Fig. 256. Case: Male, age about twenty-five. Enlargement of the mandible at the symphysis. Tenderness, intermittent local pains. The radiograph shows a large cyst. Failing to keep an appointment, the patient has not been heard of since the radiograph was made.

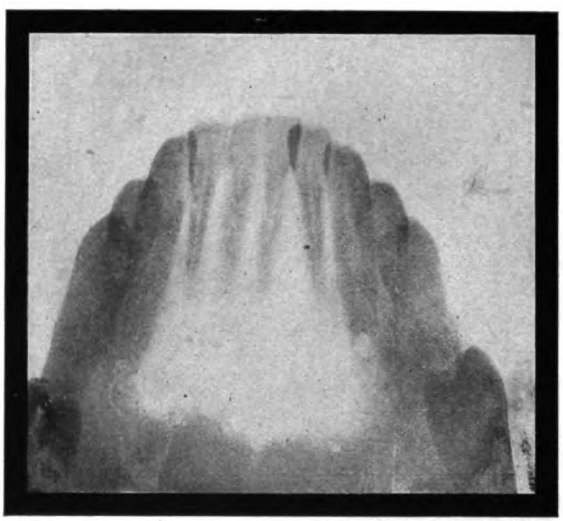

Fig. 256. Bone cyst of the lower jaw.

43. In Cases of Dentigerous Cyst.

Any cyst containing a tooth body, or tooth bodies, is said to be a dentigerous cyst. Dentigerous cyst of the jaws are not uncommon. Their definite diagnosis is possible only when the radiograph is used.

Because the apex of the tooth extends into the pus sac a chronic dento-alveolar abscess is sometimes called a dentigerous cyst. But this use of the term is considered improper.

Fig. 257. Case in the practice of Dr. M. H. Cryer. I quote Dr. Cryer: "The patient, a child of nine, had a swelling of the left side of jaw for about two years. This gradually increased to the size of a hen's egg, causing considerable deformity. A radiograph of the case (Fig. 257) shows a retained de-

Fig. 257. Dentigerous cyst of the lower jaw in child nine years old. The arrow points to the tooth in the cyst. The light area represents the cyst. (Radiograph by Pancoast, of Philadelphia.)

ciduous second molar tooth at the lower border of the jaw and surrounded by an ovoid clear area. A diagnosis of dentigerous cyst was made.

"At operation through the mouth the shell of bone was found to contain, not the usual fluid, but a resilient mass of pinkish-white tissue surrounded by a sac of darker color. The contents, including the soft tissues, the tooth shown in the picture and the sac, were removed and the cavity lightly packed with gauze. The patient is making an uneventful recovery. The further diagnosis of the case will depend on microscopic examination of the tissue."

Figs. 258 and 259.

Fig. 258 was made for a patient of Dr. J. G. Lane, of Philadelphia. Age of patient, eight. The radiograph shows an unerupted second bicuspid surrounded by a light area representing a dentigerous cyst. The upper wall

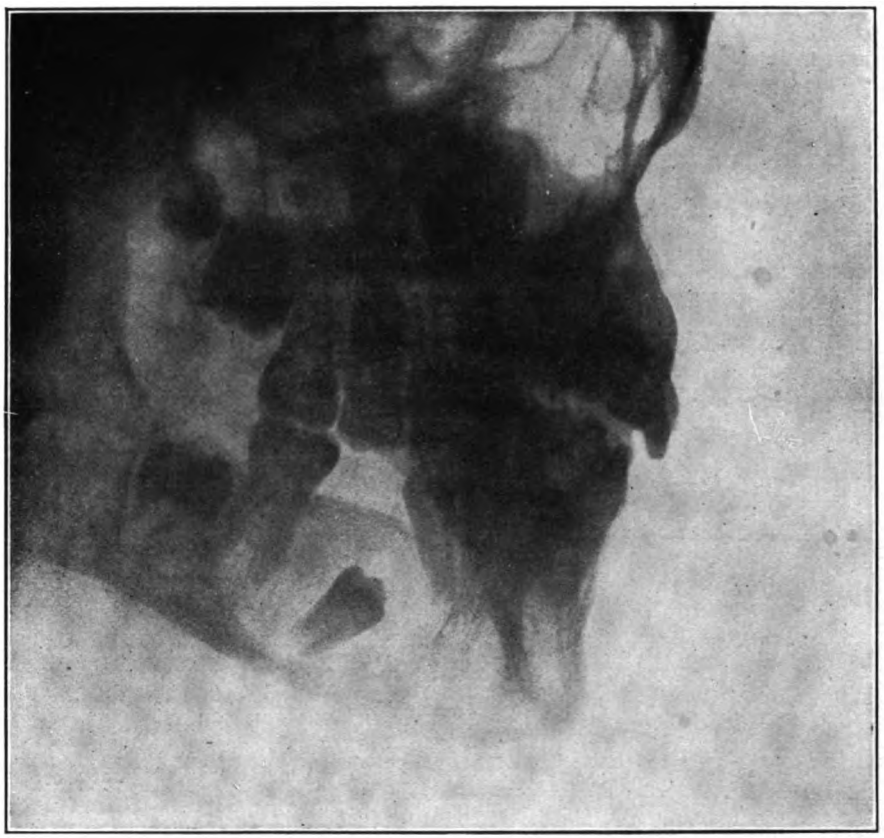

Fig. 258. A dentigerous cyst containing a lower second bicuspid. (Radiograph by Pancoast, of Philadelphia.)

of the cyst and its fluid contents were removed, leaving the tooth in place. A later radiograph (Fig. 259) shows that the tooth is gradually erupting into position. (This history is quoted from a paper by Dr. Cryer.)

44. In Cases of Tumor, Benign or Malignant.

I have already reported a case of cystic tumor, which was referred to the college clinic to have the tumor "cut off." There was nothing to "cut off," and a radiograph showed a cavity in the bone, aspiration of which accomplished a cure.

Fig. 260.

The following cases occurred in the practice of Dr. Cryer: "The two patients were sent by different practitioners from different portions of the State of

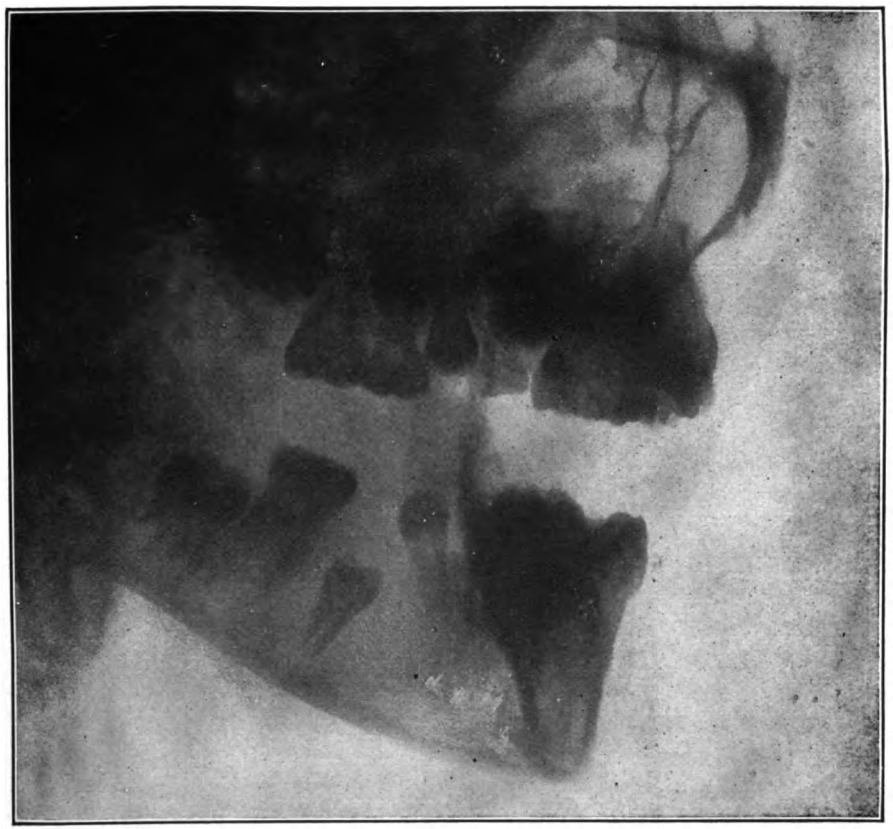

Fig. 259. Same as Fig. 258 after removal of the fluid contents and upper wall of the cyst, showing the second bicuspid erupting into place. (Radiograph by Pancoast, of Philadelphia.)

Pennsylvania, but came for examination on the same day. They were two women patients of about the same age, both wearing full upper artificial dentures and partial lower ones, and both suffering from a similar character of pain, the only difference being that in one patient the pain was located on the left side of the lower jaw, while the other was on the right side of the lower jaw. Physical examination revealed the fact that the right cervical lymphatic glands in one of the patients were slightly enlarged. The history obtained of the cases did not aid in diagnosis. Both patients claimed that the molar teeth on each side had been extracted years ago. X-rays were made of the jaws with the following results:

"Fig. 260 was made from the patient whose cervical glands were

Fig. 260. Myelosarcoma of the lower jaw. In appearance it resembles a bone cyst somewhat. (Radiograph by Pancoast, of Philadelphia.)

enlarged. The picture shows a breaking down of the bone, with the two dark shadows indicating abnormal density of the bone in some portions. From this appearance, together with the slight enlargement of the glands, the case was diagnosed as myelosarcoma. A microscopic examination of the tissue removed, confirmed the diagnosis."

I do not reproduce the radiograph of the other case because the print I have is not clear enough to permit of a good halftone reproduction. The print before me shows fairly well three impacted lower teeth, one a rudimentary bicuspid, the others a second and third molar.

Dr. Cryer says: "There seemed to be very little difference in these two cases from the history and physical examination, but the wonderful work of the X-rays revealed a very great dissimilarity. On the one hand the skiagraph indicated the sad necessity of removing the entire right side of the jaw and submaxillary lymphatic glands, with the possibility of the disease returning, while in the other case the extraction of the three impacted teeth was the only thing required."

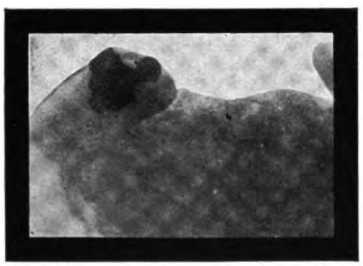

Fig. 261.

Fig. 262.

Fig. 261. Osteoma (?) of the lower jaw.

Fig. 262. Hypertrophy of the gums and alveolar process. The radiograph shows no irritant cause for the condition, and none was found otherwise.

Fig. 261. My readers are by this time acquainted with the appearance of normal alveolar process and jaw bone. Fig. 261 shows what I believe to be an osteoma. The patient would not consent to the removal of tissue for microscopical examination. The radiograph shows only that the bone is diseased. The exact nature of the disease must be determined by the microscope.

Fig. 262. Case: Enlargement of the gums about the upper anterior teeth, causing considerable disfigurement. Fig. 262 shows what was thought to be hypertrophy of the gum tissue and alveolar tissue. Microscopic examination verified the diagnosis. The teeth and the hypertrophied tissue were removed.

Fig. 263. At the age of thirteen a permanent lateral had failed to erupt. A radiograph was made to learn whether or not it was present in the jaw. Fig. 263 shows the permanent lateral, and shows also why it has not erupted. In

the path of eruption is seen what I believe to be an "epithelial, composite"* odontoma.

Odontomata sometimes assume considerable size. To be absolutely sure in diagnosis, and to be certain of their complete removal, the radiograph should be used.

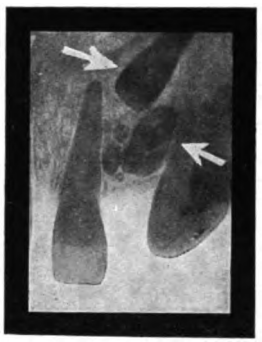

Fig. 263. The upper arrow points to the permanent lateral incisor. The lower arrow points to an odontoma. (Radiograph by Flint, of Pittsburgh.)

Fig. 264.

"The case illustrated in Fig. 264 presents many interesting features from the standpoint of diagnosis and treatment. The patient was a woman about thirty-five years of age, who suffered for a number of years from pains in the ear and the tonsilar region, as well as from difficulty in mastication and deglutition, while her general health had deteriorated to such an extent that she became very anemic, having suffered from malnutrition due, no doubt, to imperfect mastication and the absorption of pus products. In this condition she was referred to the extracting specialist who was unable, from the ankylosis present, to arrive at any definite conclusion as to the possibility of an impacted tooth which was suspected, while the only evidence that pointed in this direction was a free discharge of pus through a fistulous opening in the soft tissues over the third molar region of the right inferior maxillary.

"She was therefore referred to the radiographer when the true condition, as shown in Fig. 264, was revealed. The necessity for removing the displaced second molar, as well as the odontoma, presented a situation which was not a pleasing one to contemplate. The patient, as well as her friends, were informed of the probability of fracturing the mandible in the endeavor to remove the molar and the dental tumor, which together

*Barrett "Oral Pathology and Practice."

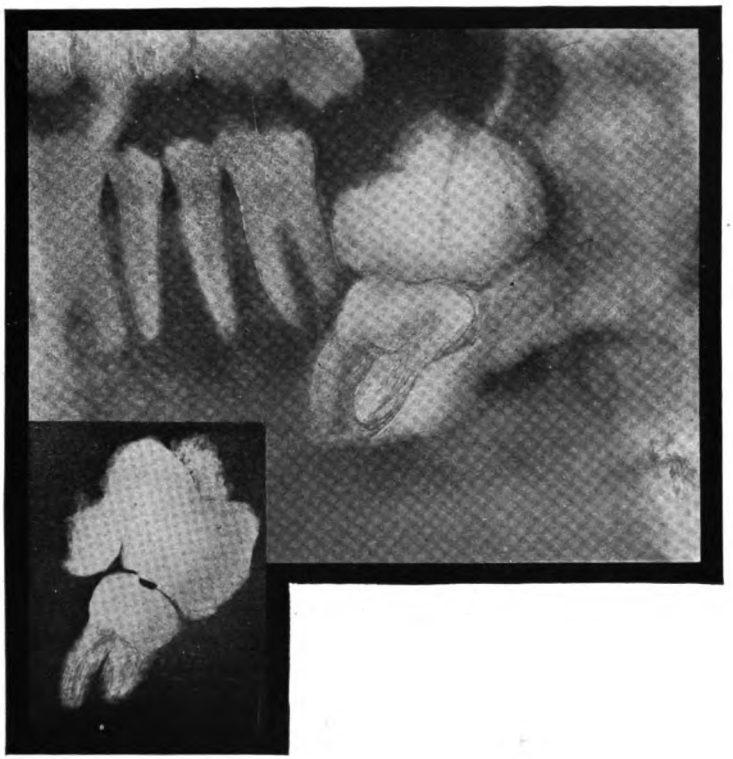

Fig. 264. A large composite odontoma. (Radiograph by Chene, of Detroit.)

occupied almost the entire body of the mandible at the angle of the ramus. Under a general anesthetic of nitrous oxide and oxygen, which was followed by ether, the tumor was removed, as was also the impacted molar, without any great difficulty, but when the circumscribed bony structure about the molar was drilled and chiseled sufficiently to permit of an elevator passing under one corner of it and pressure applied, the expected happened, and a break in the body of the mandible occurred. This accident was of no serious consequence, however, for under an occipitomental bandage, which a few days later was reinforced by wire fixation, the fracture healed and the case proceeded to an uneventful and speedy recovery, with complete restoration of health. The odontoma was of composite structure, the central part being made up of what may have been the third molar, about which were arranged concentric layers of cementum, and probably some compact bony structures."

For the report of this case I am indebted to Dr. Don M. Graham, of Detroit, Mich.

45. To Observe Anomalous Conditions Such as the Fusion of the Roots of Two Teeth for Example.

Fig. 265.

Case: Child about twelve. The crowns of two of the lower incisors seemed fused together. To accomplish regulation of the teeth it became expedient in the opinion of the operator handling the case to extract one of the

Fig. 265. Shows that the two lower incisors are not fused together.

incisors. The choice of the tooth to extract fell to one of the two which seemed fused together. The question arose: "Are the roots of the teeth fused also?" A radiograph (Fig. 265) shows they are not. It shows further that the crowns are not fused either, though, let me admit, I shared in the mistake of the man who referred the case thinking they were; and failed, as he had, in an attempt to pass a ligature between them. It was not until I had the radiograph before me, showing me that I was not attempting the impossible, that I succeeded in getting a silk ligature between the teeth. One of the teeth was slightly malformed; they were almost mortised together in consequence, and in contact from the incisal edge to beneath the gum margin.

Second and third molars are sometimes fused together. I recall having extracted the upper second and third molars in an effort to remove the third, the roots of the two teeth having been coalesced. Had I used radiographs, and known the condition which existed, I might have conserved the third molar, and so saved the second molar, which latter was a useful tooth. Or, had it been necessary to remove the teeth, I might have saved my patient considerable pain by a more inclusive use of my local anesthetic.

46. To Observe the Location and Extent of a Necrotic or Carious Condition of Bone.

Fig. 266. This radiograph is of a case of arsenical necrosis, which would not yield to the usual treatment of curettement and drug stimulation. The arrow points to the line of demarcation, below which can be seen the sequestrum. The case recovered promptly upon removal of the sequestrum.

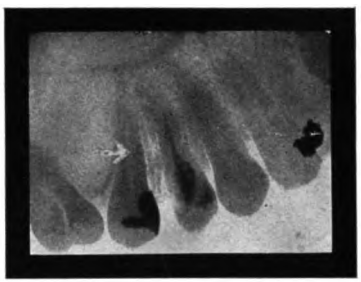

Fig. 266. The arrow points to the line of demarcation, beneath which can be seen the sequestrum.

Figs. 267 and 268. Case: Necrosis of the lower jaw, caused by an abscessed tooth. The patient suffered for a year from recurrence of an abscess in the lower jaw. During this time he made several changes from one dentist or physician to another. At the time the case came under the care of Dr. Gilmer, of Chicago, the symptoms were alarming. There were two external pus sinuses along the lower border of the mandible in the bicuspid region. The patient had been unable to lie down for a period of ten days because of the intense pain which resulted from assuming a recumbent position. The body temperature rose and fell by turns. Stupor and coma occurred.

A radiograph of the case (Fig. 267) shows a sequestrum about the size of the first joint of the thumb along the lower border of the mandible in the bicuspid and cuspid region. The line of demarcation can be seen fairly well in the plate before me. I regret that I was unable to obtain a good print of this case. The negative was an excellent one, but the photographer who made the print from it did poor work.

The operation, done by Dr. Gilmer, of Chicago, was as follows: An external incision was made along the lower border of the mandible in the region of the sequestrum, and the sequestrum removed through it. The bone was curetted, a drainage tube inserted, and the incision sewed up. The first bicuspid and cuspid were extracted.

Fig. 267. The arrow points to a sequestrum about the size of the first joint of the thumb. (Radiograph by Porter, of Chicago.)

Fig. 268. Same as Fig. 267, with the line of demarcation outlined to enable the reader to observe it better than in Fig. 267.

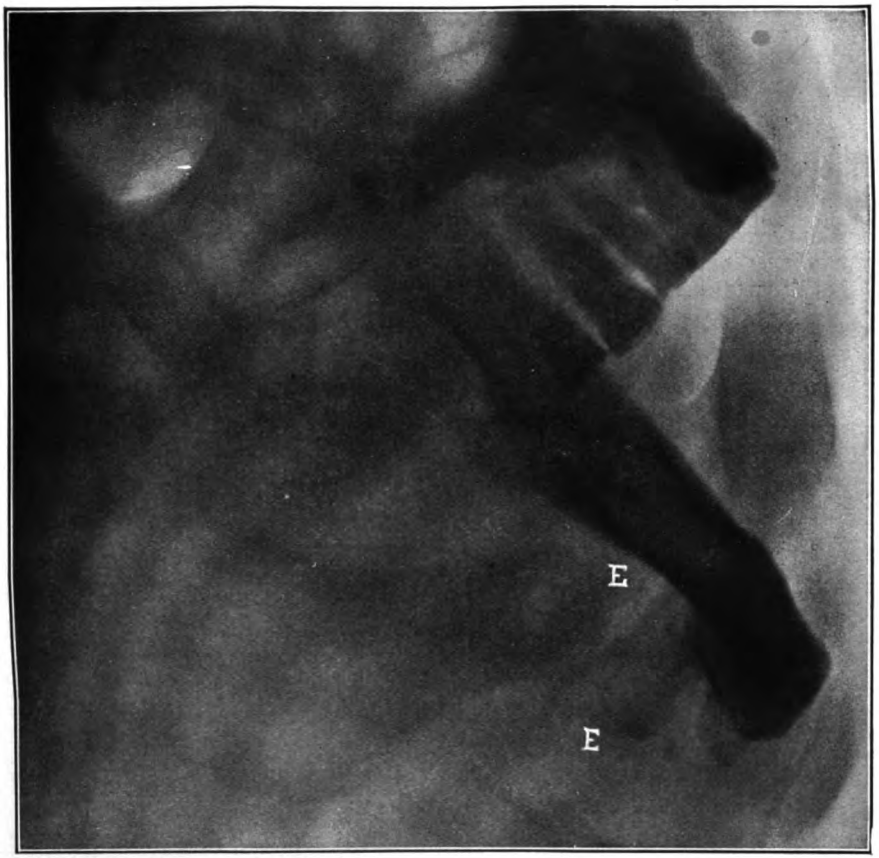

Fig. 269. EE, ends of overlapping bone.

Had the operator not had a radiograph to guide him in his work he could not possibly have performed the operation as quickly, thoroughly, and intelligently as he did, for he would not have known just where, and just how big, the sequestrum was.

Fig. 269. A case of phosphor necrosis of the lower jaw several years after removal of the sequestrum. The jaw is in two parts, with the ends overlapping.

Fig. 270. A carious condition of the alveolar process and superior maxillary bone, caused by the retention of a piece of tooth root above the dummies of a bridge.

47. To Diagnose Antral Empyema.

Fig. 271. This radiograph was made from a dry skull. It shows the following: The frontal sinuses AA, the orbits BB, ethmoid cells CC, the nasal cavity DD, and the maxillary sinuses EF. The sinus E is filled with lead shot, the sinus F has a molar tooth in it. The picture is printed to give one an opportunity to study the "landmarks" of such a radiograph, and so enable one to interpret the coming pictures more readily.

Fig. 270. Carious condition of the alveolar process and bone, caused by a piece of tooth root above the dummies of a bridge. (Radiograph by Lewis.)

Fig. 272. To observe pus in the antrum it is necessary to make a radiograph of both antra, that they may be compared. In Fig. *272* the antrum A is filled with pus, the antrum B is healthy. It must be borne in mind that the radiograph alone does not demonstrate to us the presence of *pus* in the antrum. It shows us only that there is *something* in the antrum. The appearance of the radiograph would be about the same, whether that something were pus or a soft, tumorous growth. Such a radiograph as Fig. *272* will show whether the disease is confined to the antrum or involves the ethmoidal cells and frontal sinuses. In this case the disease exists only in the antrum.

Figs. 273 and 274. Cloudiness of the antrum A indicates a pathological condition. In Fig. *273* the arrows point to a dark shadow, which is an impacted upper third molar tooth. Fig. *274* is a lateral view of the same case, and shows the impacted tooth clearly. Extraction of the tooth effected an immediate cure. (This case was one in the practice of Dr. Cryer.)

48. To Observe the Size, Shape and Location of the Antrum, as an Aid in Opening into It.

Fig. 275. Unless a pus-filled antrum is opened at its lowest point, it cannot be perfectly drained. Unless it is perfectly drained the operation cannot result

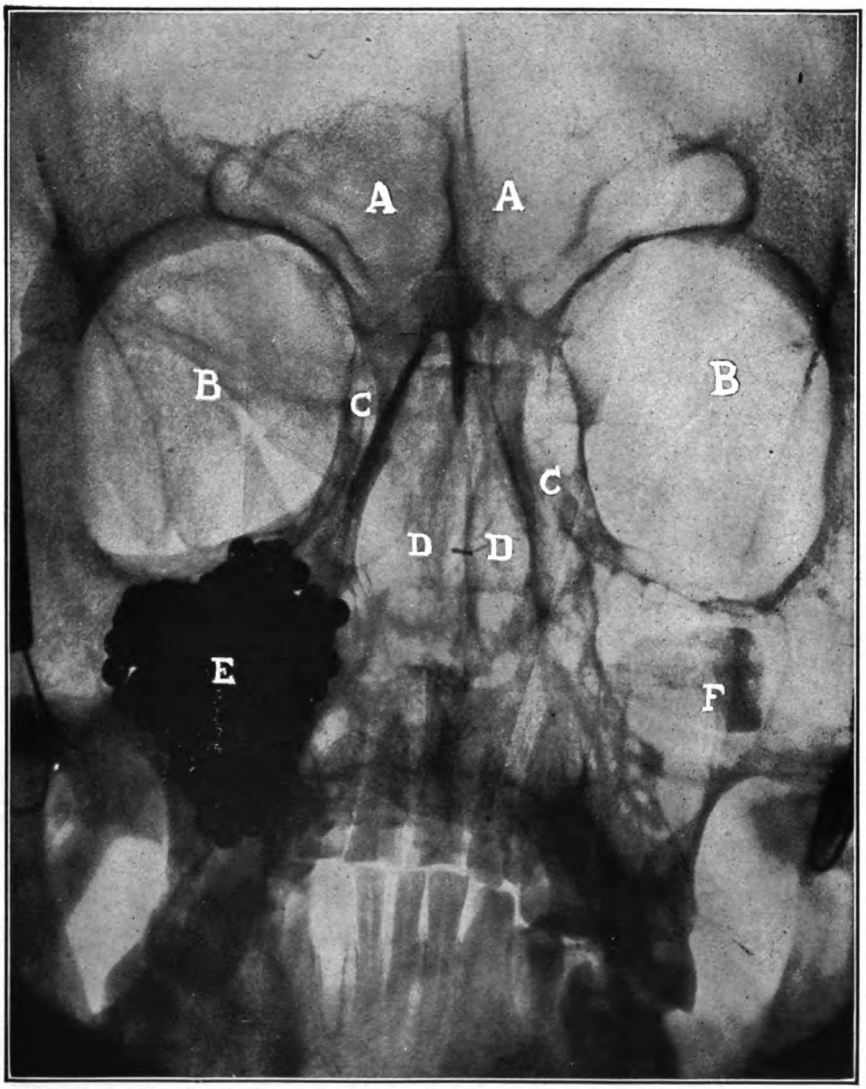

Fig. 271. Radiograph of a dry skull. One antrum is filled with lead shot, the other has a molar tooth in it. This radiograph is clearer than one made from the living subject because there were no soft parts or circulating blood to blot out detail.

in a permanent cure. The size, shape and location of the antrum can best be observed stereoptically. Often, however, a good idea of its size, shape and location can be obtained from a radiograph, like Fig. 276, for example. Radiographs of the antrum made on films held in the mouth

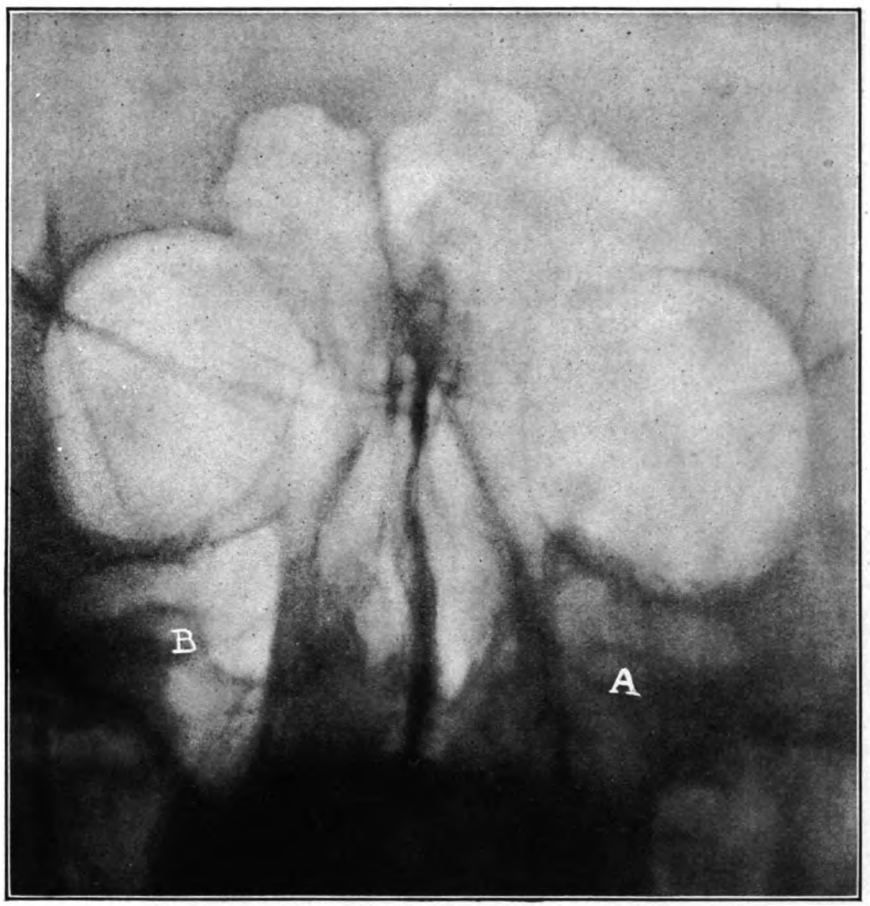

Fig. 272. A, antrum with pus in it. B, healthy antrum. (Radiograph by Carman, of St. Louis.)

are very misleading and confusing, as witnessed in Fig. 275, which was made on a film held in the mouth, and is of the antrum filled with lead shot—illustrated in Fig. 271.

Fig. 276.

The dots outline a very large antrum. An opening made at the favorite site for opening into the antrum through the mouth, above their apices, between the second bicuspid and first molar (the first molar has been extracted), would not puncture this antrum at its lowest point. The root of the second molar seems to penetrate the antrum. Whether it actually penetrates the floor of the antrum or not I cannot say definitely, because

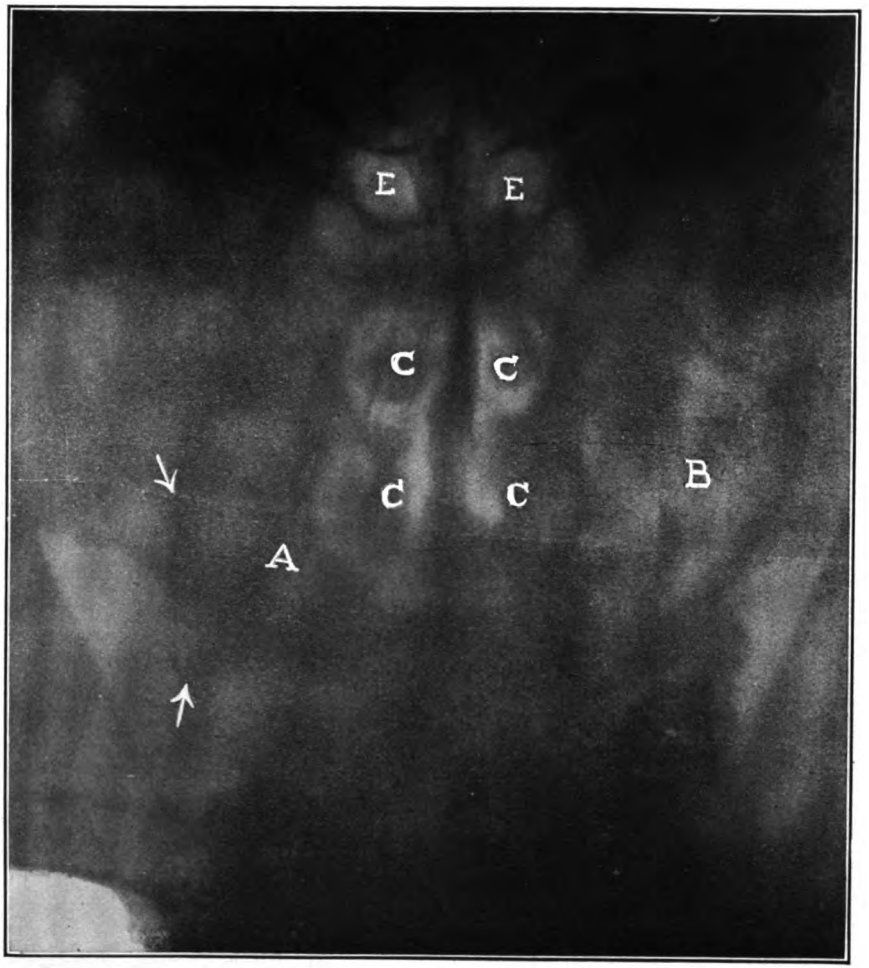

Fig. 273. A, diseased antrum. The shadow pointed to by the arrows is an impacted third molar. B, healthy antrum, CC, turbinate bones, EE, very small frontal sinuses. (Radiograph by Pfahler of Philadelphia.)

of the lack of perspective in the radiograph. I am inclined to think, however, that it does not—the lower part of the antrum and the end of the root overlap, the tooth root passing to the lingual of the antrum.

Because of its unusual size the lower part of the antrum was thought to contain a malignant growth. Dr. Cryer rejected this interpretation, saying that the antrum must have been of the size shown in the radiograph before the formation of the second and third molars, and that the large antrum was responsible for the pinched-together condition of their

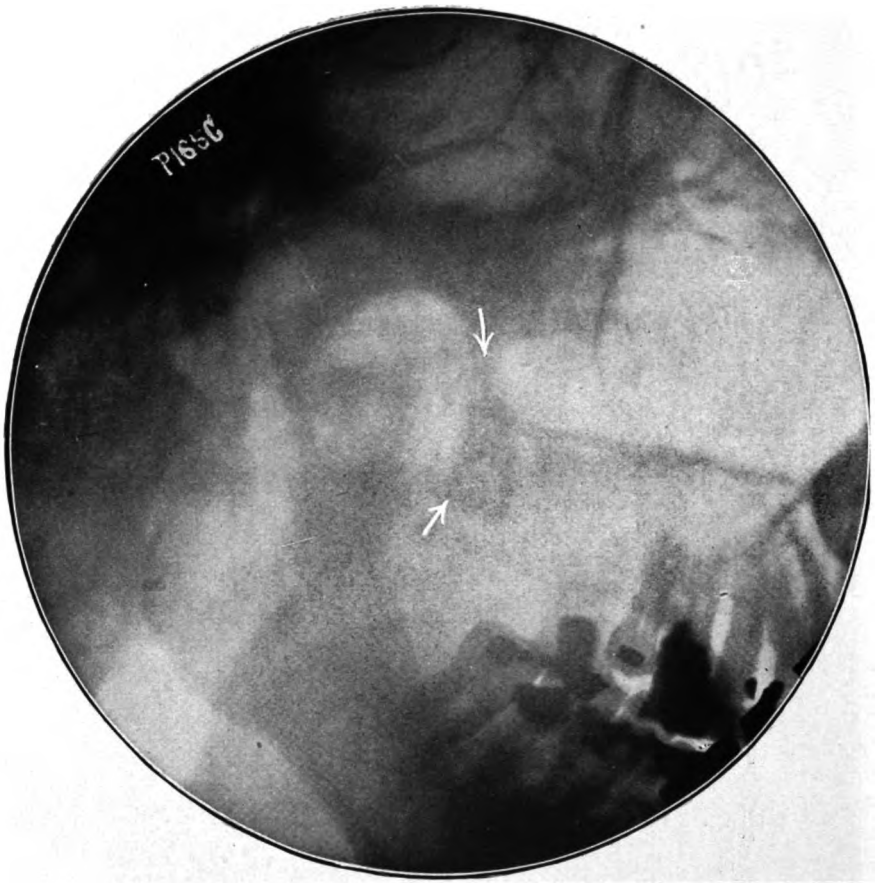

Fig. 274. Lateral view of the same case illustrated in Fig. 273. This radiograph shows the impacted tooth clearly. (Radiograph by Pfahler of Philadelphia.)

roots. He theorized further, accounting for the pain the patient suffered by surmising that the pinched condition of the roots of the third molar was causing pressure on the dental pulp. In his description of the case Dr. Cryer does not mention the faulty canal filling in the second molar as a possible cause for the pain. Both molar teeth were extracted and the patient was freed from neuralgia.

49. To Locate Foreign Bodies, Such as Tooth Roots or Broaches, in the Antrum.

Figs. 277 and 278.

Fig. 277 shows a piece of tooth root in the antrum. It is a portion of the second bicuspid, which had been extracted (?) about a week previous to the time when the patient presented to Dr. Virgil Loeb for treatment. The

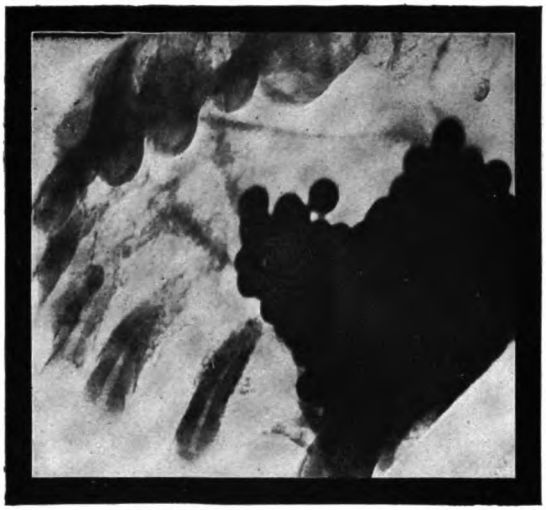

Fig. 275. Antrum filled with lead shot. The same as Fig. 271.

Fig. 276. The dots outline a very large antrum. (Radiograph by Pfahler, of Philadelphia.)

Fig. 277. The arrows point to a piece of tooth root in the antrum. (Radiograph by Carman, of St. Louis.)

first molar was extracted, an opening made into the antrum through one of its alveoli, and the piece of root removed. The object of the operation was to remove the piece of tooth root from the antrum. This was accomplished. And again let me repeat what I have said before: An operator may make a greater mistake than that of the extraction of a tooth—he may conserve the tooth at the expense of the health and happiness of the patient. Conservative dentistry often, all too often, means conservation of disease.

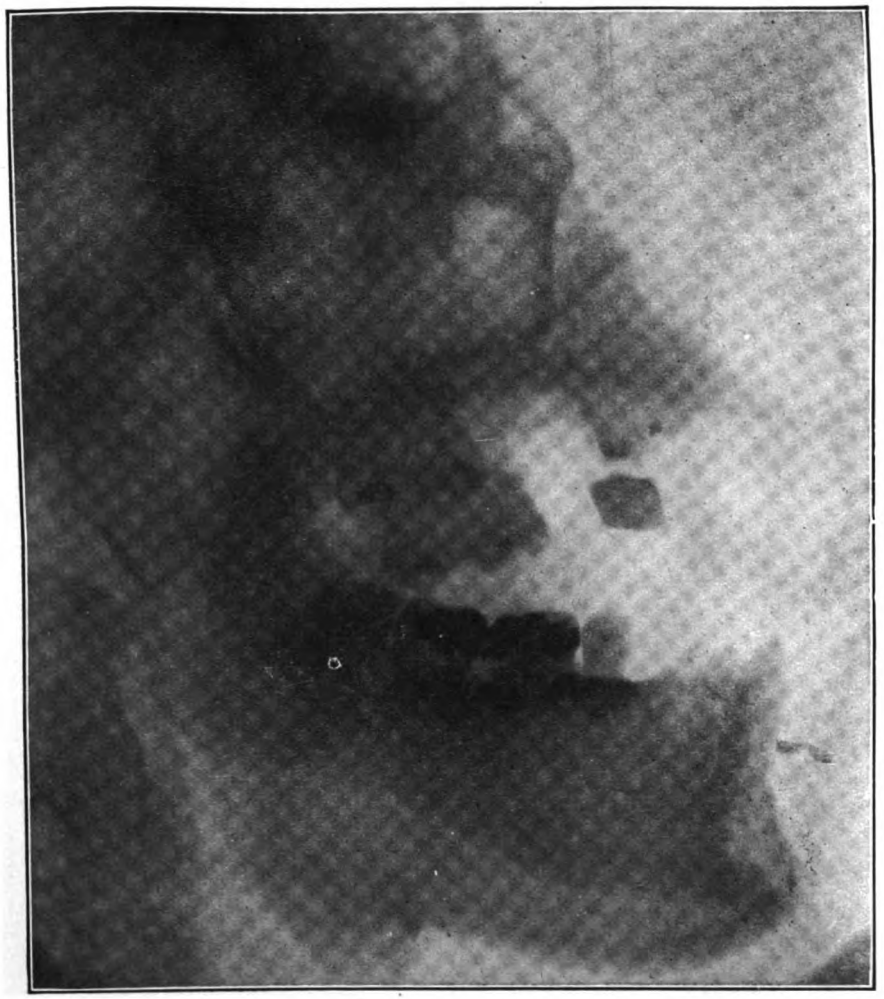

Fig. 278. Same case as Fig. 277 after removal of the piece of tooth root. (Radiograph by Carman, of St. Louis.)

Fig. 279.

Dr. Cryer says of Fig. 279: "It is made from a patient who had trouble in the maxillary sinus for some time. The picture demonstrated that a piece of rubber tubing, which had been used for drainage, had slipped into the antrum and become lodged in the region of the ostium maxillare. After its removal and a brief treatment, the part became well."

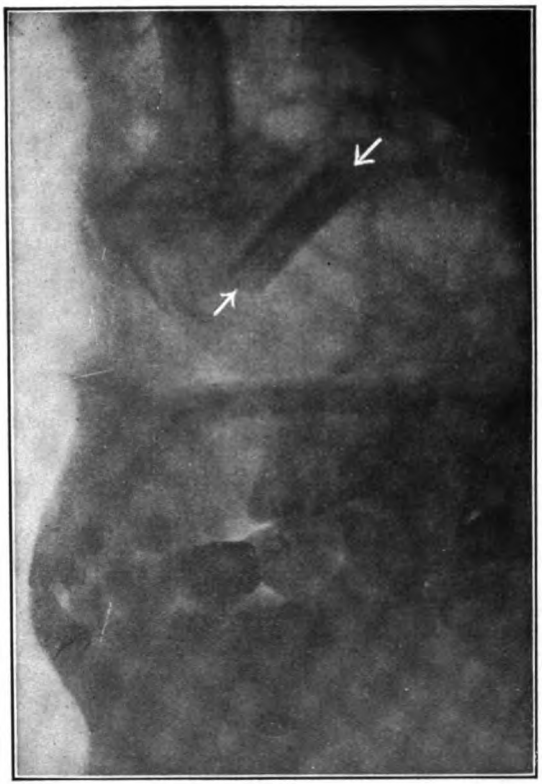

Fig. 279. The arrows point to a piece of rubber tubing in the antrum. (Radiograph by Pancoast, of Philadelphia.)

50. To Observe Cases of Luxation Before and After Reduction.

Figs. 280 and 281. The symptoms of dislocation of the condyle from the glenoid fossa are so characteristic that, it seems to me, even the most inexperienced should recognize them with ease. It is a fact, however, that the case illustrated in Figs. 280 and 281 was diagnosed dislocation, because I presume the patient could not get the anterior teeth together. The radiographs show two fractures. Fig. 280 near the angle, and Fig. 281, of the other side of the jaw, in the second bicuspid region.

Fig. 282. This radiograph is by Tousey, of New York City, and is one of the clearest radiographs of the temporo-mandibular articulation I have ever seen made from a living subject.

Fig. 280. The arrows point to a fracture of the jaw in the region of the angle. (Radiograph by Cole and Raper.)

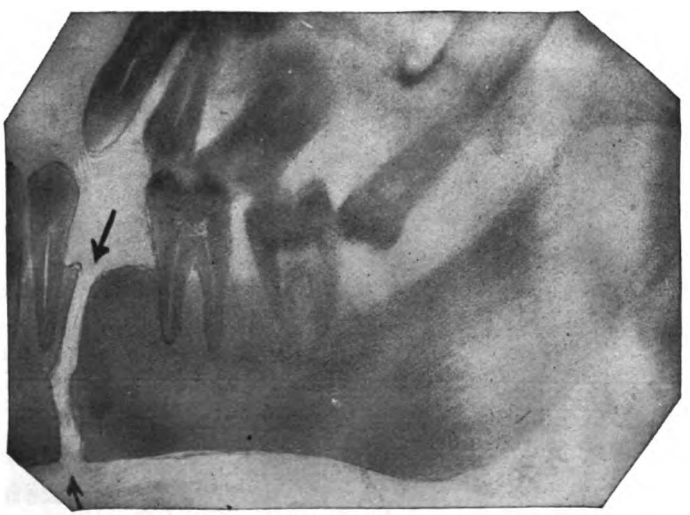

Fig. 281. The arrows point to a fracture of the lower jaw just posterior to the second bicuspid. The opposite side of the same jaw radiographed in Fig. 280. (Radiograph grossly retouched) (Radiograph by Cole and Raper.)

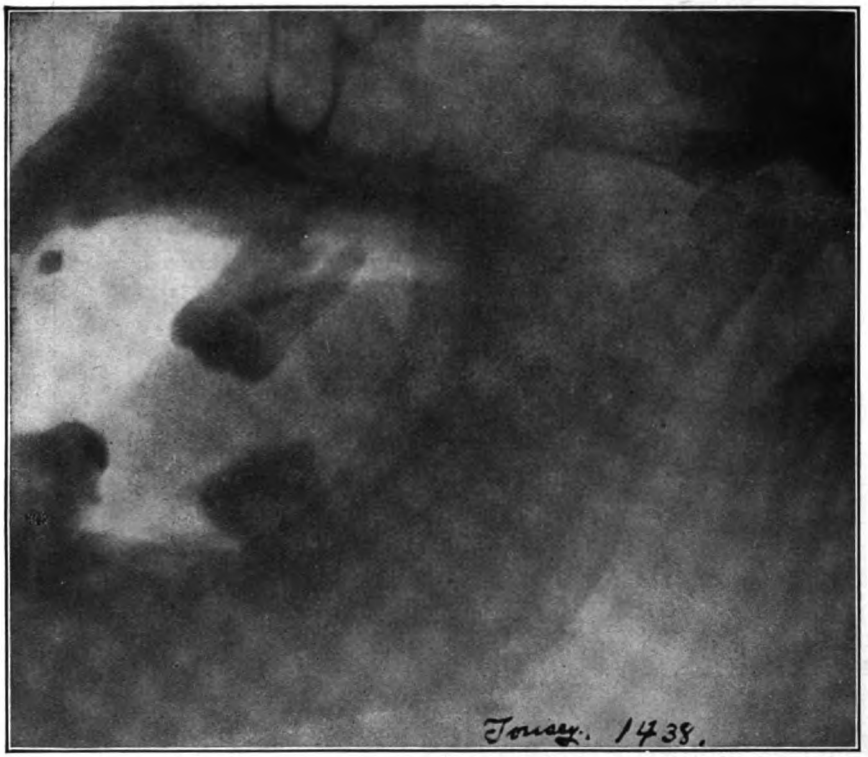

Fig. 282. Excellent radiograph of the temporo-mandibular articulation. Made from a living subject. (Radiograph by Tousey, of New York City.)

Figs. 283 and 284. Case: Dislocation of the condyle from the glenoid fossa. Fig. 283 shows the condyle A anterior to the *eminentia articularis* B. Fig. 284 of the same case after reduction. While it fails to show the condyle itself clearly, it shows the neck of the condyle and demonstrates that, in this picture, the condyle A is on the other side of the *eminentia articularis* B.

81. In Cases of Fracture of the Jaw.

Fracture of the jaw is almost always accompanied by such a great deal of swelling and induration that digital and ocular examination are highly unsatisfactory. The operator who treats a fracture should know just where and what kind of a fracture he is dealing with. If there be displacement of the fragments, he must know how much, and in what direction, the displacement occurs, in order that he may properly readjust the parts. This knowledge can be gained only by the use of radiographs—

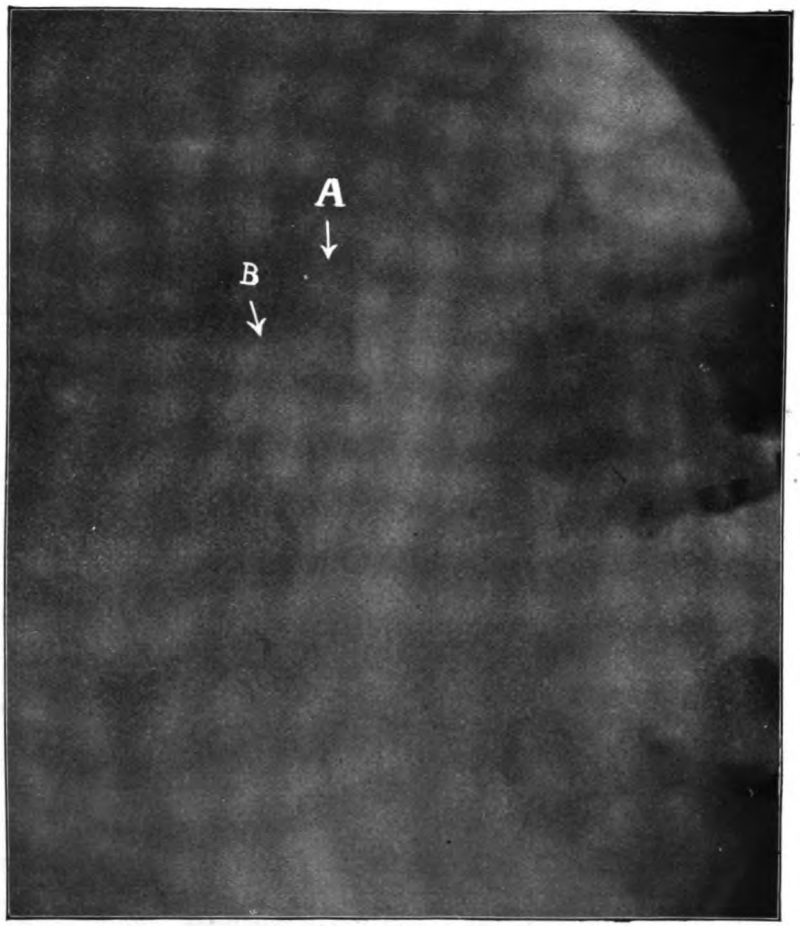

Fig. 283. Dislocation of the condyle from the glenoid fossa. A, condyle. B, eminentia articularis. (Radiograph by Cole and Raper.)

stereoscopic radiographs preferably in cases where there is considerable displacement of the fragments.

Fig. 285. Fracture at the symphysis. The appliance on the teeth is being used as a splint.

Figs. 286 and 287. Case in the practice of Dr. Cryer. Fig. 286 shows a fracture of the mandible at the angle. The body of the jaw is displaced downward. Fig. 287 is of the same case after reduction and adjustment of an interdental splint. While the apposition of the fractured ends is not perfect yet, there is a

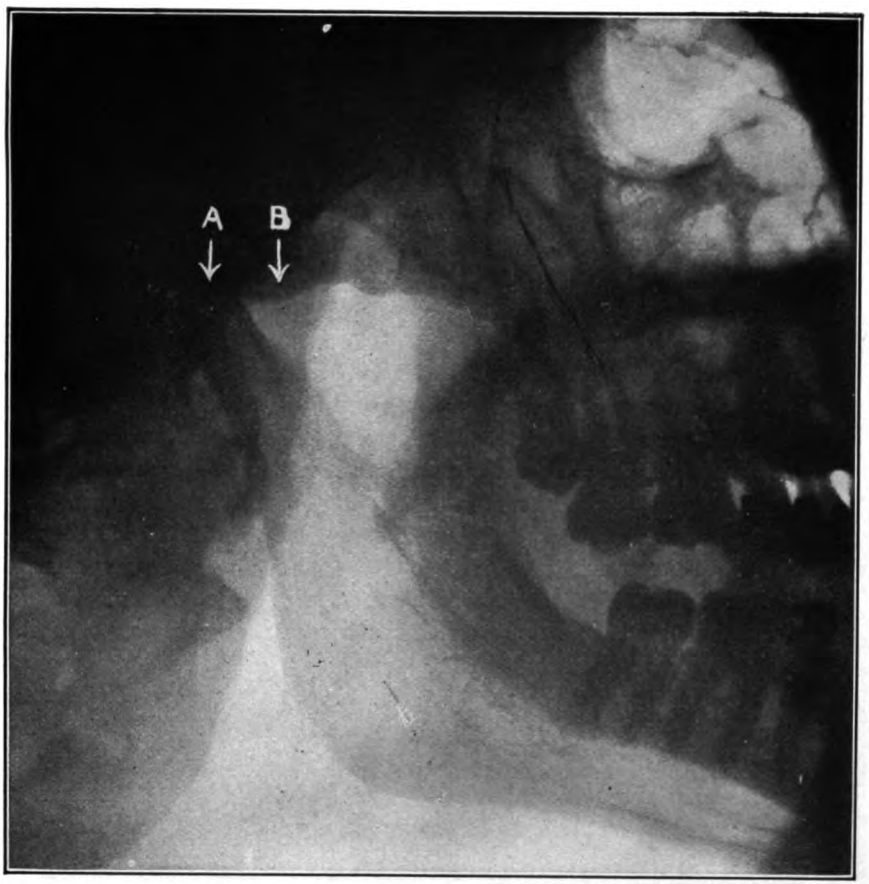

Fig. 284. Same as Fig. 283 after reduction of the dislocation. A, condyle. B, eminentia articularis. (Radiograph by Cole and Raper.)

very great improvement over the condition showed in Fig. 286, and I believe the apposition to be as near perfection as human ingenuity is capable of carrying it.

Just when to remove a splint and bandage from a fracture case is always a problem. The splint shown in Fig. 287 was removed at the end of the eighth week. Dr. Loeb, of St. Louis, Mo., states that radiographs are a great aid in determining just when to remove splints.

Fig. 288. A double, comminuted fracture of the mandible four months after the accident. The bone in the region of the fracture is necrotic.

52. In Cases of Ankylosis of the Temporo-Mandibular Articulation or the Joint Formed by the Tooth in the Jaw.

The radiograph is of value in cases of ankylosis to observe the cause of the ankylosis.

Fig. 289.

Case: A miner who had sustained a traumatism resulting in ankylosis. The ankylosis had existed for several months at the time Fig. 289 was made. The dots outline the missing parts, *i.e.*, the anterior border of the ramus and

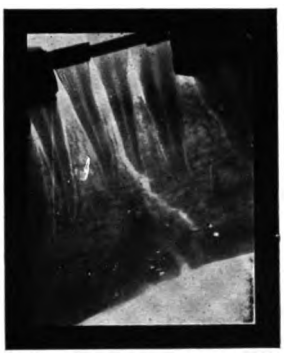

Fig. 285. Fracture of the mandible at the symphysis. (Radiograph by Blum, of New York City.)

the coronoid process. The disease of the bone could not have failed to affect the temporal and masseter muscles. It is my belief that in this case the true muscular tissue was destroyed and replaced with cicatricial tissue, which condition caused a false ankylosis. I consulted two surgeons, but neither was able to suggest a corrective operation.

An orthodontist was unable to move a tooth into proper occlusion. He referred the case to me, thinking perhaps the presence of a supernumerary tooth body was responsible for the immobility of the tooth. A radiograph demonstrated the absence of any such body, and showed that the tooth had practically no peridental membrane at all. There was a condition of partial ankylosis, to overcome which it was necessary for the orthodontist to reinforce his anchorage and exert more force on the refractory tooth. I do not print a radiograph of this case because of the great difficulty of showing the peridental membrane, or the absence of it, in a half tone.

53. To Observe the Field of Operation before and after Resection of the Mandible.

Resection of the mandible is a difficult, radical operation, and one which has been performed comparatively few times. With the exception of Dr. Ballin (*Items of Interest*, June, 1908), operators who have done this operation have not, so far as I am able to learn, availed them-

Fig. 286. Fracture at the angle of the mandible. Displacement of fractured ends. (Radiograph by Pancoast, of Philadelphia.)

Fig. 287. The same as Fig. 286 after reduction and adjustment of an interdental splint. (Radiograph by Pancoast, of Philadelphia.)

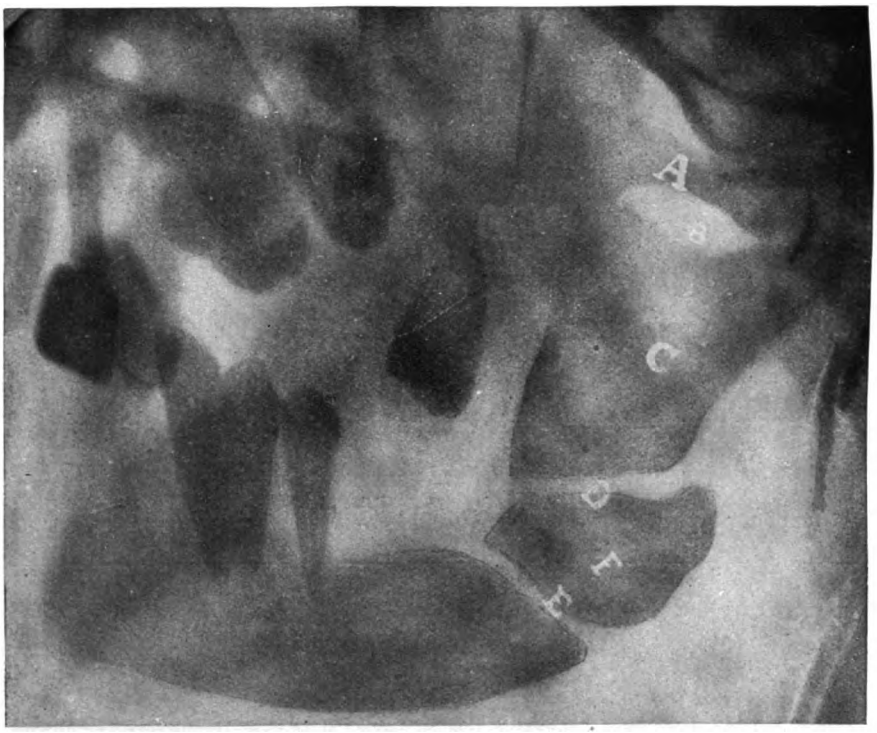

Fig. 288. Double comminuted fracture of the mandible. That the reader may understand the picture, observe the following: A, zygomatic arch; B, sigmoid notch; C, upper part of ramus; D, one fracture; E, the other fracture; F, fragment of bone between fractures. (Radiograph grossly retouched.)

selves of the assistance which good radiographs of the case would have rendered. Resection of the mandible might become necessary as a result of an existing pathological condition of the bone, or it might be done to correct a bad case of prognathism. For whatever reason the operation may be done, the operation itself is the same, in that a piece of the mandible is removed. Consider the operation for prognathism, for example: A piece of the body of the mandible from each side is cut out and removed. The anterior part is then forced back and the cut ends of the bone (four of them) wired into apposition. That anti- and post-operative radiographs of such a case would be of value is apparent.

54. In All Cases of Facial Neuralgia with an Obscure Etiology.

Cases of facial neuralgia with an obscure etiology, the exciting cause for which was disclosed by the radiograph, have already been described under more specific headings—Figs. 159, 164, 176, 177, 179, 224, 250, 264, and others. Until the exciting cause is found, when it then receives a more specific name, any dental pain is likely to be referred to as neuralgia.

When making radiographs to learn the cause of trifacial neuralgia, it is expedient usually to make a large plate picture of the affected side. This radiograph can then be studied and, if some lesion is discovered, another radiograph of the particular region of the lesion made on a small film. The second radiograph, on the film, will be clearer than the one on the plate, and will verify or disprove the findings in the larger picture.

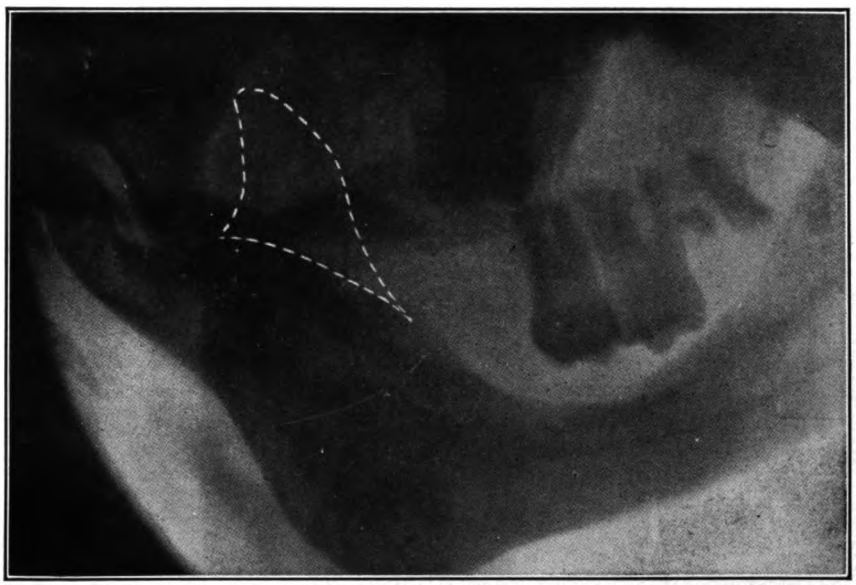

Fig. 289. The dots outline the missing parts—i.e., the anterior border of the ramus and the coronoid process. (Radiograph by Cole and Raper.)

Figs. 290 and 291. Case: Married woman, middle age, suffered from pains in the region of the upper bicuspids. The dentist could find no lesion that might be responsible for the trouble. A radiograph (Fig. 290) was made, but does not show the upper teeth clearly. It does, however, show a shadow in the body of the mandible in the region of the *lower* first molar, which tooth is missing from the jaw. A radiograph (Fig. 291) of the region in which the shadow appeared was made on a small film held in the mouth. The film was not placed in exactly the proper position and, as a result of this mistake, pictures only a part of the lesion. It shows the crown of a supernumerary lower bicuspid with three supernumerary bodies (denticles) above it. Though the lesion in the lower jaw was not at the location in which pain occurred, it was very likely responsible for the neuralgia.

The patient would not submit to an operation. The case, if not operated upon, will probably progress to a large dentigerous cystic tumor. Evidence of this can already be noticed in Fig. 290 by the lack of normal density of the surrounding bone.

Fig. 290. The arrow points to a shadow in the body of the mandible. (Radiograph by A. M. Cole, of Indianapolis.)

Fig. 292.

Case: Married woman, physician's wife, about forty-eight years old, had suffered for twenty-five or thirty years with attacks of neuralgia occurring four or five times a year, each attack lasting for several days. None save dental operations were performed, though she received palliative treatment for ear, mastoid cells and antrum trouble. No treatment gave relief. She left her home in Indiana and spent one winter in South Carolina, hoping the milder climate would ward off the attacks of pain, but this proved futile. At no time did her temperature rise above normal, prov-

ing, or seeming to prove, that whatever the irritation, there was little or no suppuration attending it. A radiograph (Fig. 292) was finally made, and showed an impacted upper third molar. This tooth was removed, and since then, now over four years ago, she has not had a single attack of neuralgia.

Attention is called to the fact that up to the time of making the radiograph this was a typical case of idiopathic facial neuralgia.

Fig. 291. The same case as Fig. 290. A radiograph of the upper part of "the shadow." It shows the crown of a supernumerary bicuspid with three denticles above it. The white spot at the apex of the second bicuspid is caused by an air "bell" attaching itself to the film in that region at the time it was in the developing solution. (Radiograph by A. M. Cole, of Indianapolis.)

55. To Observe the Inferior Dental Canal.

Often, but not always, we are able to radiograph the inferior dental canal. (See Fig. 190.) To the man contemplating resection of the inferior dental nerve anywhere throughout its course in this canal a radiograph showing the location of the canal would be of value.

Dr. Virgil Loeb, of St. Louis, reports a case of anesthesia of the lower lip, and that part of the face on one side which receives its nerve supply from the nerves passing through the mental foramen. The anesthesia followed the extraction of a lower third molar. A radiograph of the case showed that the roots of the third molar had penetrated the inferior dental canal. Knowing this, it was deduced that, at the time of extraction, the inferior dental nerve had been stretched, and a few fibers torn at the mental foramen. Lately I have personally observed such a case. I do not print radiographs of either Dr. Loeb's or my own case, because they are not clear enough to permit of good half-tone reproduction. Such cases as the ones now under consideration recover slowly, the time required varying from one to several months. Treatment with the high-frequency current may, or may not, hasten recovery slightly. Though slow, complete recovery may be expected.

Immediately after the filling of the canals of a lower second molar a patient suffered most severe pain in the region of the filled tooth. A radiograph was made and showed the canal filling penetrating the apical foramen of the distal root, projecting into the inferior dental canal, and

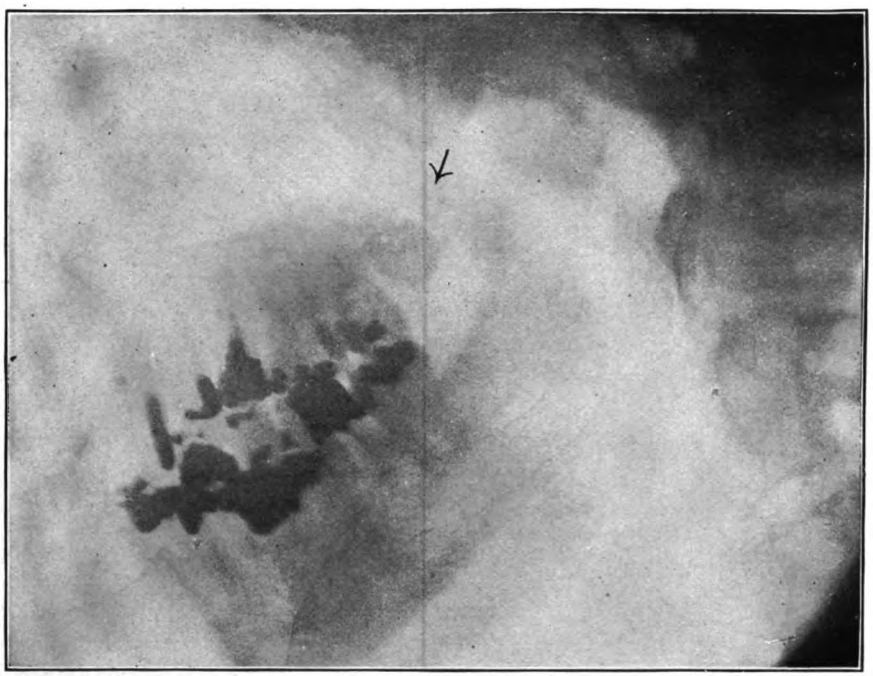

Fig. 292. The arrow points to an impacted upper, third molar, the cause of "idiopathic" neuralgia, from which the patient had suffered recurrently for from between twenty-five to thirty years. (Radiograph by A. M. Cole, of Indianapolis.)

doubtless pressing the inferior dental nerve. An effort to remove the canal filling met with failure, and the tooth was extracted to relieve the patient of the intense pain. Again I do not print radiographs of the case because the prints are not sufficiently clear to permit of good half-tone reproductions.

56. In Cases of Ludwig's Angina.

Angina is defined in Dorland's Medical Dictionary as "any disease or symptom characterized by spasmodic suffocative attacks"; Ludwig's angina as "purulent inflammation seated around the submaxillary gland." Whenever there is a pus sinus opening on the neck in the region of the submaxillary gland, the patient is said to have Ludwig's angina. This is the popular application of the term, and it seems to the writer unfor-

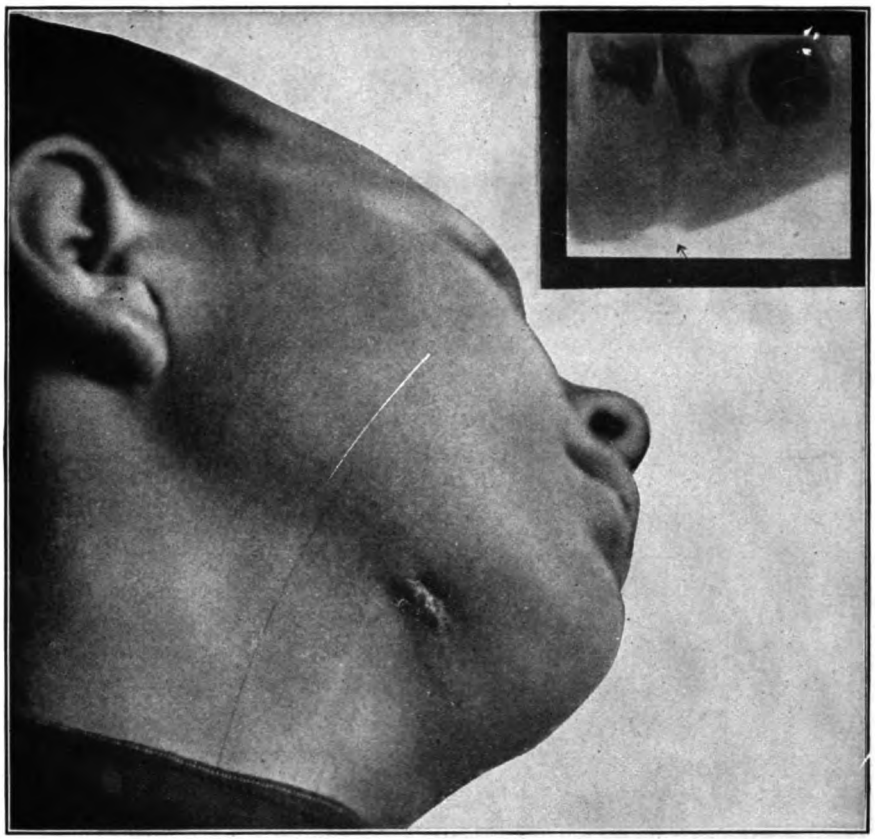

Fig. 293. Photograph of a case of so-called Ludwig's angina. Also a radiograph of the case showing an abscess of the first permanent molar. The fistulous tract cannot be seen.

tunate, for there is seldom angina—*i.e.*, suffocative attacks—in these cases of suppuration of the neck.

Fig. 293.

Fig. 293 is a photograph of a case of so-called Ludwig's angina occurring in a child ten years of age. The accompanying radiograph of this case shows an abscessed lower first molar, which was responsible for the sinus on the neck. The arrow points to a notch in the lower border of the body of the mandible. Extraction of the lower first molar and curettement of the alveoli was all that was necessary to effect a cure in this case. Had the patient been older, or not so vigorously healthful, the slightly necrotic area pointed to by the arrow would have required curettement through a facial opening. The radiograph happens to demonstrate the congenital absence of a lower second bicuspid.

Dr. H. R. Sparrevohn, of Los Angeles, reported a case of "Ludwig's Angina" in the June number of the *Dental Cosmos,* 1910. The patient was receiving hospital treatment for suppuration of the glands of the neck, when Dr. Sparrevohn examined the case, had radiographs made, and pronounced the trouble due to an impacted lower third molar, which could be seen clearly in the radiograph, and in appearance was similar to Fig. 159. Neither the patient nor the attending physicians could be convinced that his diagnosis was correct. (Had the fistula been injected with bismuth paste and a radiograph made there would have been no chance for dispute.) Dr. Sparrevohn closed his report of the case as follows: "I should be thankful to readers of the *Dental Cosmos* if they would express themselves as to the correctness of my diagnosis. At present I am much discredited, especially by the medical men connected with the case."

Dr. Herbert McIntosh, a physician, answered Dr. Sparrevohn in *Dental Cosmos,* October, 1910. He said in part: "I think there can be scarcely any doubt that the malposed molar, of which very good radiograms were presented, was the cause of the serious symptoms reported. Anyone who has had experience in the skiagraphing and observing of such cases would have no hesitation in suspecting dental irritation as the origin of the symptoms reported in the case. In general, the medical man is too apt to overlook the reflex irritation produced by the teeth. There is evident need of skiagraphy to clear up these obscurities of diagnosis in conditions of the face and cranium. There should likewise be a greater readiness to admit the importance which teeth have in producing pathological conditions of the tissues."

I believe I am safe in saying that about all of the cases of so-called Ludwig's angina are due to dental lesions. Yet, referring to no less than a dozen medical dictionaries and works on the practice of medicine, I find that none of them even mention the teeth as an etiological factor to be considered. These books state that the disease is caused by diphtheria, erysipelas, syphilis, tuberculosis, and that it occurs epidermically and idiopathically. It is therefore not surprising that Dr. Sparrevohn's diagnosis was discredited.

As is indicated by the remarks of Dr. McIntosh, many medical men are more enlightened than the authors of the books to which I have referred. But, on the other hand, many of our brothers in the practice of general medicine need education along this line. For example, a physician of my acquaintance, a specialist on the treatment of tuberculosis, treated, and treated without benefiting, a case quite similar in appearance to Fig. 293, giving the usual anti-tubercular treatment, including the administration of bacterine. The patient's mouth had *never* been examined

by a dentist, and radiographs of the case were not made, nor were either of these things done after I suggested them, because the physician thought it so highly improbable that the teeth could cause such a condition.

To illustrate the grave nature of the symptoms in some of these cases permit me to report the following case:

Young man, age twenty-three, suffered from what was diagnosed pharyngeal abscess. Confined to the house for a month, and lost thirty pounds. A change of physicians brought in a man on the faculty of the Indiana Dental College. It became necessary to make an external incision to permit the escape of a great quantity of pus. And let me say that because the incision was made on a line with, instead of at right angles to, the fibers of the muscle, the resultant scar is hardly noticeable. The writer was called in consultation. I did not do radiographic work, nor appreciate its importance at this time, or the doubt in my mind as to the correctness of my diagnosis might have been eliminated. The patient could not open the mouth, but instruments passed along the vestibule of the mouth came in contact with the corner of what I suspected to be an impacted lower third molar. The mouth was opened, the tooth found and removed, and the patient recovered immediately. The impacted tooth was not decayed.

The radiograph should be used in all such cases of suppuration about the face and neck.

Fig. 294. A very large abscess about the apices of the roots of the lower first molar. In facial fistula cases it is best to make a radiograph which will include the entire side of the jaw. I have seen a case recently where *both* a lower second molar and a first bicuspid were involved in the production of a facial fistula.

57. In Cases of Insomnia, Neurasthenia, Insanity and Kindred Nervous Disorders.

If Dr. Henry S. Upson, of Cleveland, were a dentist, his assertion that dental lesions may, and do, cause insanity, would be met, not altogether unfairly, with the argument that, in the practice of his specialty, Dr. Upson had developed a rare case of myopia, and could no longer see past his especial field and consider other etiological factors. But Henry S. Upson is not Henry S. Upson, dentist; he is Henry S. Upson, M.D., Professor of Diseases of the Nervous System at the Western Reserve University, and Attendant Neurologist to the Lakeside Hospital, Cleveland, Ohio.

The situation as it stands to-day is this: Dr. Upson claims that impacted teeth and chronic alveolar abscesses cause insomnia, neurasthenia and insanity. He gives histories of radiographically illustrated cases, which have been cured by extraction of the impacted or abscessed teeth,

Fig. 294. Dento-alveolar abscess of the lower first molar discharging on the face.

and he asks a question: "*If* a diseased uterus can cause insanity (and it is believed that it can), then why not dental disease?" The nervous connection between the teeth and brain is much more intimate than that between the uterus and the brain. No one answers Dr. Upson's question, and so far, no one has in any way tried to prove Dr. Upson wrong in his belief that the teeth are responsible for grave nervous disorders. We must then, in fairness, accept what he says as the truth, until we are able to show wherein he is mistaken.

To give you an idea of the importance of dental lesions as a causa-

tive factor in the neurosis, as promulgated by Dr. Upson, I quote from the doctor's book, *"Insomnia and Nerve Strain":*

"Of the viscera responsible for the more obscure cases of nervous and mental derangement, I have no hesitation in designating the teeth as the most important. This is not only on account of the common, almost universal occurrence of dental diseases, but because these organs move, during the period of their development, through the solid framework of the jaw, highly innervated and clothed by a membrane sensitive to impact and to corrosive toxins."

That Dr. Upson has met with skepticism on the part of his brother practitioners is suggested I believe by the following, quoted again from the book, *"Insomnia and Nerve Strain":*

"There seems to exist among physicians not only a disregard but a distinct, though mild dislike of the teeth as organs to be reckoned with medically, they being, as it were, an Ishmael, not to be admitted to their pathologic birthright. Lauder Brunton's essay on the subject is too little known and heeded, and few such systematic attempts have been made to correlate their disorders with the suffering of the human race, except for the obvious phenomena of pain. Ordinary pain at a distance, as headache or neuralgia, due to the teeth, though well known, is commonly disregarded. Even the various reflex nervous phenomena in children, convulsions, fretfulness, and fever, are not now ascribed to the irritation either of teething or of dental caries, but to digestive disorders. The state of recent opinion, as enshrined in epigram, is that 'The result of teething is nothing but teeth.'"

My readers may ask what has all this to do with dental radiography? Just this: the radiograph should be used more extensively, as Dr. Upson has used it, in a search for dental lesions in cases of the various nerve disorders, for Dr. Upson states "The lesions can seldom be observed by any means save the use of the X-rays."

Though I would like to print a radiograph and history of all of the different neuroses including insomnia, neurasthenia, mania, hysteria, melancholia and dementia, it would hardly be in keeping with a work of this kind, and I shall therefore give but one case, which is more or less typical.

Fig. 295.

Case: Melancholia and insomnia. "An unmarried woman, twenty-seven years old, a teacher, for a year had been profoundly melancholy with intractable insomnia, delusions of various deadly sins, and entire hopelessness of recovery. Restlessness was extreme, tonic and local uterine treatment were of no avail. As a last resort the teeth were examined. They were apparently in perfect condition. A skiagraph (Fig. 295) showed an impacted upper third molar tooth pressing against the second molar, a con-

dition obviously capable of causing irritation. The symptoms, in about a week after the removal of the tooth, began to improve. Recovery was complete in six or eight weeks, and has persisted. There had been at no time pain or other localizing symptoms."

Fig. 295. Impacted upper third molar, causing melancholia and insomnia. (Radiograph by Lodge, of Cleveland.)

In concluding our consideration of this subject, I quote from a recent paper by Dr. Upson:

"The following is a tabulated statement of cases of neurasthenia and the psychoses seen in private practice during about two and a half years, in which skiagraphic examinations of the teeth and jaws were made. These results represent the first stumbling efforts in a new and unknown field, and so do not adequately show what may be accomplished by skill and careful endeavor along the same line:

	Number	Operation	Recovery	Convalescent	Improved	Unimproved	No Data
Manic depressive type.....	11	9	5	..	2	..	2
Dementia precox.....	10	8	5	1	..	2	..
Psychosis	4	4	1	2	..	..	1
Insomnia	7	6	2	..	4	..	..
Neurasthenia	26	15	1	4	6	1	3
	58	42	14	7	12	3	6

The following is a separate statement of the cases of impaction included above:

	Number	Operation	Recovery	Convalescent	Improved	Unimproved	No Data
Manic depressive type.....	5	3	2	..	1	..	..
Dementia precox.....	7	5	4	1	..	..	..
Psychosis	2	2	1	1	..	..	..
Insomnia	3	2	..	..	2	..	..
Neurasthenia	13	9	..	4	2	1	2
	30	21	7	6	5	1	2

58. In Cases of Periodic Headaches.

Irritation of the trifacial nerve may cause headache. The irritation may be due to such lesions as an impacted tooth, a chronic abscess, or a cementoma, for examples.

Fig. 296. "After the removal of the malposed impacted cuspid seen in Fig. 296, severe headaches which she (the patient) had had once or twice a week for many years ceased immediately."*

Several cases similar to the one cited above have been reported in recent dental literature.

Fig. 296

Fig. 297

Fig. 296. Malposed impacted lower cuspid, responsible for periodic headaches. (Radiograph by Thomas, of Cleveland.)

Fig. 297. An impacted upper cuspid, which caused blinking of the eyes. (After Dr. Varney Barnes.)

59. In Cases of Facial Gesticulatory Tic. (Spasmodic Twitching of a Set of Facial Muscles.)

Fig. 297. "An impacted upper cuspid which caused blinking of the eyes."**

Dr. Barnes also reported a case of twitching of the facial muscles on one side. On the corresponding side two supernumerary teeth were found. I have been unable to learn from Dr. Barnes whether removal of the supernumerary teeth effected a cure. Dr. Barnes agrees with Dr. Upson thus far at least: both men are of the opinion that impacted teeth may be responsible for varied and grave nerve disorders. Dr. Up-

*Dr. Henry S. Upson, Cleveland, Ohio.
**Dr. Varney E. Barnes, Cleveland, Ohio.

son's treatment has always been extraction, while Dr. Barnes advocates orthodontic procedures, such as enlarging the dental arches and elevation of the impacted tooth.

60. To Allay the Fears of a Hypochondriac.

Every practitioner of dentistry and medicine has trouble with hypochondriacal patients, patients suffering — and actually suffering — from some imaginary ailment. What these patients need is psychic treatment.

Fig. 298. The radiograph demonstrates the absence of a piece of the lateral root above the lateral dummy and shows the canals of the central and cuspid well filled and the tissues at their apices healthy. (Radiograph grossly retouched.)

To be sympathized with—or a better way to state it would be to say "understood"—and at the same time shown that their trouble lies, not in any pathologic lesion, but in faulty habits of thought.

Fig. 298.

Case: Young lady, age about twenty-three, complained of obscure indefinite pains in the region of a bridge extending from central to cuspid, which pains she declared were due to an unremoved portion of the lateral incisor root. Having seen the lateral root when it was extracted, and superintended the treatment of the central and cuspid, and the making of the bridge, and knowing the patient—in short, knowing the complete history of the case—I was inclined to believe that the trouble with the bridge lay in the diseased imagination of the patient. After treating the case with counter-irritants once or twice, each time conversing freely with the patient concerning her symptoms, and failing to observe any clinical signs of a pathologic lesion, I became convinced that my original surmise was correct, and that the

teeth involved in the bridge were causing no pain. I positively knew there was not a piece of the lateral root above the artificial dummy, as the patient insisted. Having arrived at this conclusion, I proceeded as tactfully and kindly as I could to explain my belief to the patient. Whereupon she broke down and cried, displaying definite symptoms of hysteria. I want it distinctly understood that I did not blame the patient for her condition; that I was not out of patience with her; that I did not tell her there was nothing the matter with her—for there was, though the seat of the trouble was not the bridge. And this I tried to make her understand. After she had recovered somewhat from her crying, I said: "Now I do not want to take that bridge off, for I know there is no root beneath it. I do not need to look and see, as you ask me to. But I know a way of looking at the bridge so we can *both* see it if there is any root there, or if either of the crowned teeth are at all diseased. If I can show you beyond the shadow of all doubt that there is no root there, will you believe that what I have been telling you is perhaps true, that the bridge is all right, and that you are falling into faulty habits of thought?" She said she would.

The radiograph (Fig. 298) shows there is no root above the lateral dummy, that the canals of the central and cuspid are properly filled, and that the tissues at their apices are not diseased. The radiograph of her own case, together with several others showing roots above bridges, abscesses and perforations, were shown and explained to the patient. I did not attempt to force her to admit that I had been right in my diagnosis of her case, nor did she do so verbally; but she has not returned for further treatment, and she still wears the bridge.

61. In Cases Where the Patient Cannot Open the Mouth Wide Enough for an Ocular Examination.

An impacted lower third molar sometimes causes a false ankylosis. We suspect the presence of the impacted tooth, but are unable to demonstrate it except by the use of the radiograph made extra-orally (Fig. 108). With the radiograph to confirm suspicions and show the exact location of the offending tooth, the operator may proceed to anesthetize the patient, force the mouth open with a mouth prop and extract the tooth.

Fig. 299. Fig. 299 is a case in which the mouth could not be opened because of the inflammation caused by the impacted lower third molar seen in the radiograph.

62. In Research Work to Study Osteology, the Development of the Teeth, Action of Bismuth Paste, Bone Production and Destruction, Changes Occurring in the Temporo-Mandibular Articulation When Jumping the Bite, Blood Supply to Parts, Resorption of Teeth and the Causes for It, Etc.

The value of the radiograph to the man who is looking for the just-how and why of things is clearly apparent. It obviates the necessity of conjecture, and gives us simple, indisputable facts. Many problems now

Fig. 299. Impacted lower third molar, causing a false ankylosis. (Radiograph by Graham, of Detroit.)

confronting the dental scientist can be solved only by the intelligent and persistent use of the X-rays.

It is not my intention now to tell of all the different uses to which the radiograph has been and may be put in the broad field of dental scientific research. I could not if I tried. I shall mention but a few.

Dr. Joseph Beck, by the use of the stereoscopic radiographs, is making a comparative study of the pneumatic sinuses of man and the lower animals.

Dr. Johnson Symington and Dr. J. C. Rankin have recently published a book, *"An Atlas of Skiagrams,"* illustrating, in twenty radiographs, the development of the teeth and jaws from birth to the age of sixteen years.

I have demonstrated the action of bismuth paste in one case. (Fig. 223.) No definite conclusions should be drawn from this single case. The field of research work along this line is still wide open and inviting investigation.

Fig. 300.

Fig. 301.

Fig. 300. Abscessed upper lateral incisor, causing disintegration of the built-in bone at the apex of the central incisor. (Radiographed by Schamberg, of New York City.)

Fig. 301. The same as Fig. 300 after treatment and filling of the canal of the lateral. Bone is being rebuilt into the abscess cavity at the apex of the central. (Radiographed by Schamberg, of New York City.)

Bone production and destruction in alveolar abscesses is a matter of which we know entirely too little. A systematic radiographic study of the subject is bound to result in the disclosure of interesting and important facts.

Figs. 300 and 301.

A question, the answer to which is of extreme importance is, "Do alveolar abscess cavities become filled with bone after the abscess is cured?"* My experience leads me to believe they do; but the new bone may not be quite as dense, and it is susceptible to ready disintegration as a result of contiguous inflammation.

Observe Fig. 300, a case from the practice of Dr. R. Ottolengui. Note the light areas at the apices of both the central and lateral. A cursory observation of the radiograph, and a failure to consider clinical history, would result in the diagnosis of abscess of both the central and lateral. Observe, please, however, that the canal of the central is well filled, while the canal of the lateral is not filled at all.

* For a further consideration of this subject see Appendix Chap. XI.

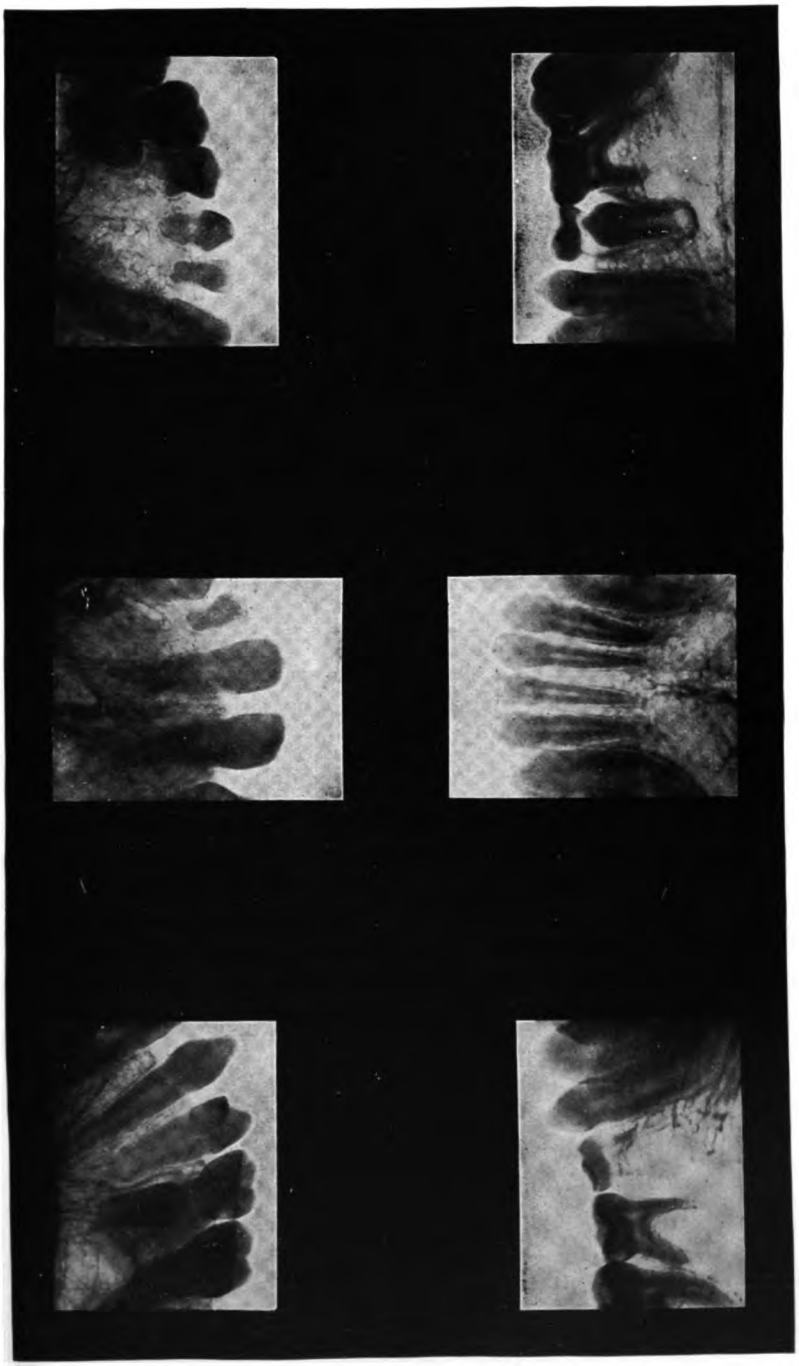

Fig. 302. Radiographs demonstrating the congenital absence of seven secondary teeth. (Radiograph by Schamberg, of New York City. Case: One in the practice of Dr. Ottolengui, of New York City.)

The central had been filled three years previously to the making of the radiograph, and there had been no recurrence of the abscess during that time. The lateral was treated and its canal filled, when all symptoms of abscess disappeared. Fig. 301 was made after the canal of the lateral was filled. What I shall speak of now I fear cannot be seen in the accompanying half-tone; but it can be observed *easily* in the negatives. At the apex of the central there is a deposition of bone in the old abscess cavity. The bone is not as dense as the surrounding structure, and hence the outline of the old cavity can still be seen; but it is sufficiently dense, so that it can be observed distinctly, and especially well when compared with the cavity at the apex of the lateral, which has not been freed from infection long enough to permit of an osseous formation within it.

Just what changes occur in the temporo-mandibular articulation when "jumping the bite" is still an unsettled question. It is extremely difficult to radiograph this articulation, but it can be done, and it is not unreasonable to expect that some day the radiograph will show us just what occurs. Dr. H. A. Ketcham, of Denver, is, and has been for some time, working in this field of research.

Dr. Cryer, in a recent article on the study of blood supply to the jaws and teeth, printed a radiograph of a disassociated mandible injected with mercury. How well blood supply may be studied by injecting the vessels with bismuth paste, or some other substance opaque to the rays, then making a radiograph is obvious and most encouraging to the student.

Fig. 302. The radiographs are of a little girl eleven years of age. They demonstrate the congenital absence of the following teeth: In the upper jaw both lateral incisors, one cuspid and one bicuspid; in the lower jaw three bicuspids, making in all seven permanent teeth congenitally absent from the jaws. Despite the absence of the permanent teeth resorption of the roots of the temporary teeth occurs, showing that the resorption is not dependent on the eruption of the permanent teeth. I do not make the statement that the temporary tooth roots resorb independently of the succedaneous teeth because of what I see in the radiograph in Fig. 302. Fig. 302 but illustrates what has been observed in many other radiographs.

Dr. H. A. Ketcham, with the aid of radiographs, has endeavored to disprove that certain orthodontic procedures caused impaction of the third molars.

Figs. 303 and 304. The discussion of the orthodontic procedure of "opening the maxillary suture" is one in which the radiograph is yet playing an important rôle. That

this suture can be opened is claimed by Dr. Varney C. Barnes. Figs. 303 and 304 are from the practice of Dr. Barnes. How wide it may be opened, the permanency of the separation of the bones, and the benefits to be derived from the operation I shall not discuss, but radiography will always be a valuable aid in determining the condition, both before and after treatment.

In the discussion of a paper, read at a dental society meeting, Dr.

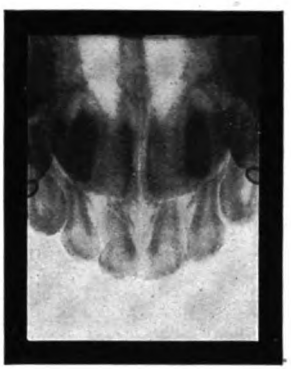

Fig. 303.

Fig. 304.

Fig. 303. Before attempting to open the maxillary suture. (Radiographed by Lodge, of Cleveland.)

Fig. 304. Same case as Fig. 303 fourteen days later, after attempt to open the maxillary suture. (Radiographed by Lodge, of Cleveland.)

Don Graham recently said: "If the radiograph has done nothing else it has proven beyond all doubt that the best canal filling in use to-day is gutta-percha."

Also radiographs have shown us that, when filling canals with large apical foramina, we would better force a little gutta-percha through the apex rather than to fall short of reaching the end of the root. Of the two mistakes, the former is less likely to be followed by abscess formation.

Fig. 305. The radiograph shows an upper cuspid with a perforation to the mesial through the side of the root into the peridental membrane. The radiograph was made several weeks after patching the perforation with gutta-percha. There is scarcely any inflammation at all at the point of perforation, showing how well the tissues tolerate gutta-percha.

Under this heading of research work allow me to mention the recent

disturbing paper by Dr. William Hunter, of London. Let me say that Dr. Hunter's charge that we, as a profession, practice septic dentistry is well founded. One needs to do but little radiographic work to be fully convinced that the conservative dentistry of which we have been so proud is often a dreadful mistake. It consists all too often of simply treating the case until it becomes a chronic abscess, then, with the abatement of

Fig. 805. The arrow points to a perforation, through the side of the cuspid root, which has been patched with gutta-percha.

the acute symptoms, calling the case cured. As a radiographer, a man in a position to make extensive observations, I declare that the root canal work of the majority in our profession is a menace to health. Bad root canal work is not usually the result of inability to do the work properly, so let us have hope. It is nearly always due to the fact that the operator *thinks* he cannot get paid for the work. And it is indeed hard to convince a public, which has received its dental education from advertising quacks, of the necessity of receiving and paying for the proper treatment of its teeth.

I would not be understood as saying that I agree fully with Dr. Hunter. I do not. But the doctor is on the right track. He knows there is such a thing as bad dentistry, septic dentistry, being practiced, as do all observing men, especially radiographers.

63. As a Record of Work Done.

Any sort of a record of work done is always valuable. Radiographic records of canal fillings, extractions and the like are often of the utmost value to the operator. Such records would be of the most gratifying service in the unpleasant event of being tried for malpractice. A patient,

let us say, finds it necessary to go to the hospital for a week after the extraction of a badly impacted third molar. The next thing the operator knows is that suit has been brought against him. He learns that he "broke the jaw-bone," and that the patient is to remain a "helpless invalid for the balance of her life," because of "his lack of skill, his ignorance and brutality." Radiographs of the case showing just what had been done for the patient might prevent the suit or win the case for the operator.

In cases where the patient is seized with a decided disinclination to pay a dental bill the radiograph may sometimes be used to advantage. These patients usually suffer from the loss of memory, and tell the judge that the plaintiff is quite mistaken in imagining that he filled their root canals. Radiographs would go far toward convincing the judge of the validity of the claim.

64. In Cases of Hidden Dental Caries.

The "diagnosis of hidden dental caries by means of radiographs" was suggested and recommended by Drs. H. W. C. and C. F. Bodecker in a short unillustrated paper printed in the *Dental Review,* April, 1912. I quote a paragraph from the article referred to. "The diagnosis of caries in its first stages on the proximal surfaces of molars and bicuspids is often difficult, and frequently patients complain of sensations at points where we cannot discover caries either with floss silk or explorer. Separation then has to be resorted to, in order to definitely locate the trouble. Sometimes the patient is not able to point out any single tooth in which he notices the sensation; he simply tells us that it is 'somewhere on that side,' and passes the finger over two or three teeth. Another factor which makes diagnosis difficult is reflex pain. Frequently the irritation is in an upper tooth, and the patient experiences the pain in a lower one, and *vice versa.* Therefore, to obviate the useless separation of teeth in locating small carious spots, we have used the Roentgen apparatus. It would, nevertheless, be a useless expenditure of time and work to radiograph two or three teeth in the upper arch, and if no defect had been found to repeat the same in the lower. We have, therefore, constructed a film holder by the aid of which the crowns of the bicuspids and molars of one side can be photographed at one time."

Personally, I have never put the radiograph to the use suggested by the Doctors Bodecker, but it is my intention to do so.

And so—we have passed over the uses of the radiograph in the practice of modern dentistry, and it has been a long trip. Permit me to repeat what I said at the beginning of the chapter, for you are now better able to understand and believe me. Of the uses for the radiograph enumerated, some are of cases that the general practitioner of dentistry may

not be called upon to diagnose or treat oftener than once or twice in a lifetime, perhaps not at all; but by far the greater number are of cases the like of which we meet almost daily in the practice of dentistry.

There is a popular belief among dentists at large that the use of the radiograph is indicated only in the baffling, the exceptional, the iconoclastic cases in our practice. This is not true. It is a fact that the radiograph, in a spectacular manner, has been responsible for the diagnosis and cure of many baffling cases. But I am tempted to say that this is unfortunate. For the radiograph does not always solve the mysteries of the refractory cases, though practitioners of dentistry and medicine pay it the embarrassing and unfair compliment of expecting it to do so. The radiograph's most potent value in dentistry is in the ordinary, the every-day cases which come to our offices—in cases of impacted teeth as an aid in extraction; in cases where the apical foramen is very large as an aid in filling the canals properly; in cases where apical sensitiveness may be due to a large apical foramen or an unremoved, undevitalized remnant of pulpal tissue; in cases of retained temporary teeth to learn if there be succedaneous teeth present in the jaw; in cases of badly decayed teeth of the secondary set in the mouths of children to learn if the roots of the diseased teeth are fully formed; in cases of abscess to determine which tooth is affected; in cases of traumatism, and so on. It is in these cases, met constantly, that we may use the radiograph and derive the greatest assistance and benefit. In baffling cases we will often be disappointed in our use of the radiograph, but in the ordinary cases, such as I have just enumerated, never, for we know just what to expect, and we do not expect too much.

It should ever be borne in mind when using the radiograph for diagnostic purposes that it is only an *aid;* in many cases the greatest aid we have, but, nevertheless, only an aid in diagnosis. No other methods or means of diagnosis should be forgotten or slighted.

When the use of the radiograph fails to reveal the cause of the trouble it is not fair to look upon its use as of no assistance or value. For example, a patient is suffering from false ankylosis. Judging from the symptoms we suspect an impacted lower third molar to be the active cause. We make a radiograph and fail to find an offending third molar or anything else that might be responsible for the ankylosis. It is natural that we should be disappointed, but we must not feel that the radiograph has been of no service at all, for we now know that an impacted third molar is *not* the cause of the trouble, and we have taken an important step in diagnosis by elimination.

In printing the great number of radiographs, which have appeared in this chapter, it is inevitable that some should not be good. It must be

remembered, too, that *only an idea* of what can be seen in negatives can be learned from half-tones. It has been most discouraging to the writer to observe, at times, the great loss of detail in the printed half-tones, as compared to the original negative. However, with the rarest exception the loss of detail was not the result of incompetency on the part of the makers of the half-tone plates. This collection of dental radiographs has

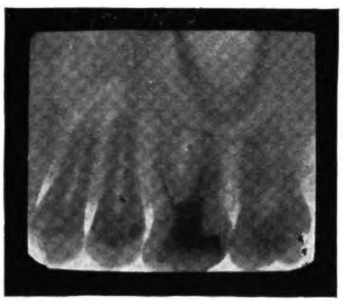

Fig. 306. The light area at the apex of the upper first bicuspid has the appearance of an abscess.

Fig. 307. The same case as Fig. 306, proving the spot at the apex of the upper first bicuspid in Fig. 306 is not an abscess.

been transferred from the photographic print to the half-tone in a masterful way, and its failure to be perfect represents only the shortcoming of the process itself.

Misinterpretation of radiographs is one of the easiest things in the world and, for this reason, I can already hear, in imagination, the cries of condemnation of the disappointed ones who will, within the next few years, take up dental radiographic work.* I believe that no one who has ever done radiographic work has experienced disappointment more often, or more keenly, than I have. But every radiograph ever made is the product of simple physical and chemical laws, and when misread the fault usually lies in the reader.

Very often it is expedient to make several radiographs of the same part, changing the pose slightly to verify or disprove the findings in the first picture of the part.

Figs. 306 and 307. Fig. 306 shows what seems to be an abscess at the apex of an upper first bicuspid. Fig. 307 is of the same case and shows no shadow such as is seen in Fig. 306. The spot in Fig. 306 is not an abscess; it is a spot produced by faulty technic in the process of fixing.

* Written in 1912.

When I started this chapter I expected to close it by quoting words of praise for the radiograph, spoken and written by the leading men in the dental profession. I shall not take the space to do this, but shall tell you simply that I could if I wished. I shall quote but one man who, in an impromptu discussion, voiced the sentiments of all. Though he is a specialist in oral surgery, he speaks as well for the orthodontist, the extracting specialist and the general practitioner. Dr. T. W. Brophy said "Now that we have the X-ray picture to help us, I do not see how we could possibly get along without it."

The greatest argument in favor of the use and value of the radiograph, however, does not lie in the enthusiastic and inspiring remarks concerning its value, but in the irrefutable facts set forth and illustrated in this chapter.

Seldom, indeed, is the use of the radiograph in dentistry a matter of life or death to the patient, though it may sometimes be, but often, often indeed, does health and happiness depend on its use.*

* In the light of recent discoveries pertaining to metastatic infection due to local foci of infection in the mouth, it seems that the use of the dental radiograph IS often a matter of life and death. One needs to see but one case of arthritis deformans greatly improved or cured, following the eradication of oral foci of infection, to be tremendously impressed.

CHAPTER VIII.

The Dangers of the X-Ray.

A work of this kind would be worse than incomplete, it would be a positive menace to the welfare of the public and the profession, without a chapter devoted to vigorous warning of the evil results that may occur from exposure to the X-rays.

The following unfortunate results have been attributed to the action of the X-rays: dermatitis (*i.e.*, X-ray burn), cancer, leukemia, sterility, abortion, insanity, lassitude and alopecia.

We will now consider each of these foregoing dangers, taking them up in the order named.

X-ray burns are of two kinds, acute dermatitis and chronic dermatitis.

Acute Dermatitis.

Acute dermatitis* manifests itself anywhere from twenty-four hours to (in rare cases) as long as two or three months after exposure to the rays. The time, however, is usually from three to fifteen days.

Itching and redness are the first symptoms to appear. The itching becomes intense, swelling occurs, the skin grows harsh and dry, and has a smooth, glossy appearance.

In mild cases the inflammation subsides gradually after a few days and, depending on the severity of the burn, may or may not be followed by desquamation and loss of hair.

This Elberhart calls an acute dermatitis of the first degree.

In the more severe form of acute dermatitis, termed by Elberhart of the second degree, there will be the formation of a blister with the usual serous exudate and marked neuralgic pains.

*Elberhart "Practical X-Ray Therapy."

In the very severe cases of acute dermatitis, where the deeper layers of the skin and underlying tissues are affected, a slough forms and the destructive condition shows a marked tendency to spread and become malignant. Severe pain in these latter cases is a wellnigh constant symptom.

Chronic Dermatitis. After exposing himself to the X-rays a great number of times, and having had a number of mild attacks of acute dermatitis—or perhaps without ever having had acute dermatitis—the X-ray operator notices certain tissue changes occurring, usually on the back of the hands, sometimes on the face and chest. The hands, face and chest are most likely to become affected, because these parts are the most exposed to the rays. There is a pigmentation of the skin very similar to tanning, such as sun and wind will produce. Freckles occur in some cases. The skin becomes harsh, dry and wrinkled—the same changes that occur with age. Hair drops out. The fingernails become brittle and thin and ridged longitudinally. Small, hard, scabby growths (keratoses) occur here and there. These growths break down into ulcers, which often become cancerous. (Fig. 308.)

Fig. 308. Chronic X-ray Dermatitis.

Cancer. There has been a great deal of discussion as to whether X-rays can, or cannot, produce cancer, but in the face of such reports as Dr. C. A. Porter's* I do not see how anyone can dispute it. According to the highest authorities, X-rays can, and have, produced carcinoma. In 1907 Dr. Porter re-

* "The Surgical Treatment of X-Ray Carcinoma and Other Severe X-Ray Lesions, Based Upon an Analysis of Forty-seven Cases."

ported eleven cases of "unquestionable X-ray cancers," six of which proved fatal.

Cancer usually follows a chronic dermatitis, occurring at the site of a former ulcer, though it may result from a very severe acute dermatitis. When cancer follows chronic dermatitis the victim is almost invariably an X-ray operator; when it follows acute dermatitis the victim is usually a patient who has been exposed to the rays for therapeutic purposes.

Even before the formation of cancer, when chronic ulcers appear, operation after operation becomes necessary. These operations consist of

Fig. 309. X-ray Cancer.

a curettement of the ulcer and skin grafting. With the formation of cancer commences amputation. First one finger, then another, then two more, then a hand, both hands, an arm. A welcome death, due usually to the formation of metastatic cancers throughout the vital organs of the body, is the next step of the progressive case.

I print reports here by Dr. Porter of two more or less typical cases of fatality due to X-ray lesions:

"Case XXXI—Man, 32 years old, who, after three years of X-ray work, suffered from severe lesions on both arms, breast, neck and face. In 1901 there began a slowly growing ulceration of the back of the right hand, which, by the middle of 1902, had become a gangrenous epithelioma; glands enlarged at the elbow and in the axilla. Amputation at the shoulder; axillary glands removed, and found full of squamous-celled carcinoma. Sound healing. In December, 1904, a typical cancer of the lower lip and another of the angle of the mouth were excised, as was a suspicious

lesion on the back of the left hand. In March, 1905, a growth of the cheek was removed, which was pronounced by Unna to be a sarcoma. In September, 1905, excision of the right lower jaw for carcinoma. Recurrence, involving the tongue and the adjacent cheek, was present in February, 1906. Death soon followed."

"Case XLVII. Summary: In 1897 began work with the X-rays, testing the tubes for several hours a day. First noticed erythema and

Fig. 310. Hands of X-ray operator after thirty operations.

warty growths in 1900. In 1905, keratoses and warts had formed on both hands, chest and face. First carcinoma developed and required amputation of two fingers of the left hand in April, 1907; similar growth curetted on right hand. By March, 1908, rapid extension of the disease necessitating amputation of left forearm; curettage of epithelioma on right hand. August, 1908, involvement of epitrochlear and axillary glands. August 11, 1908, amputation of fingers of right hand. September 25, 1908, amputation at shoulder. Death on November 7, 1908; general carcinosis." (Fig. 309.)

The report of another case by Porter commences:

"I have operated upon this patient under ether thirty-two times, the operations varying in duration from one hour and a half to three hours. At present there remains of his left hand two joints of the little finger, the forefinger and thumb; of the right hand, the thumb, the middle finger, barring part of the terminal phalanx, and one and a half phalanges of the little finger. More than half of the skin of the backs of both hands consists of Thiersch grafts." (Fig. 310.)

Figs. 308, 309, 310, copied by permission from *The Journal of Medical Research.*

Regarding the pain suffered by these patients, with severe chronic dermatitis and cancer, Porter says: "The amount of pain suffered is variable though usually extreme. From my experience and personal communications with patients, I believe that the agony of inflamed X-ray lesions is almost unequaled by any other disease."

Leukemia. Leukemia is a blood disease characterized by an increase in the number of white blood cells. The cardinal symptoms of the disease are insidious emaciation and lassitude. It is generally fatal. Practically nothing is known concerning its etiology. It is suspected that continued exposure to the X-rays may produce leukemia but, as yet, this supposition has not been scientifically substantiated.

Sterility. X-ray operators of the male sex, who subject themselves to repeated mild exposures to the rays, are often sterile. This sterility is due either to the death of the spermatozoa, or to their complete disappearance from the semen. This condition has no effect one way or the other on the carnal instincts of the individual, and if the victim will discontinue exposing the parts to the X-rays, virility will be regained. Likewise repeated exposures of the ovaries to the X-rays will produce sterility in the female by causing a disappearance of the Graafian follicles; the menses do not cease, and sexual animation remains unaltered. As with the male, the power of reproduction is regained promptly when the parts are no longer subjected to X-radiation.

Abortion. Quoting from Elberhart (Practical X-Ray Therapy): "Fraenkel claims that the Roentgen ray retards the growth of the ovum and tends to produce abortion when the thyroid gland and ovaries are exposed to it."

Fraenkel has in mind the use of the X-rays as a therapeutic agent, and mentions a case of induced abortion after twenty-five exposures of five or ten minutes each every other day.

For the slight radiation required for dental radiographic work pregnancy *cannot possibly* be considered a contra-indication.

Insanity. There is a somewhat popular superstition that X-rays will produce insanity in those who constantly expose themselves to their action. This belief arose, I think, from the fact that a prominent X-ray operator lost his mind a few years ago. So far as I know he is the only X-ray operator, of the thousands engaged in the work, who has met with such a misfortune, and it is as ridiculous to blame the X-rays for it as it would be to claim that his insanity was caused by the suspenders he wore.

There is a belief among operators themselves that X-ray operators develop a "nervous, restless, intense personality." Whether the development of such a personality is due to the electric condition of the atmosphere of the operating room, to the action of the X-rays, or to the enthusiastic interest developed by research work is a matter of conjecture. Personally I do not believe any of these things are responsible for the restless, nervous personality of so many operators. These men were of a restless disposition before they took up X-ray work. In fact, their adoption of the work was but a sign of their restlessness and desire to be progressive.

Lassitude. X-ray operators often complain of a feeling of utter exhaustion. When it is proven that X-rays can produce leukemia, I shall believe that this feeling of extreme lassitude is caused by exposure to the X-rays. Until then I shall hold to the belief that this exhaustion, which unquestionably does occur, is due to the work, physical and mental, the bad air of the dark room, and the depressing disappointments experienced by all conscientious radiographers.

Alopecia. Loss of hair may occur from a severe X-ray burn, but I can find no reliable authority who attempts to prove that the X-rays will produce baldness of the head without dermatitis.*

Protection. Knowing now the dangers of the X-rays, how shall we protect ourselves and our patients against them? We shall protect ourselves by never exposing any part of our bodies to the direct or primary X-rays, and our patients by exposing them as short a time as possible.

How can we do radiographic work without exposing ourselves to the X-rays?

Sheet lead one-eighth inch thick is opaque to very penetrating X-rays. Lead glass—a transparent glass containing a great deal of lead silicate—though it would need to be "about two inches thick to totally obstruct very penetrating X-rays," nevertheless offers considerable, and perhaps sufficient, protection in the thickness of one-quarter inch.

The writer was informed that linoleum is opaque to the X-rays. To test the verity of this information Figs. 311, 312 and 313 were made. A study of the illustrations will show that, compared to lead or lead glass, linoleum offers very little resistance to the rays; compared to wood, the resistance is much greater. White linoleum offers more resistance than red, green or blue.

* For a further consideration of alopecia see Appendix, Chapter IX.

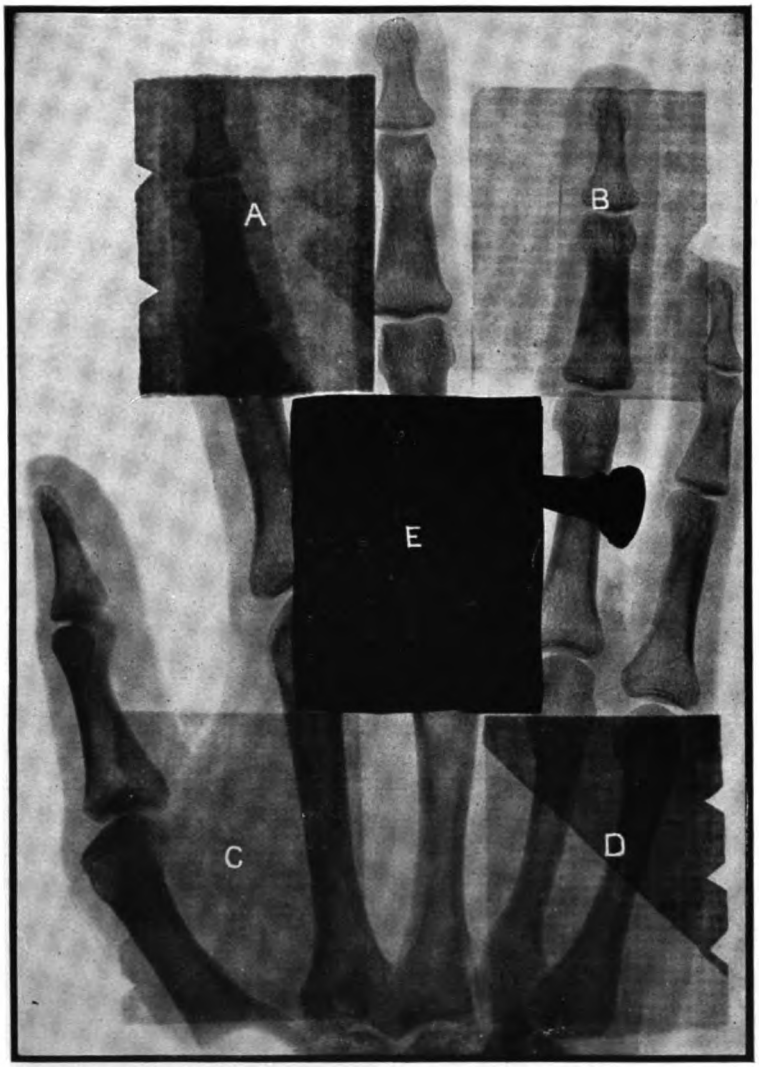

Fig. 311. A, B, C, and D are pieces of linoleum. E, a piece of sheet lead 1-16 inch thick.

Appliances for Protection.

The appliances which may be used for protection against the X-rays are: Protection lead screens (Figs. 314 and 315), protection lead cabinets (Figs. 316 and 317), protection shields for the tube (Figs. 60, 61, 63 and 64, Chapter III, and Fig. 318), protection or safety X-ray tubes (Fig. 319), X-ray proof gloves (Fig. 320), lead glass spectacles (Fig. 321), and protective aprons.

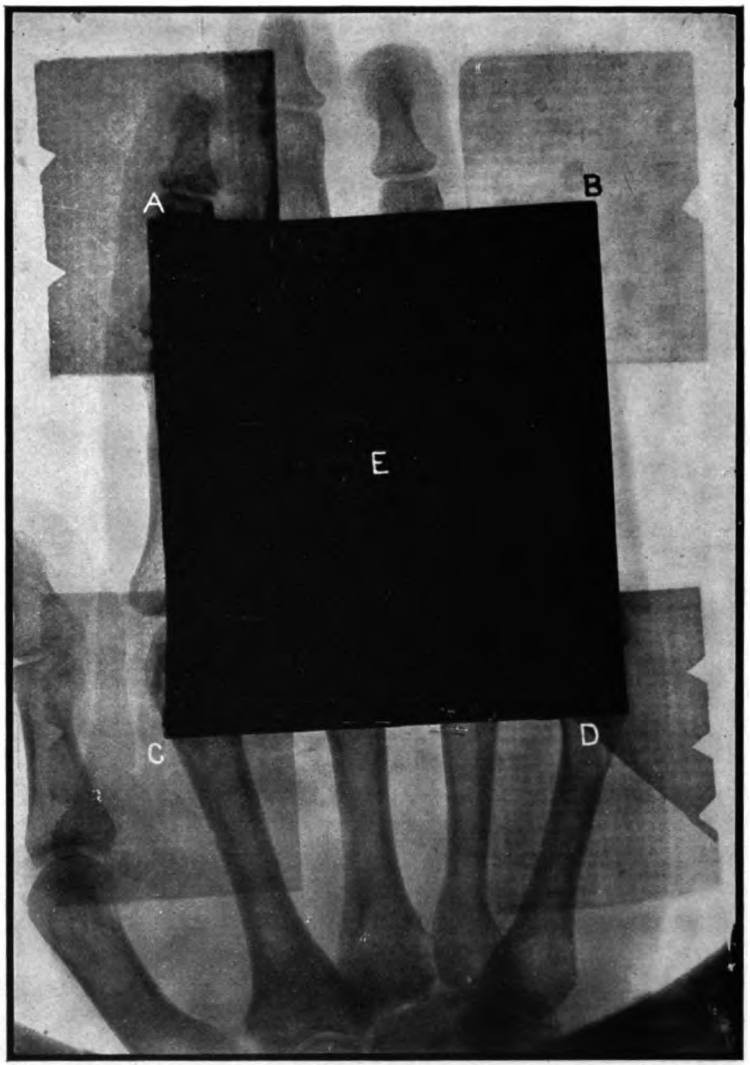

Fig. 312. A, B, C, and D, same as in Fig. 311. E, a piece of lead glass 1-4 inch thick.

The Lead Screen and Cabinet.

From the standpoint of protection for the operator nothing is so efficient as the lead screen or cabinet (Figs. 314, 315, 316 and 317). The use of either makes it possible for the operator to protect himself completely from all direct X-rays.

The lead used in protective screens and cabinets is usually one-six-

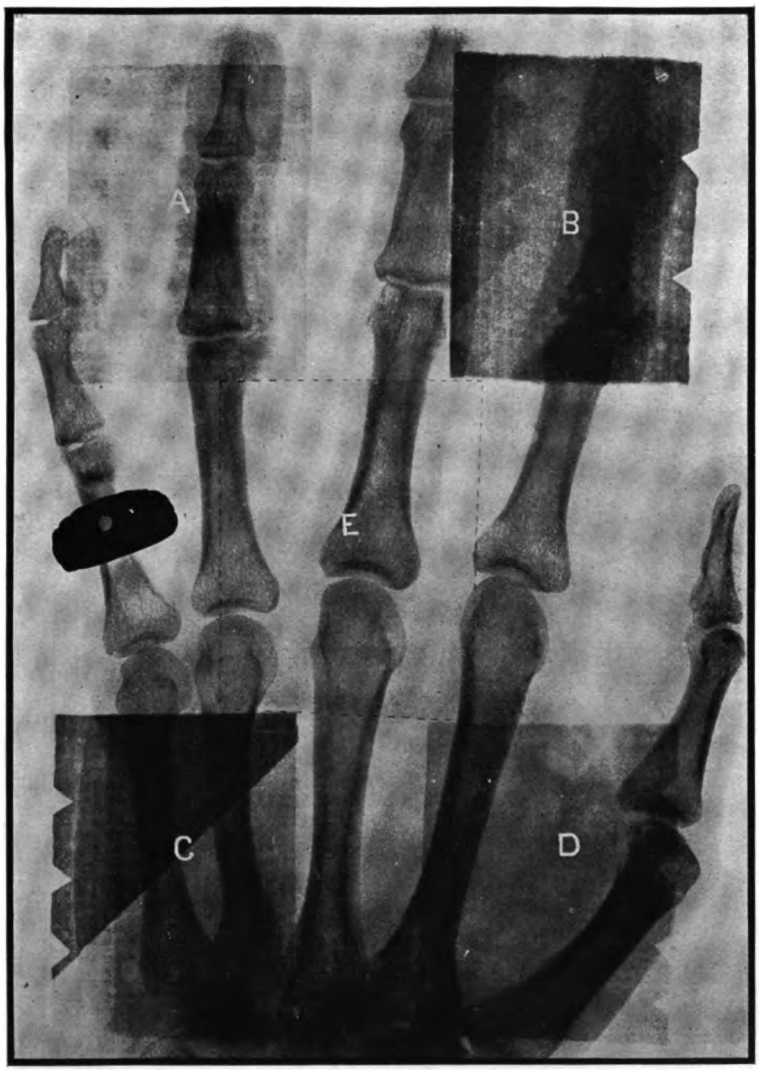

Fig. 313. A, B, C, and D, same as in Fig. 311. E, the dotted lines outline the position of a piece of pine wood 1-2 inch thick.

teenth inch thick. Lead of this thickness does not totally obstruct very penetrating X-rays when the tube is brought close up to it, but at the usual distance of several feet between tube and screen it is doubtful if any X-rays penetrate the latter.

The lead glass used in the windows in protection screens and cabinets is usually one-fourth inch thick. With the tube placed in close proximity



Fig. 314.

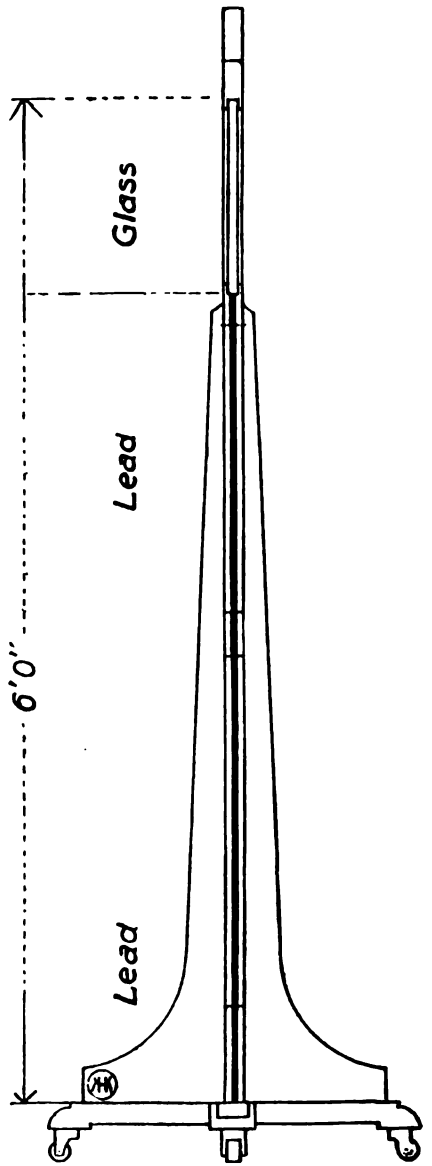

Fig. 315.

Fig. 314. Protective lead screen.

Fig. 315. Protective lead screen, sectional view.



Fig. 316.



Fig. 317

Fig. 316. Protective lead cabinet; front view.
Fig. 317. Protective lead cabinet; rear view.

to the screen, lead glass of this thickness is highly translucent to the X-rays, but with the tube a distance of several feet the rays penetrate the glass but feebly.

Instead of the lead glass window a screen may be covered entirely with lead and mirrors so arranged that the operator may observe his tube and patient from his position back of the screen.

Let it be clearly understood that the man standing behind a lead

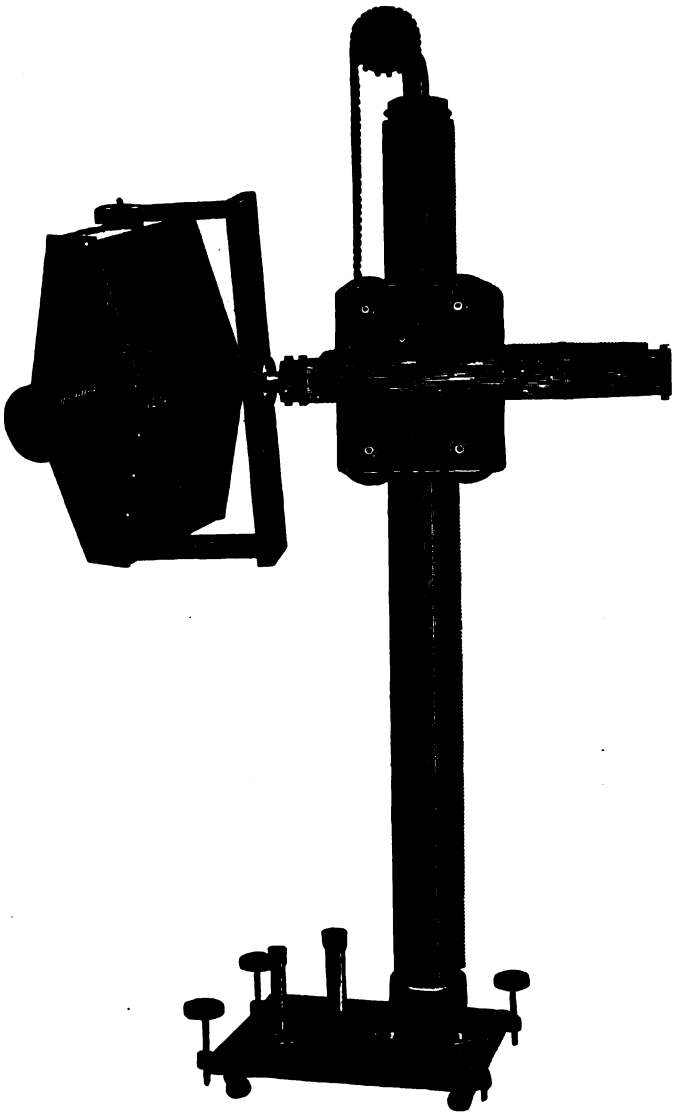

Fig. 318. Protective tube shield and stand.

screen is not *completely* protected from *all* X-rays. If the tube is rather close to the screen some of the X-rays may penetrate it—becoming extremely feeble, however, by the time they make the penetration—and he is, of course, exposed to the secondary, tertiary and other sets of feeble rays which fill the room like light. *But* he *is* completely protected from the powerful dangerous rays.

The protective lead screen, or cabinet, or their equivalent, is a necessity in the practice of modern radiography.

Protection Shields.

Protection shields are of three varieties: those made of lead glass (Figs. 60, 61 and 63, Chapter III), those depending on a sheet of metallic lead for their action (Fig. 64, Chapter III), and those made of rubber impregnated with lead or a salt of lead (in appearance similar to Fig. 64). The X-ray tube fits into the protection shield, which latter protects the patient to a great extent against the action of all X-rays except

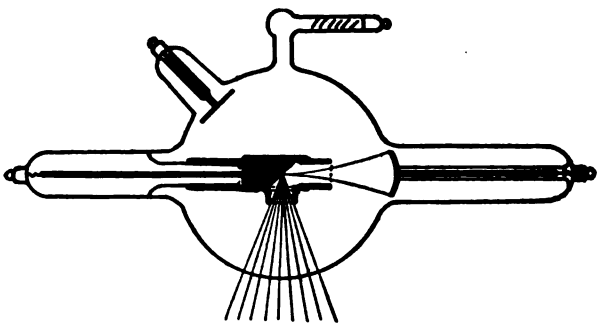

Fig. 319. Protection or safety, X-ray tube.

those which pass through the window of the shield and are being used to make the radiograph. As a matter of fact, the patient does not need this protection in the practice of dental radiography, but it is not inexpedient to use even protective measures that are thought to be unnecessary. The operator is also protected in a degree by the protective shield.

A protection shield calculated to take the place of a lead screen or cabinet is illustrated in Fig. 318. The protective material used is, I judge from its appearance, rubber impregnated with lead or a salt of lead. The manufacturers claim to use a German preparation, the formula of which is not divulged. This material is more opaque to the X-ray than lead glass, less opaque than metallic sheet lead.

Protection X-Ray Tubes.

Protection or safety X-ray tubes are manufactured, some of lead glass save for a window of ordinary glass transparent to the X-rays, and some with an internal protective arrangement which allows the X-rays to be given out from the tube from a limited place or spot only (Fig. 319).

Gloves. Fig. 320.

The hands of the operator may be protected with X-ray proof gloves. These gloves are usually made of rubber impregnated with lead or some salt of lead. Protective gloves may be made by painting ordinary leather gloves with several coats of white lead. X-ray proof or "opaque" gloves, as they are called, are not really opaque to X-rays; they are, in fact, quite translucent to powerfully penetrating rays.

Gloves should be used when the operator finds it necessary to hold the film in the patient's mouth himself. Seldom, very seldom indeed, is

Fig. 320.

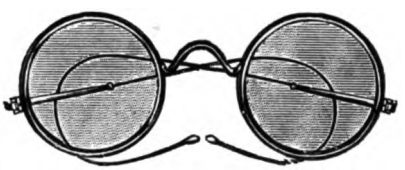

Fig. 321.

Fig. 320. X-ray proof, opaque, or protection gloves.
Fig. 321. Lead glass spectacles.

it necessary for the operator to do this, and I warn you against the practice with the same feeling that I would cry "Don't!" if I should see you making a plaything of a culture of the bacillus of the white plague.

Spectacles.

Protection lead glass spectacles may be used to protect the eyes (Fig. 321). Not because the eyes are any more susceptible to the ill effects of the X-rays than the skin of the face, but because injury to them is such a serious matter. Operators suffering from chronic dermatitis of the face usually suffer also impairment of vision.

Protection Apron.

Protection aprons of lead-impregnated rubber may be purchased from manufacturers of X-ray supplies. They are used to prevent sterility.

Protection gloves, spectacles and aprons are obviously not needed so long as the operator remains behind a screen.

Efficiency of Protective Measures.

Having now told you of the dangers of the X-rays and shown what measures have been adopted to prevent disaster, the question arises, Have these modern means of protection proved efficient?

So far as I know, no man who has conscientiously and consistently stayed behind a protective lead screen, or in a lead cabinet, has developed either cancer or dermatitis or sterility, or suffered or experienced any other pathological change which could be attributed to the X-rays. And some have been engaged in the work for as long as twelve years.

The severe and fatal cases of dermatitis and cancer have occurred in patients who received prolonged and repeated X-ray treatments for some disease, and in pioneer operators.

As practitioners of dental radiography, we will never be called upon to make such exposures of our patients as are necessary when the X-rays are used as a therapeutic agent.

The pioneer operators whose lives were ruined and destroyed by the X-rays did not protect themselves at all, not knowing that it was necessary. Even without any protection disaster did not manifest itself immediately, as might be imagined. Men worked for months and even years before any trouble developed. Take the case of a well-known manufacturer of X-ray tubes, for example. He exposed himself two or three hours daily, six days in the week, for a little over a year before he noticed any dermatitis. It must be remembered, however, that at that time the machines and tubes could not generate near the same number of X-rays that the improved machines and tubes of to-day can, and the danger was therefore less.

Efficiency of Slight Protection.

As an example of how efficient even slight protection is, Dr. Porter cites a case of dermatitis of the hands, save for the skin protected by a broad gold ring, which remained perfectly normal. The immunity which even light clothing offers is shown by the rarity or slight degrees of dermatitis above the cuffs, or on the other parts of the body protected by clothing.

Before it was known to be dangerous, operators formed the habit of using their hands for penetrometers—observing them through the fluoroscope to learn the power of penetration of the X-rays. This practice has doubtless caused many cases of dermatitis and cancer of the back of the hands. The use of any penetrometer save those of an improved type which enable the operator to "look around a corner" necessitates the exposure of the operator, especially his hands, to the rays, and I object to their use for this reason.

Summary of Danger to Operator.

Summarizing the danger to the operator, we may say simply this: If he will observe strictly the rule to remain behind a lead screen or in a lead cabinet he may work for a period of ten or twelve years in safety. What the dangers of exceeding this time limit are we do not know. Perhaps there are none. Perhaps all the older X-ray operators will die of leukemia within the next ten years. Who can say? We are entitled to our opinions, but no one really knows. The pioneers in the work are still in danger; we who follow are comparatively safe.

Though the operator need never expose any part of his body to any except the weak, harmless X-rays which fill the room, it is necessary to expose at least that part of the patient being radiographed to the direct rays. The question arises, how long may we expose the patient with perfect safety, without any danger whatever of producing acute dermatitis? Authorities are very reluctant to set this time limit.

The very few cases of serious acute dermatitis due to exposure for radiographic work occurred when the outfits used were so small that the time for exposures was as long as 20 or 30 minutes. Compare such exposures with those of to-day, which range from a fraction of a second to only one minute at most, even with the small suitcase outfits, and the improbability of producing dermatitis will be appreciated.

The first rule regarding the exposure of patients should be, *never expose the patient longer than absolutely necessary.*

Time Limit for Exposing Patients.* And now I shall place myself in line for criticism by authorities, by setting a time limit of exposure of the patient. Even with the smallest apparatus, and where a number of exposures are necessary, the aggregate time of exposure need not and should not exceed two minutes. If it is necessary to use this full time, two minutes in one day, then do not expose the same part of the same patient for about 14 to 30 days. Give the skin a chance to recover from any change produced in it, and so guard against a cumulative effect of the X-rays. I cannot imagine a case in dental radiography which would require an exposure longer than two minutes. And *seldom, indeed,* will it be found necessary to expose the patient, even in the aggregate when several radiographs are made, as long as the time limit set.

Two minutes is a conservative time limit *if the X-ray machine in use does not force more than about 20 milliamperes through the X-ray tube, and if the distance between target and skin at the time of exposure is not less than 16 inches.*

It may be truthfully stated that, so far as the patient is concerned, the application of the X-rays in the practice of radiodontia, is attended with no danger, *if the operator is careful.*

"In the early days of the X-rays there was a tendency to attribute X-ray burns, not to the X-rays themselves, but to some accompanying factor, the

* For a further, more scientific and more comprehensive consideration of the subject of the exposure of patients to the X-rays see the appendix to Chapter VIII.

exclusion of which would prevent the occurrence of X-ray burns."* Thus it was suggested that burns were due to an electrical condition surrounding the tube; to chemical conditions surrounding the tube; to bacteria being carried into the tissues by the X-rays; to violet rays, and so on. It is generally conceded to-day, however, that X-ray burns are the result of a specific action of the X-rays themselves on the tissues.

The Filter. There is a popular theory that for X-rays to have an effect on the skin they must be absorbed by it. Thus, the more penetrating X-rays which pass completely through the derma are less likely to produce dermatitis than rays of less penetration—just enough penetration to be absorbed. Knowing this theory we will now consider the use of a *filter*.

First, however, let us dwell on some points which were not touched upon in Chapter III, when we discussed the generation and nature of X-rays. It was stated in Chapter III that the X-rays from a tube of high vacuum were the most penetrating—that the penetration of the X-rays varied directly according to the degree of vacuum of the tube. Thus the X-rays from a high vacuum tube are very penetrating, the rays from a medium vacuum tube of medium penetration, and the rays from a tube of low vacuum, of low penetration. While this is true, there is something further to be said. Take the high vacuum tube: while most of the direct X-rays given off from it are of high penetration, *some* rays of medium and low penetration are also generated. While the tube of medium vacuum generates X-rays of medium penetration principally, *some* rays of high and low penetration are also generated; and though the X-rays from a tube of low vacuum are by far mostly of low penetration, some few rays of medium and high penetration are given off also.

Since the tube of a high vacuum is the one we use in radiographic work, let us enumerate the different sets of X-rays given off from such a tube. First, are the direct rays of high penetration—these are by far the most numerous; next, the sets of direct X-rays of medium and low penetration—these are comparatively few in number; then secondary X-rays given off from the glass of the tube; and last, if there is any inverse current in the tube, the rays generated by it.

If now the theory of absorption for effect is correct, then it is desirable to expose the patient only to the direct penetrating X-rays, and not to any of a less penetrating nature. In an effort to gain this end the filter is used.

Filters are made of wood, aluminum, leather and various other materials. For example, a piece of sole leather (no definite thickness) is

*Pusley and Caldwell, *"Roentgen Rays in Therapeutics and Diagnosis."*

placed over the window of the tube shield. The X-rays from the tube pass through it before striking the patient and the leather filters out, absorbs, all (?) of the weaker rays, which might otherwise be absorbed by the skin, and so guards against dermatitis.

The danger of producing dermatitis varies directly according to the number of X-rays which strike the part. Recollect that X-rays emanate from a point, traveling in diverging lines. Thus the greater the distance between the target and the skin the fewer rays strike the latter and the less danger of dermatitis. When the tube is brought very close (within three or four inches) to the part and *no filter is used* the skin is then acted upon not only by a much greater number of the direct penetrating rays, but also by the softer direct rays and by the secondary rays from the glass of the tube, so increasing the danger of burning materially. Thus it will be seen that the use of the filter permits the operator to place the tube close to the patient, so that his film or plate is within range of a greater number of penetrating direct rays, and at the same time protects the patient against the soft rays.

Theoretically, the use of the filter should aid in obtaining a clear radiograph by cutting out all save the direct penetrating rays. It is not as efficient in this respect, however, as the compression cone or cylinder and diaphragm. (Fig. 65.)

The number of direct X-rays generated by a given tube varies directly according to the number of milliamperes sent through it. Thus danger of dermatitis also varies directly according to the number of milliamperes sent through the tube. To elucidate: the distance between the tube and the skin remaining the same, an exposure of one minute with ten milliamperes passing through the tube will have practically the same physiologic effect as an exposure of two minutes with five milliamperes passing through the tube.

Immunity. There is no such thing known as either acquired or natural immunity to the action of the X-rays. Some are more susceptible than others, but no one is immune. Blondes are reputed to be more susceptible than brunettes. One burn greatly predisposes to another.

Treatment of Acute X-Ray Dermatitis. The careful practitioner of dental radiography, unless he meets a case of idiosyncrasy, will never have occasion to make use of knowledge regarding the treatment of acute X-ray dermatitis. It is well, however, to have the knowledge even though we are never called upon to use it. The most important thing to know concerning the treatment of acute X-ray burns may be learned from the nursery

rhyme about "Little Bo-Peep" and "her sheep." *"Let them alone."* So many drugs aggravate the condition that their use is contraindicated. A normal salt solution is, perhaps, the best wash and may be used freely.

There will be men in our profession who will not take up radiographic work, and who will say as an excuse for not doing so that they believe the work "too dangerous." Men who give this excuse are either unacquainted with the facts relative to the real danger or they are deceiving themselves. A disinclination to do necessary work, mental and physical, may lead a man to believe that the reason he does not take up X-ray work is because he believes it to be "dangerous."

Radium Rays.

It is interesting to know that the rays given off by the recently discovered element radium are very similar to the X-rays.

The commercial, so-called, radium is not pure radium. It is a salt of radium, usually radium bromid. So far, radium never has been isolated. Radium bromid is a white crystal.

"In 1896 it was discovered that the metal uranium gave off rays very similar to X-rays. Observing that different pieces of uranium varied greatly in their radio-activity, M. and Mme. Curie, of Paris, working on the hypothesis that uranium itself was not radio-active at all, but derived this property from some impurity incorporated in it, isolated radium bromid from the metal uranium."*

At present radium salts are obtained from uranium oxid, which latter is first obtained from pitchblende, a heavy black material in appearance somewhat similar to anthracite coal. One ton of pitchblende must be treated with approximately five tons of various chemicals and fifty tons of water to obtain one gram of radium bromid. The present market price of one gram of radium bromid ranges from $1,500 to $125,000, according to the radio-activity of the salt.

Radium rays, like X-rays, travel in straight lines, and secondary rays are given off from objects which they strike. They penetrate objects directly according to the density of the object and act on a photographic plate like light and X-rays. Their physiologic effect on the skin is very similar to X-rays. They produce a dermatitis almost identical to X-ray dermatitis. Becquerel carried a sealed glass tube containing 0.2 gram of radium salt in his shirt pocket for six hours. Fifteen days thereafter a dermatitis closely simulating X-ray dermatitis appeared, then subsided in about thirty days. One case of fatality from leukemia caused, presumably, by radium has been reported.

---

*Tousey, *"Medical Electricity and Roentgen Rays."*

CHAPTER IX.

Purchasing a Radiographic Outfit.

Before considering the purchase of a radiographic outfit, let us consider the question of who should do dental radiographic work. Should it be done by specialists or the general practitioners of dentistry? Six years ago it was my habit to answer this question unhesitatingly, and say "by the specialist."

My reasons for believing that dental radiographic work should be done by specialists were: (1) I was of the opinion that the radiograph was not particularly useful in the practice of dentistry except in rare cases, and (2) there being no text-book on the subject, proper self-education in the art was difficult, almost to the point of being impossible.

The City Practitioner.

As I see the situation to-day, however, the use of the radiograph is indicated in so many cases that it would be rather impractical for the general practitioner to refer all radiographic cases to the specialist, unless said general practitioner of dentistry happened to be located in a city of sufficient size to support a radiodontist; not simply a specialist in radiography, but a specialist in dental radiography. And this would be practical only if the radiodontist did work at practical fees and could be depended upon to faithfully fill all appointments. But granting the presence of such a radiodontist in a city it would be advantageous for the general practitioner of dentistry to patronize him and thereby give his patients the benefit of better service than he himself could hope to give. Also the trained radiodontist is in a position not only to give better service, but to give that service at a more reasonable fee.

Each general practitioner who installs an X-ray outfit must, if he wishes to be fair to himself, charge a fee in proportion to the money, time and study invested. Suppose now one hundred practitioners install X-ray machines: The investment in money, time and study—for all of which the "ultimate consumer," the patient, must pay—becomes tremendous compared with the investment of a single man, a radiodontist, who could serve these one hundred dentists. Thus it will be seen that the new specialist, the radiodontist, has a right to existence, looking at the matter

from an economic standpoint. And from the standpoint of service there can be no fair comparison of the skilled specialist to the general practitioner. A study of Appendix Chapter VI will give some idea of the treachery of radiographs in the hands of men who do not know their limitations. Fewer radiographs with intelligent interpretations is infinitely better than many radiographs incorrectly interpreted.

Argument Against Referring Patients.

The argument advanced in favor of each dentist doing his own radiographic work is that it is so much more convenient, for pulp canal work, to have the machine accessible and in the same office at all times. The convenience of having a machine in the office is indisputable, but the inconvenience of getting it there, and using it intelligently after it is there, is likewise indisputable. The dentist who refers his patients to a radiodontist for canal work should not make it *his practice* to place a wire in the canal of a tooth, send the patient to a specialist, located a mile away perhaps, then wait for the patient to return with a radiographic report. The patient should be referred to the radiodontist between the usual sittings. (A medicinal dressing may be sealed in the canals with the wires.)

Whether the city man, who has access to a radiodontist should do at least some of the simpler radiographic work, referring the balance to the specialist, depends on whether he has the time and enthusiasm necessary to take up the work. Unless he has the time to do it as it should be done, and unless the nature of the work appeals to him, he had better not attempt it.

Country Practitioner.

But how about the dentist practicing in a small city or town, who does not have access to a radiodontist? The dentists of such a community should band together and select one of their number to do radiographic work, buy a good outfit, and refer patients to the man selected to do the work. In case the dentists of the smaller communities cannot or will not do this, then each man must have his own X-ray outfit and do the best he can, just as the country practitioner is compelled to do the best he can with cases of malformations of the dental arch, difficult extractions, pyorrhea and other things which he could refer to the specialist if he were located in a city.

I have said that fewer radiographs with intelligent interpretations of them is better than a greater number with less intelligent interpretations. I must add that radiographs and interpretations of any sort are better than no radiographs at all, and, as I make this statement, I have not forgotten the perfectly asinine things which may be done as a result of misinterpretation of radiographs.

Specialists' Work.

For extensive diagnostic examination with the X-rays, requiring the making of many radiographs, some extra-orally, the work should as a rule be done by a radiodontist, even though it necessitates traveling from town to city on the part of the patient.

The foregoing is a consideration of what I think *should* be done. What will actually happen is, I think, that most dentists will install X-ray machines. The majority will do poor work and will not know it is poor and so will continue the work, while others who have access to radiodontists, seeing their own limitations, will discard their machines. The country practitioner, even though he detest the work and recognizes his inability to do it well, will probably be forced to continue it, and so in time will develop proficiency.

My second reason for having formerly been of the opinion that all radiographic work should be referred to specialists—viz., the difficulty of self-education—I hope is no longer a good reason, for I have tried, in this work, to supply a text-book which will enable the man who wishes to take up dental radiography to do so without wasting a great deal of time and energy reading books on electricity, photography and general X-ray work.

Untruthful Statements.

Some manufacturers make such statements regarding radiographic work as, "The work is extremely simple and can be mastered in a few minutes; in the time it will take to glance over our instructions which we send with each outfit." As a result of such misrepresentation men have taken up the work in profound ignorance and so have endangered their own and their patient's health and life. Self-education to do the simplest work *intelligently, safely* and *well* is not, I assure you, a matter of a few minutes' study, but of *many, many* hours.

X-Rays as a Therapeutic Agent.

In passing let me mention X-rays as a therapeutic agent in dentistry, and condemn them as useless. It is so difficult to measure the dose in X-radiation that it is only by long and usually soul-trying and disastrous experience that a man becomes competent to use X-rays as a therapeutic agent. The work should be done by specialists only. General practitioners of either dentistry or medicine are liable to do more harm than good when attempting therapeutic X-radiation.

X-rays have been employed in the treatment of pyorrhea alveolaris, but no results have been obtained that have not been gained by the use of the easier-used, better-known, less-dangerous drugs, commonly applied. The incurable cases remain incurable, whether the X-rays are used or not, and, in the cases in which disease is due to local irritants

which can be removed, recovery takes place as a result of the universally known methods of treatment—again, whether the X-rays are used or not. X-rays are used also for treatment of cancer of the mouth and leukoplakia, but such diseases are comparatively rare, and, if treated with the X-rays, the work should be done by specialists. As far as I know, this is the extent of the therapeutic application of the X-rays to diseases of the mouth—an extremely limited application.

In short, my opinion of the value of the X-rays in the practice of dentistry is this: As a means of making dental radiographs they are invaluable; as a therapeutic agent, they are worse than useless.

Requirements of an X-Ray Outfit.

Of what should a dental radiographic outfit consist? Naming the bare necessities for the simplest work—to which the operator may add, as he does the work and feels the need of expediting apparatus—we have: (1) Photographic paraphernalia and supplies, including a dark-room lantern, trays, a glass graduate, prepared developing powder or solution, prepared fixing powder, and films; (2) an X-ray machine or coil; (3) an X-ray tube; (4) a tube-stand; (5) a lead screen; (6) a lead, X-ray-proof box for films and plates.

All the photographic paraphernalia and supplies may be purchased at any photographic or X-ray supply house. The expenditures for photographic paraphernalia and supplies need not exceed $5.

There are three kinds of X-ray machines for the prospective buyer to choose from; the transformer or interrupterless coil (Figs. 15 and 38), the induction coil (Fig. 13), and the high frequency coil (Fig. 14). The so-called "dental X-ray machines" are either small transformers, medium-sized induction coils or large high-frequency coils.

Interrupterless Coils.

The transformers are the most powerful and most expensive X-ray machines on the market. Transformers range in size from the small dental transformer, selling at about $300 or $400, to the very large transformers, such as those used by specialists and found in hospitals, selling at over a thousand dollars.

With transformers, intra-oral radiographs may be made in exposures ranging from a fraction of a second to about 5 seconds; extra-oral radiographs from a fraction of a second to about 10 seconds.

Transformers operate with equal reliability on either a D. C. or A. C. circuit. Take two transformers of an equal efficiency, one for a D. C. circuit and one for an A. C. circuit, however, and the machine for the D. C. circuit will be a larger, more expensive machine than the one for the A. C. circuit owing to the difference in construction. (See Fig. 38.)

Induction Coils.

Induction coils are made in various sizes. The largest ones rival the transformers in power, the smaller ones are not nearly so powerful. Induction coils range in price from about $200 to $600.

With induction coils intra-oral radiographs may be made in exposures ranging from a fraction of a second to about 15 or 20 seconds; extra-oral radiographs from about 1 or 2 seconds to about 45 seconds.

Induction coils operate at their highest efficiency on the D.C. circuit.

High-Frequency Coils.

Most high-frequency, suitcase, X-ray coils are built to sell; not to make radiographs. Only the most powerful of the type are capable of doing good dental radiographic work. I would advise the prospective purchaser to insist on a practical demonstration before investing.

With high-frequency coils which are strong enough to be used for dental X-ray work, intra-oral radiographs may be made in from about 3 to 30 seconds; extra-oral radiographs from about 12 seconds to a length of time so great that the making of extra-oral radiographs becomes impractical.

High-frequency machines operate at their highest efficiency on the A.C. circuit.

The high-frequency X-ray coils range in price from about $150 to $200.

X-Ray-Tubes

A 6 or 7-inch X-ray tube is the proper size to do dental radiographic work. The price of the 6 or 7-inch tube is well standardized, and is from $20 to $35. When purchasing a new X-ray tube for dental work take care not to get one which necessitates vacuum regulation—i. e., vacuum reduction—to keep it from backing up 5 inches of parallel spark.

The Coolidge tube costs $125, and necessitates the purchase of a special controlling apparatus at a cost of about $200.

Tube-Stands

There is a great variety of tube-stands to choose from (Figs. 59, 60 and 61). They range in price from $10 to $150. The small tube-stands or holders which are fastened on to the suitcase coils do not permit of a sufficient range of movement to adjust the tube properly, nor are they substantial enough to hold the tube firmly immovable.

Protection Screens

Lead screens (Figs. 314 and 315) cost from $10 to $30. Even the best lead screens are not backed with lead thicker than 1-16 inch. The writer operates back of a "home-made" screen, the lead of which is ⅛ inch thick, and the 3 x 3 inch window the lead glass of which is 1½ inches thick. The material for this screen cost $15. It is not a

particularly beautiful piece of furniture, and if the time spent in building it be considered worth anything, I did not save money, but the finished screen offers more protection than any I know of on the market.

X-Ray-Proof Box

An X-ray-proof box (Fig. 115) may rightfully be considered a necessity; for all photographic films, plates and paper must be kept in such a box or in another part of the building away from the lighted X-ray tube. Obviously it is impractical to keep the photographic films, plates and paper any great distance from the X-ray apparatus. Hence such a box becomes a necessity. X-ray-proof boxes cost from $5 to $20.

A man may figure from the foregoing approximately what it will cost him to buy the kind of an outfit he wishes to purchase.

The following is, to the best of the writer's recollection, a complete list of the manufacturers of X-ray apparatus in America: The Victor Electric Co., Chicago; the Scheidel-Western X-Ray Coil Co., Chicago; the American X-Ray Equipment Co., New York City; the Edwards Instrument Co., Indianapolis; the Kelly-Koett Mfg. Co., Covington, Ky.; the Wm. Meyer Co., Chicago; the Wappler Mfg. Co., New York City; the Kny-Scheerer Co., New York City; the Campbell Electric Co., Lynn, Mass.; the Vulcan Coil Co., Los Angeles; the H. G. Fischer & Co., Chicago; Noyes Bros. & Cutler, Inc., St. Paul; Geo. W. Brady & Co., plate manufacturers, Chicago; Roentgen Mfg. Co., Philadelphia; Green & Bauer Tube Co., Hartford, Conn.; MacAlaster-Wiggins Tube Co., Chicago; Machlett & Son, tube manufacturers, Chicago; McIntosh Battery & Optical Co., Chicago; Kesselring X-Ray Tube Co., Chicago; the Rogers Electric Laboratories Co., Cleveland, Ohio; the Eastman Kodak Co., Rochester, N. Y.; the Cramer Dry Plate Co., St. Louis, Mo.; Snook Roentgen Mfg. Co., Philadelphia, Pa.; Waite & Bartlett Co., New York City; Columbia X-Ray & Electric Corporation, New York City.

CHAPTER X.

Stereoscopic Radiography.

The word stereoscopic is derived from two Greek words, meaning "solid" and "to see."



Fig. 322. Hand stereoscope in use.

The phenomenon of the stereoscopic picture or radiograph is one very difficult to explain briefly. It is sufficient for us to say here that to gain a stereoscopic effect—that is, to get a picture rich in perspective—we must have two pictures, one for each eye, and observe them with a stereoscope (Figs. 322 and 323). When the two pictures are properly focused in the stereoscope, the observer no longer sees two flat pictures of the same object, but, instead, the single object stands out in clear perspective, just as it would if we looked at the object itself, the two pictures being registered on the retina of either eye and the merging centre of the brain fusing them into one.

To make stereophotographs it is necessary to use a special, double-lens camera (Fig. 324), which takes a picture for each eye simultaneously. Figs. 337 and 338 are stereophotographs.

A moment's consideration of the subject makes it obvious that two radiographs, one for each eye, cannot be made simultaneously. We must



Fig. 323. Large stereoscope made especially for observing stereoradiographs.

place the X-ray tube in the position to make the radiograph for one eye and make the exposure, then shift the tube two and one-half inches (the approximate distance between the eyes), place a new plate or film in exactly the same position occupied by the first plate or film (and this without changing the position of the part being radiographed), and make a second exposure to get the radiograph for the other eye.

Stereoscopic Tube Stand.

To accomplish the proper shifting of the tube a special tube stand or pedestal should be used. There are several such stands on the market known as "stereoscopic tube stands." The one shown in Fig. 61, and again in Figs. 326 and 330, is used by the writer.

Plate Changers.

To accomplish the removal of the first plate after exposure, and replace it with a second plate for the second radiograph, without changing the position of the part being radiographed, it is necessary to use a plate changer (Fig. 325), or a "stereoscopic table" (Fig.

Fig. 324. Double lens camera for making stereophotographs.



Fig. 325. Plate changer.

326), which latter is simply a large plate changer made into a table. The principle of all plate changers is the same. The part being radiographed rests undisturbed on a window of celluloid or thin aluminum, while the plates slide beneath in a tunnel.



Fig. 326. Stereoscopic table and tube stand. H, centering rod.

The plate changer illustrated in Fig. 330, and explained by diagram in Fig. 327, differs from others in that only one five by seven inch plate is used, two pictures, five by three and one-half inches, being made on either end of the plate. A five by seven stereoradiograph (both pictures on the one plate) may be observed with a hand stereoscope (Fig. 322), while all other plate stereoradiographs must be observed with the special stereoscope (Fig. 323).

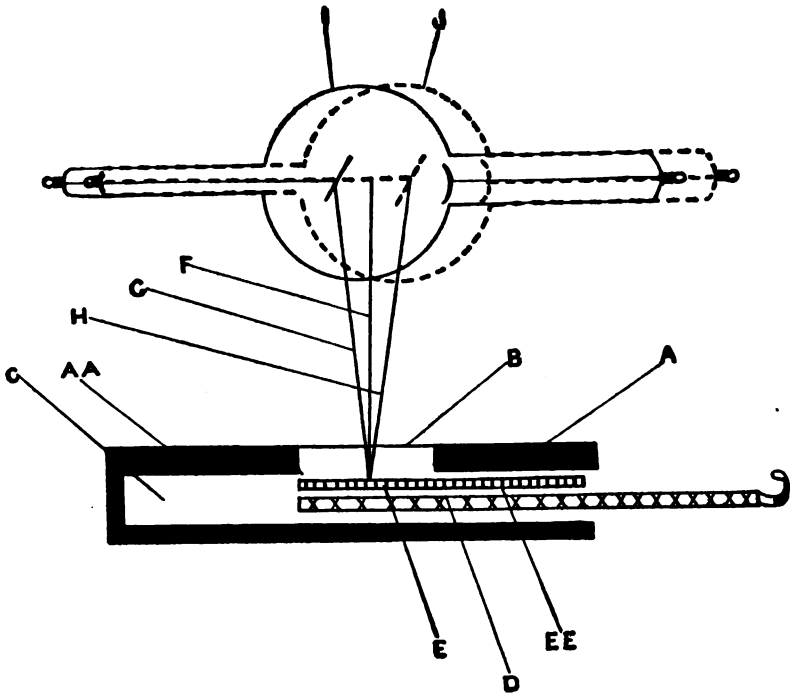

Fig. 327. A and AA, lead which protects the plate against the action of the X-ray. B, window of thin aluminum or celluloid on which the part being radiographed lies. C, end of the tunnel. D, plate carrier. E, end of 5x7 plate on which the first radiograph is made with the tube in position I. EE, end of plate on which second radiograph is made after it is shifted under the window B, and the tube is in position J. F, centering line. G, angle of X-rays with the tube in the first position, I. H, angle of X-rays with the tube in second position, J. The diagram shows the tube being shifted on a line with its long axis. It may be shifted in this manner, or at any angle to its long axis—it makes no difference.

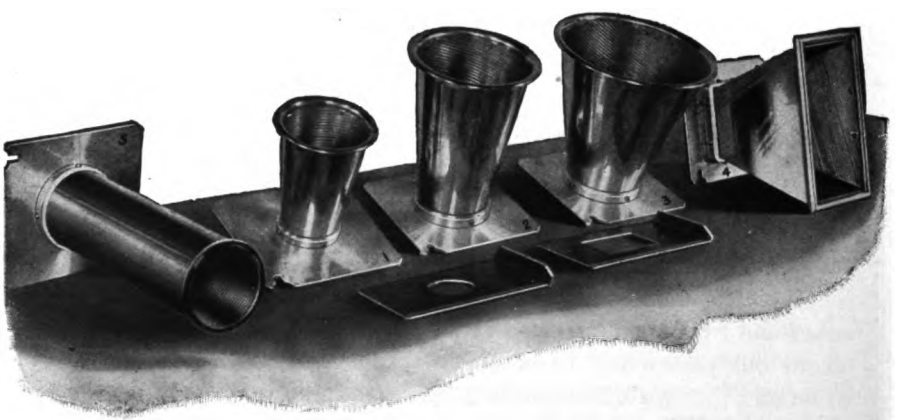

Fig. 328. Compression cones, cylinder and square, and diaphragms for same.

Technic for Making Stereoradiographs.

Let us now take a concrete example and describe and discuss the steps taken in the making of Fig. 339.

Distance. First, what should be the distance between the target and the plate? There are no special rules to follow regulating the distance between the target and the plate when making stereoradiographs. The same results were obtained by the writer with the distance twelve inches as when working at twenty-four inches.



Fig. 329. The lead glass bowl and X-ray tube must be removed while the centering rod is being used. When the stand is "set," the rod is removed and the protection bowl and X-ray tube replaced.

Setting Tube Stand. The first step is to "centre the tube," to place it so that a line (line F of Fig. 327) drawn from the focal point on the target will strike the plate in the center. This may be done with the greatest accuracy by the use of the centering rod (Fig. 326), but the use of the rod is not imperative unless a compression cone or cylinder (Fig. 328) is to be used, as will be described presently.

After centering the tube, when using a stand like the one in Figs. 326 and 330, the stand is "set" so that the tube may be moved one and one-quarter inch on each side of the center to positions I and J of Fig. 327 (see illustration),

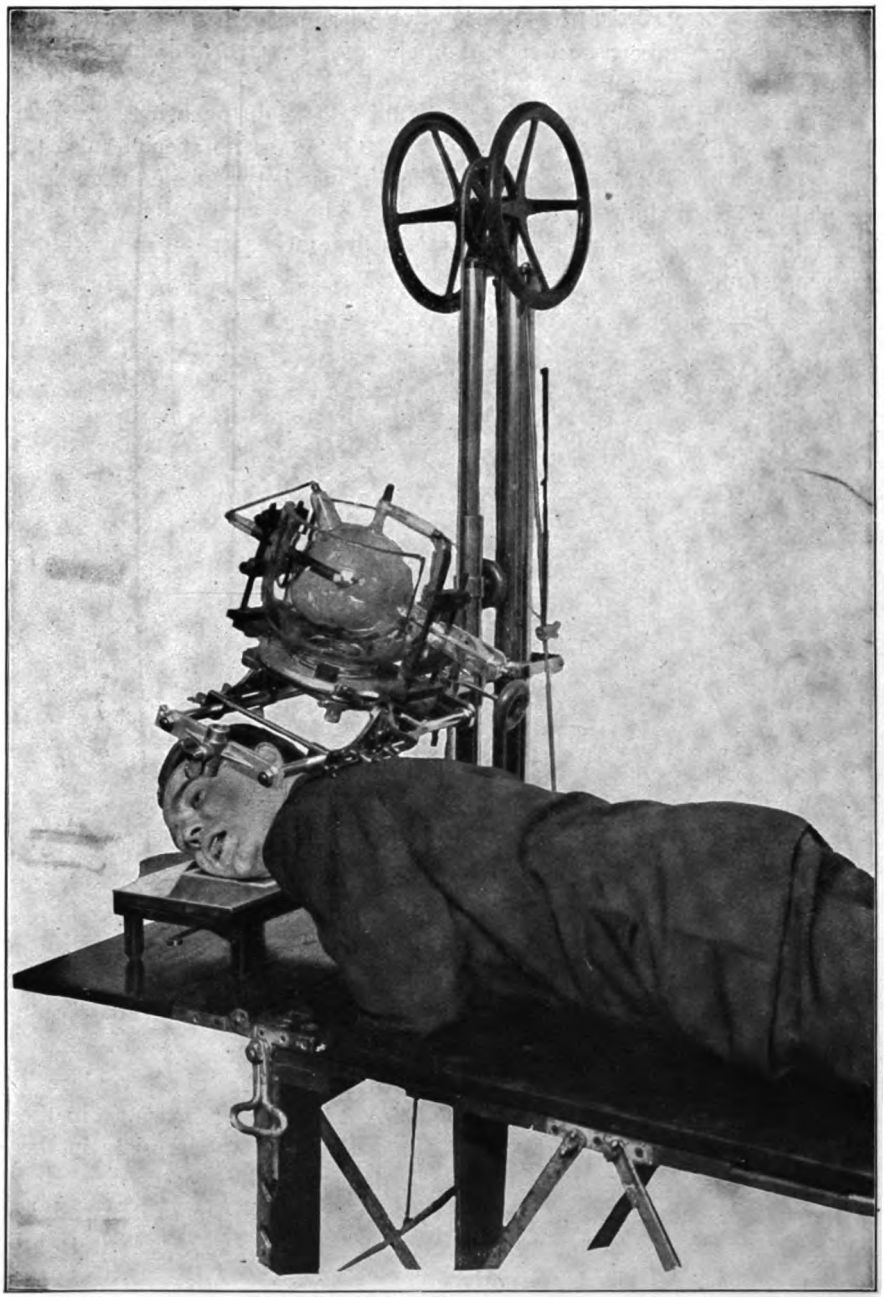

Fig. 330. Pose for making Fig. 344. It is often expedient to have the patient remove the coat and collar for this pose.



Fig. 331. Modified Kny-Sheerer film holder.

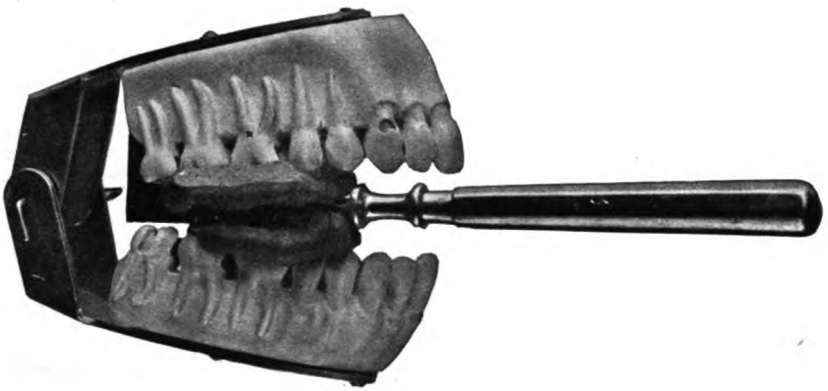

Fig. 332. The film holder shown in Fig. 331 in position.



Fig. 333. Another view of the film holder in position.

Tipping the Tube.

It is not necessary to tip the tube, as it is shifted, in order to have the X-rays strike the object and plate at the proper angles—at the angles at which the eyes of an observer would see the object, because the X-rays emanate from the focal point on the target in diverging lines in all directions. So the *same* X-rays are not used to make the second picture that are used to make the first. If they were, it would be necessary to tip the tube to make them strike the object and the plate at the proper angles. (Observe lines G and H of Fig. 327.) When using a compres-

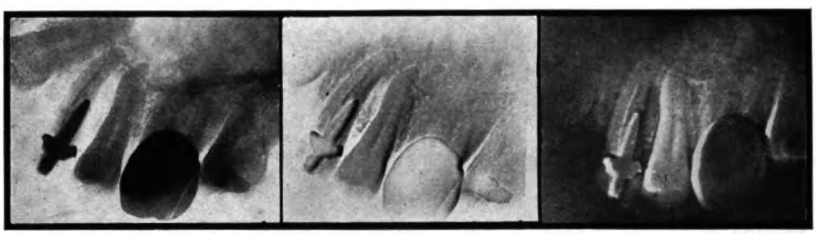

Fig. 334 Fig. 335 Fig. 336

Fig. 334. The photographic print from which this halftone was taken was made from the original negative, or "first picture."

Fig. 335. The same as Fig. 334, except made from "pictures one and two," held together with binding strips.

Fig. 336. The same field as Fig. 334, but made from the "third picture."

sion cone or cylinder we *do* use the same rays to make both radiographs, and hence it becomes necessary to tip the tube as it is shifted. This can be accomplished with accuracy only by the use of the centering rod (see Fig. 329). Thus, if a cone or cylinder is to be used, the tube stand must be "set" not only to shift the tube but to tip it also as it is shifted.

With the tube stand "set," the tube in position I of Fig. 327, and the plate in the position shown in Fig. 327, the first exposure is made. The tube is then shifted to position J, the plate carrier pushed in until the unexposed half of the plate comes under the window B, and the second exposure is made. Since the two radiographs are made on the same plate in this instance, special care should be taken to expose them each the same length of time. Otherwise they will "come up" unequally in the developing solution and radiographs of different densities will result.

If the technic outlined above is followed, it will be found when observing the finished stereoradiograph that we see the part from the position of the tube during exposure. Thus observe Fig. 339, which was taken with the palm of the hand toward the plate, a coin on the back of the hand, a needle under the hand.

If, instead of following the technic as given, the first exposure be made with the tube in position J and the plate as shown in Fig. 327, and the second exposure with the tube in position I, after the plate is shifted; then, when observing the finished stereoradiograph, it is as

Fig. 337. Stereophotograph of the skull of a monkey, from Dr. John J. Kyle's collection of skulls of vertebrates.

though we saw the part from the position of the plate during its exposure (see Fig. 340).

This changing of position of observation may be accomplished also by interchanging the two radiographs—placing the right on the left and the left on the right. Take Fig. 339, for example; interchange the radiographs and the stereoradiograph is the same as Fig. 340; or take Fig. 340 and interchange the radiographs and the stereoradiograph is the same as Fig. 339. The interchanging of radiographs must be done without inverting them, or the change of position of observation will not be accomplished—the stereoscopic effect will remain the same and the part will simply be viewed upside down.

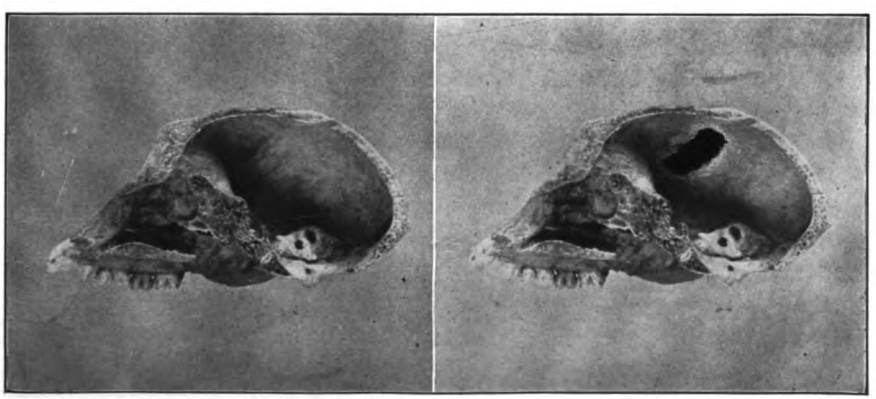

Fig. 338. Sagittal section of the skull of a monkey, from Dr. John J. Kyle's collection of skulls of vertebrates.

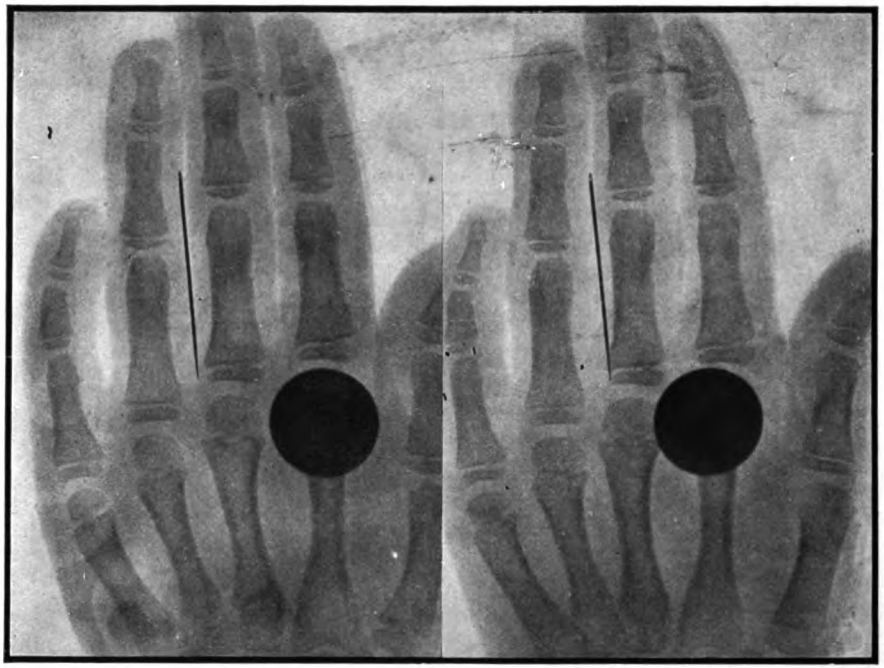

Fig. 339. Showing the coin on one side of the hand, the needle on the other. Here we observe the hand from the position of the tube.

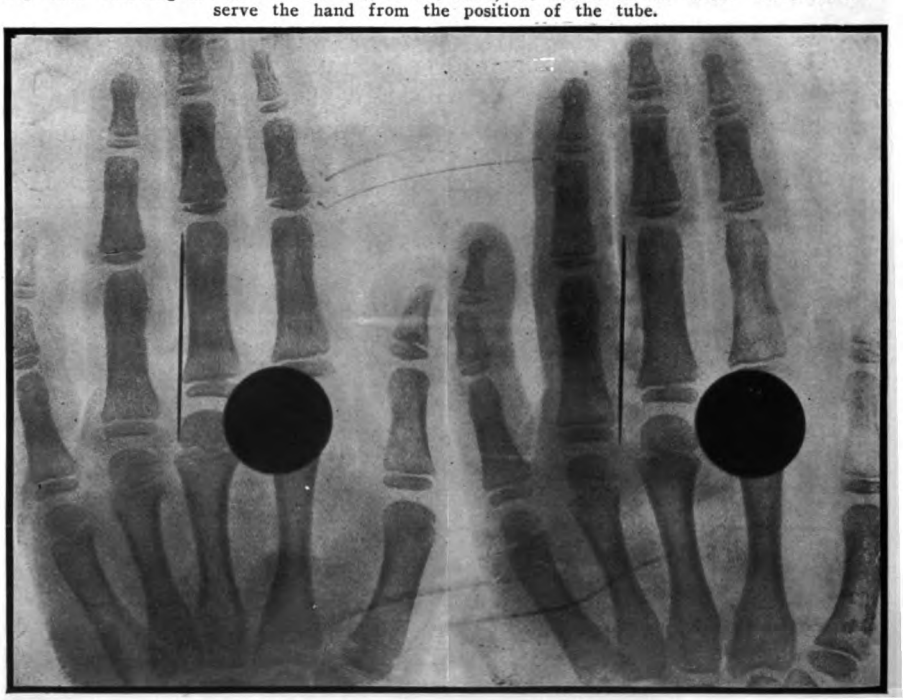

Fig. 340. The same as Fig. 339 except that we observe the hand from the position of the plate during its exposure, instead of the position of the X-ray tube.

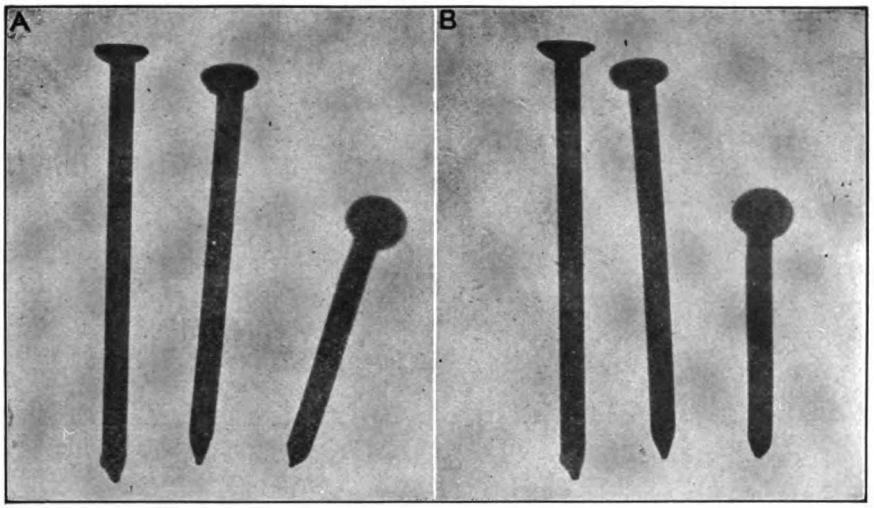

Fig. 341. Three nails of the same size and length. One is in a vertical position, the other two lean toward the observer, at different angles.

Figs. 341, 342 and 343 are the same radiographs mounted differently. No stereoscopic effect at all is seen in Fig. 343, because the tube was shifted at right angles to the long axis of the nails. Had the tube been shifted on a line with the long axis of the nails it would be necessary to observe them as in Fig. 343 to get a stereoscopic effect.

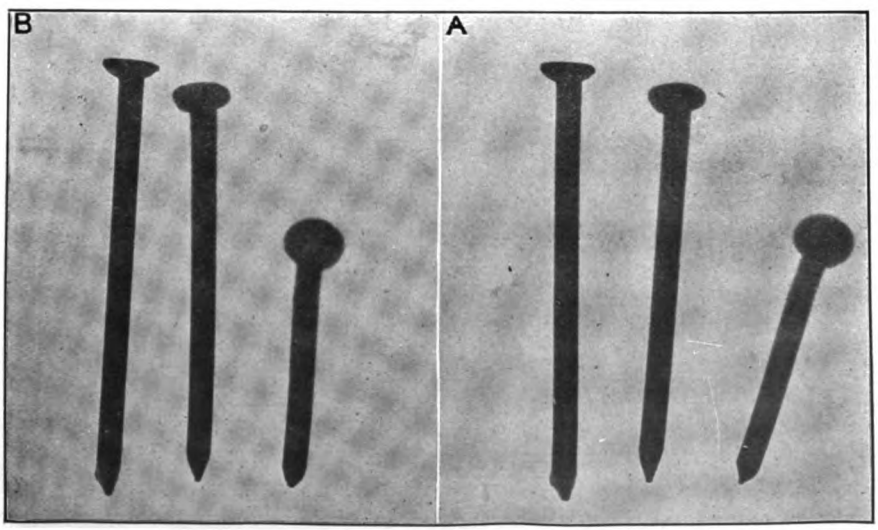

Fig. 342. The same as Fig. 341 except that the individual radiographs are interchanged, the right changed to the left side and the left to the right side. Thus in this stereoradiograph the leaning nails lean away from instead of toward the observer.



Fig. 343. No stereoscopic effect at all is obtained with the radiographs mounted as in this figure.

Special Technic for Dental Stereo-Radiography.

We now come to a more definite consideration of dental stereoscopic radiography. Stereoradiographs of the lower teeth may be made on plates using the plate changer illustrated in Fig. 327. Fig. 344 is such a stereoradiograph. Fig. 344 was made from the pose illustrated in Fig. 330.

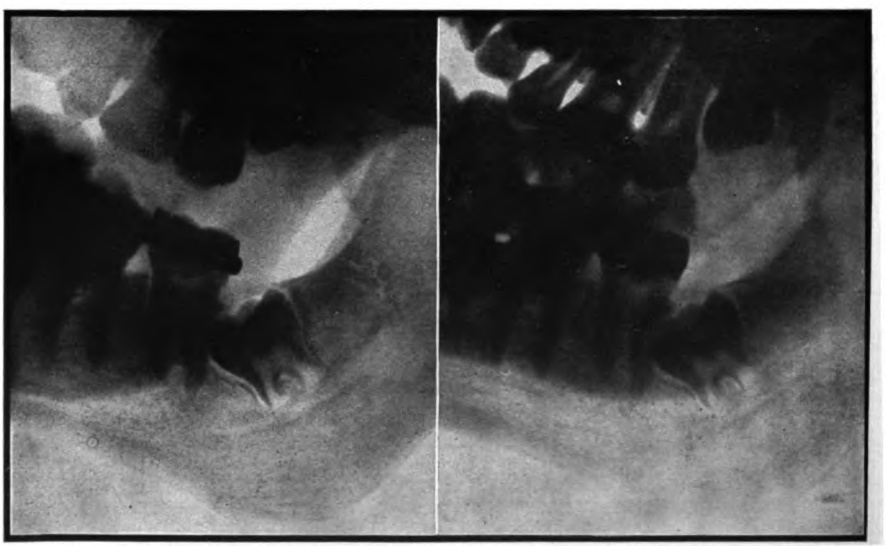

Fig. 344. Though the stereoscopic effect is not very good the figure is representative of what can be done by the method employed to make this stereoradiograph.

When making stereoradiographs on separate plates, like Figs. 345 and 346, it is necessary to use a large plate changer, like Figs. 325 and 326. Figs. 345 and 346 were made on eight by ten inch plates, and the radiographs reduced, as shown in the figures, so that they might be observed with the small hand stereoscope. To observe the original negatives it is necessary to use a large stereoscope (Fig. 323).

Dental Film Holder.

When making dental stereoradiographs, on films held in the mouth during their exposure, the problem of replacing the first film, after its exposure, with a second film, which will occupy precisely the same position as the first, is one fraught with great difficulties. In an effort to accomplish this the writer uses a Kny-Sheerer film holder and modeling composition. The film holder, as I use it, is modified almost beyond recognition (see Figs. 331, 332 and 333). Films may be placed in this modified holder in exactly the same position, and, by the aid of the impression of the occlusal surfaces of the teeth in modeling composition, the holder may be replaced in the mouth in the same position. This film holder is applicable to practically any part of the mouth, but especially so to the molar region.

It is not absolutely necessary, but I prefer to have the patients pose in a recumbent position for all dental stereoscopic work, believing they are less likely to move the head while the films are being changed in this position than they would be if sitting in a chair. Thus the pose for making Fig. 347 was a slight modification only of Fig. 330.

Thanks to the work of Dr. C. Edmund Kells, we now know that it is not necessary to have the two films in exactly the same *position* to make a stereoradiograph like Fig. 348. All that is necessary is to have them occupy exactly the same *plane*. Hence no film holder need be used. The film is placed in the mouth as in Figs. 95, 96 and 103.

Preparation of Radiographs for Study with Stereoscope.

After the two film negatives are made, prints may be made from them, and these prints mounted on cardboard to be observed with the hand stereoscope. Or the negatives themselves may be observed stereoscopically by mounting them on transparent glass, sticking them in place with binding strips such as are used in *passé partout* work.

The distance between the radiographs mounted for stereoscopic observation should be approximately two and one-half inches from a given point in one radiograph to the same point in the other radiograph. Great

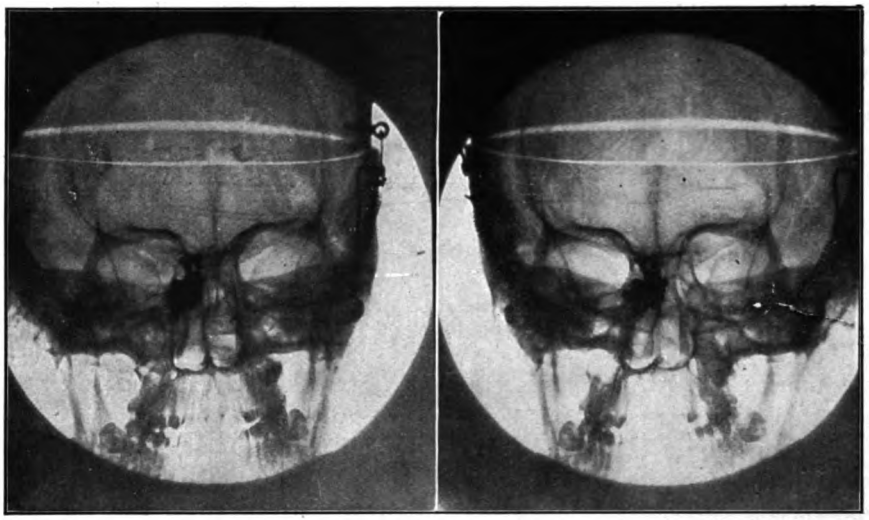

Fig. 345. Antero-posterior view of a dry skull. The right sphenoid sinus is filled with lead shot

accuracy in mounting the radiographs for stereoscopic study is not necessary though preferable.

Landmarks. It is always expedient when making dental stereoradiographs to place some landmark, such as an anchor clamp band or a wire, on the teeth. Knowing then that the screw and nut of the clamp band are on the lingual or buccal side, as the case may be, or that the wire is twisted on the lingual or labial side, as the case might be, we may determine immediately, when

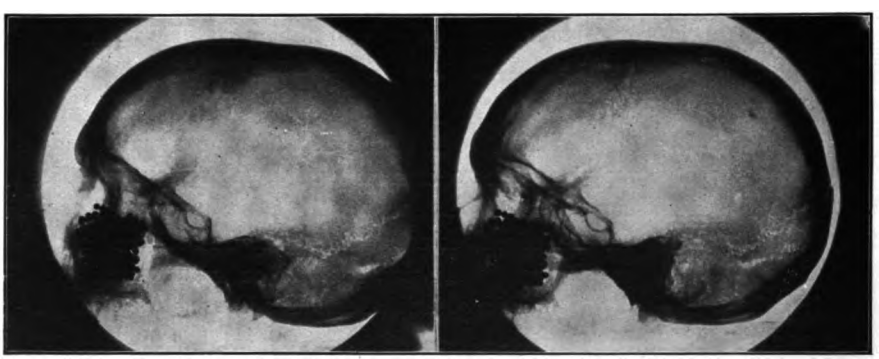

Fig. 346. The reproduction here has lost much of its excellence. When the original negatives were viewed in the illuminating stereoscope, one could look as clearly and directly into the skull as he could into a soap bubble. The dark outline is the antrum nearer the observer filled with lead shot. (Stereoradiograph by A. M. Cole and Raper.)

observing the stereoradiograph, whether we observe the part from the position of the tube or the position of the film.

Dr. Kells states that, as a general proposition, a more perfect stereoscopic effect may be gained if the radiographs are mounted so that the stereoradiograph is observed from the position of the film. This is true, and one reason for it is that, other things being equal, the closer an object

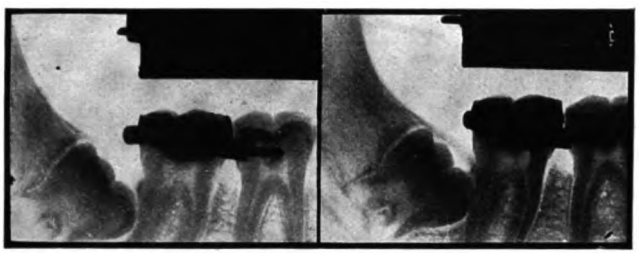

Fig. 347. Impacted lower, left, third molar, viewed from the lingual. The screw and nut of the clamp band are on the lingual.

Fig. 348. Viewed from the position of the film—from the lingual. The temporary cuspid is so much decayed and resorbed it can scarcely be seen. The wire around its neck can be seen clearly. The wire is twisted on the labial.

is to the plate or film the clearer it is outlined in the radiograph. Likewise as we look upon a scene, the closer objects are clearer than those at a distance. Hence, when we observe a stereoradiograph from the position of the film or plate during its exposure, those parts of the stereoradiograph seeming to be closer to us are clearer, while those farther away are less clear.

If the film packets used contain two films each, four negatives will be made, and these may be mounted on clear glass, so that the operator

may observe the part from the position of the film and tube also.

Enlargement of Dental Stereoradiographs.

In direct proportion as things are large or small it is easy or difficult to discern perspective. The parts in dental radiographs are so small that it is difficult to gain perspective. In an effort to overcome this handicap, to an extent at least, Fig. 350 was made. Fig. 350 is an enlargement of Fig. 349. Owing to the loss of

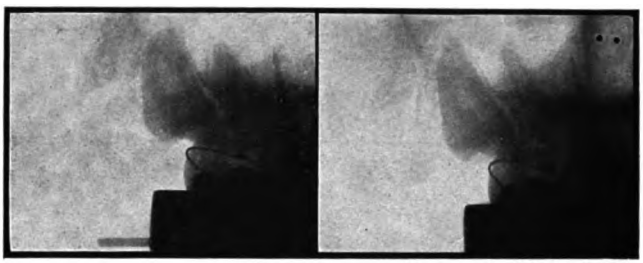

Fig. 349. Impacted upper, third molar, viewed from the position of the tube. The wire passing around the neck of the second molar is twisted on the lingual. The impacted tooth sets to the buccal.

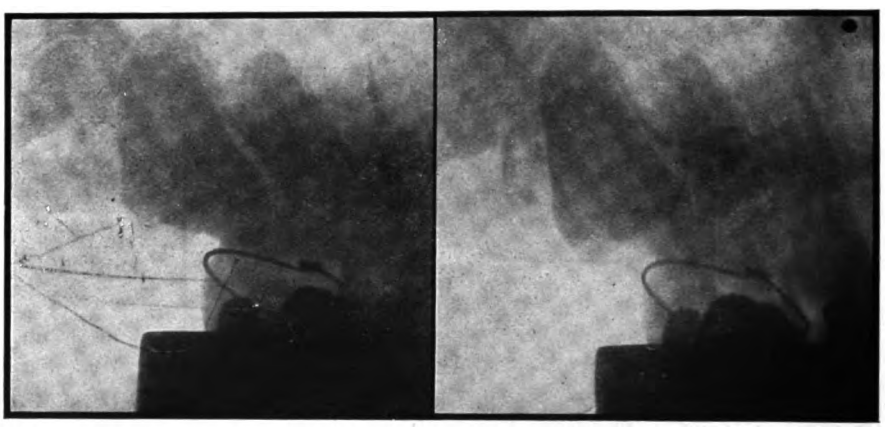

Fig. 350. Same as Fig. 349 enlarged.

detail incident to enlargement there seems little if any advantage in this step. There is none made at the present time, but a magnifying stereoscope would probably be of value for viewing dental stereoradiographs.

Practical Value of Dental Stereoradiographs.

So much for the technic involved in the practice of dental stereoscopic radiography. Let us now consider the results, the practical application and the possibilities of dental stereoscopic radiography. Frankly, the results are discouraging. Considering

the difficulties of practice, and the results obtained at the present time, there is an extremely limited practical application of the stereoradiograph to dentistry. What the future possibilities of dental stereoscopic radiography are I would not attempt to say. My hope is that some day we may be able to stereoradiograph the upper molar roots successfully.

By describing it I think I have proved that the technic involved to do dental stereoscopic work is so difficult that the work should be left entirely to specialists in radiography. Even in the hands of the most skillful it seems, at the present time, that there are several good reasons why it will never be popular. The reasons are: (1) The difficulty, and



Fig. 351. Coins at different distances from a wire screen.

at the same time the necessity, of obtaining two radiographs uniformly rich in detail. (2) The difficulty and necessity of placing two films in the mouth in the same position. (3) The difficulty and necessity of having the patient maintain the same pose while the two exposures are made. (4) The great amount of time consumed to do the work. (5) The parts being so small makes it especially difficult to gain a stereoscopic—a perspective—effect. (6) One of the most important reasons why dental stereoscopic work probably never will be popular, even among specialists, is that we feel no great need of it. The single radiograph is not totally lacking in perspective, and a careful study of it will reveal almost, if not quite, as much as can be seen in the dental stereoradiograph. (7) The stereoradiograph is sometimes misleading. For example, see Fig. 351. To make this illustration three coins were placed on a piece of wire screening, one directly against the screen, the other two resting on cotton

built up to hold them at different distances from the screen. In the stereoradiograph the coin which rests against the screen seems to stand out from it a short distance.

Some day perhaps we may so modify and perfect our technic that the stereoradiograph will be of indispensable value (1) in observing the three roots of upper molars; (2) in seeing a wire passing through a perforation to the labial, buccal or lingual; (3) in some particular cases

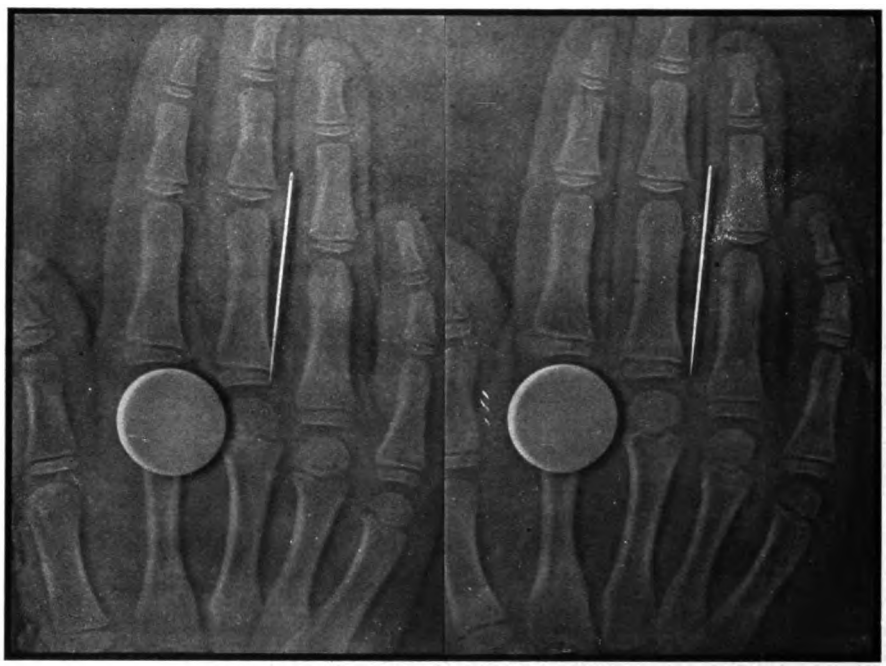

Fig. 352. Same as Fig. 339 made "plastic."

of impacted teeth to show more exactly their location, and so aid in the extraction; (4) in showing the orthodontist when he may move the coming permanent teeth by moving the deciduous teeth; (5) in determining more exactly than can be done with the single radiograph the size and location of a pus cavity or cyst; (6) in cases of fracture of the mandible; (7) in locating exactly bone "whorls," calculi in the glands or ducts of glands and foreign bodies in the antrum; (8) in learning the size, shape and location of the antrum as an aid in opening into it; and (9) in cases of tumor to locate more definitely the offending body.

Plastic Radiography.

There is no one thing which so limits the usefulness of the radiograph as its lack of good perspective. Hence our interest in stereoscopic radiography. Hence, also, our interest in plastic radiography.

Plastic radiography is a method of making radiographs in such a way that the parts stand out in *bas relief*. A better name than plastic

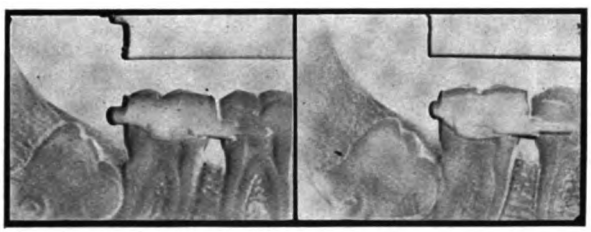

Fig. 353. Plastic reproduction of Fig. 347.

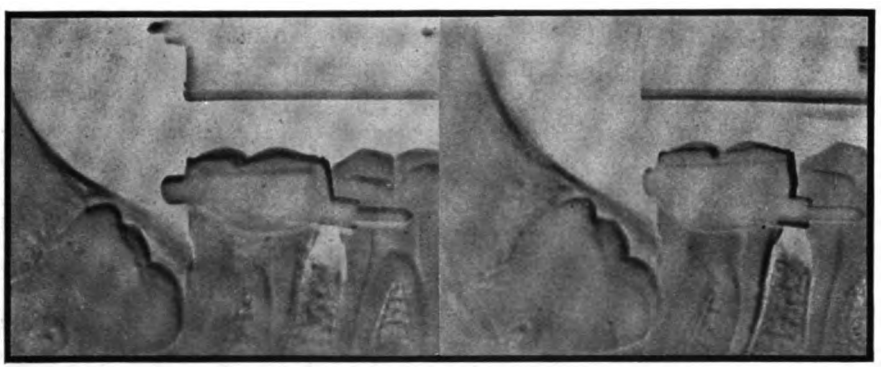

Fig. 354. Fig. 353 enlarged.

radiography would have been trick radiography. I describe the method simply as a matter of interest. It is of no practical value whatever.

Technic of Plastic Radiography.

The following are the steps in making a plastic radiograph. The negative is made as usual. For convenience in referring to it we shall call the negative the *first picture*. From the *first picture* another picture, the *second picture,* is made on a photographic plate, the technic for doing this being the same as for making contact lantern slides. The *first* and *second pictures* are now placed together, non-sensitive sides in apposition, held up to the light and moved about until the parts of the two pictures overlie one another exactly. They are now held immovable while an assistant sticks them together with

paper binding strips. Next, place them in a printing frame and make a photographic print on paper (see Figs. 335, 352, 353 and 354). While the exposure is being made the printing frame must remain immobile and the light must pass through pictures number one and number two and strike the photographic paper at an angle of about ninety degrees.

Instead of allowing the light to pass through pictures one and two and strike the photographic paper at an angle, the same result may be accomplished by allowing the light to pass straight through pictures one and two, if at the time they are stuck together the two pictures are almost, but not quite, in perfect overlying opposition.

Instead of making the print on paper from pictures one and two, another picture, number three, may be made on a plate, and from this *third picture* photographic prints made (Fig. 336).

Plastic radiography is simply a scheme of shading radiographs Nothing *more* can possibly be seen in the plastic production than could have been seen in the original negative, though, perhaps, something may be seen *more easily.* To the man unacquainted with the reading of radiographs the plastic pictures seem much clearer, but to the man of experience it is not so clear, for there is an unavoidable loss of detail in the making of the plastic reproduction.

Plastic Stereoradiographs.

Figs. 352, 353 and 354 are plastic stereoradiographs. It is interesting to pause and consider the number of steps necessary to make Fig. 354. First, the negatives were made; from these the "second picture" of the plastic method, then the prints on photographic paper, from which enlargements were made, and then the halftone.

In concluding let me say that the properly made, intelligently read single radiographic negative is of the utmost importance and value in the practice of dentistry. Let us not forget this, and let us not decry the radiograph because our efforts in stereoscopic and plastic work fail to make it absolutely infallible.

---

* For a further consideration of dental stereoscopic radiography see Appendix, Chapter X.

APPENDIX

APPENDIX TO CHAPTER I

Electricity

To make the meaning of the word " phase," used as an electrical term, clear, would require the use of unnecessary space in this volume.

The operator need not bother about the phase of his supply currrent. *As it reaches him* it is single phase and X-ray machines are always built for the single phase current.

APPENDIX TO CHAPTER II

X-Ray Machines

Some eight or ten special dental X-ray machines have been placed on the market within the past three years. The machines represent, in



Figure 355A.—Special dental X-ray machine. Transformer or Interrupterless type. Size: 24 inches wide, 26 inches deep, 59 inches high.

their construction, the three standard types of X-ray machines, viz., the transformer, or interrupterless coil. the induction coil and the high-frequency coil.

Figure 355B.—Special dental X-ray machine. Transformer or Interrupterless type. Size: 17 inches wide, 23 inches deep, 37 inches high.

Figures 355, A and B, and 356 are representative of the dental transformer type.

Figures 357 and 358 are representative of the dental induction coil type. The tube on top of Fig. 357 is a valve tube.

Figure 359 is a dental X-ray machine of the high-frequency coil type.

With some types of the high-frequency X-ray coil (Fig. 360) the operator has at his disposal the high-frequency current for electrotherapeutic work.

The value of the high-frequency current as a therapeutic agent in the practice of dentistry has not been satisfactorily established. I would

Figure 356.—Special dental X-ray machine. Transformer type, with high-frequency—*i. e.*, electrotherapeutic—attachment on the top. Size: 21 inches wide, 20 inches deep, 71 inches high.

suggest, however, that the man with such a current at his disposal might experiment with it using it with the idea that it is a cellular massage.

Some coils are so constructed that the coil proper may be placed on a shelf on the wall, up out of the way, the controls of the coils or switchboard being mounted elsewhere and within easy reach. With an X-ray machine installed in this way "overhead wiring" is usually necessary

The principle of the overhead wiring system is illustrated in Fig. 361. The terminals of the coil are attached to the overhead wires. On the



Figure 357.—Special dental X-ray machine. Induction coil type. Size: 15 inches wide, 28 inches deep, 36 inches high.

overhead wires are the trolley reels which fasten to the tube. The convenience of overhead wiring is great.

It will be observed that on Fig. 362 there are the usual terminals, viz., the positive and negative secondary terminals and the " dead " or " false "



Figure 358.—Special dental X-ray machine. Induction coil type. Size: 30 inches wide, 17 inches deep, 44 inches high.

terminal to which the vacuum reducing lever is attached. Back of these terminals are two others. It is interesting to know what these two extra terminals are for.

They are connected directly to the terminals of the secondary winding



Figure 359.—Special dental X-ray machine. High-frequency coil type. Size: 24 inches wide, 16 inches deep, 52 inches high.

of the transformer before rectification, so that the current delivered at these two terminals is high potential alternating.

In addition to the safety valve action, they have two other functions. One is to indicate when the disc switch is out of synchronism. While the current " slopping " across these two terminals occasionally, would not indicate anything wrong with the switch, if the current slops across reg-

ularly and in considerable quantity, it is a certain indication that the disc has gotten out of synchronism.

The remaining function is to deliver unrectified alternating current to a high-frequency attachment, should the user of the transformer desire to operate a high-frequency apparatus in connection with the transformer. (Fig. 356.)



Figure 360.—X-ray and electrotherapeutic machine. High-frequency type. Size: 24 inches wide, 18 inches deep, 48 inches high.

Dental X-Ray Unit.

Figure 363 illustrates what is called a dental X-ray "unit." There are several points of interest regarding its construction. Let me describe the one illustrated.

Electrically it is an induction coil with an electrolytic interrupter. The first "units" were all induction coils. (Recently "units" of the Tesla or high-frequency type have been placed on the market.) Being small it is easily movable and so, with the tube fastened to the adjustable upper part, it acts as a tube stand.

The X-ray tube used with this unit is a special one. First, a valve tube to cut out inverse is built into it as is indicated by the illustration (Fig. 363) which shows two, instead of the usual one, bulbular part. Second, for protection the bulbular part of the X-ray tube proper is made of lead glass save for a window of ordinary glass through which the X-rays are directed on the part to be radiographed. (When in operation the tube fluoresces blue except just at the window of ordinary glass which

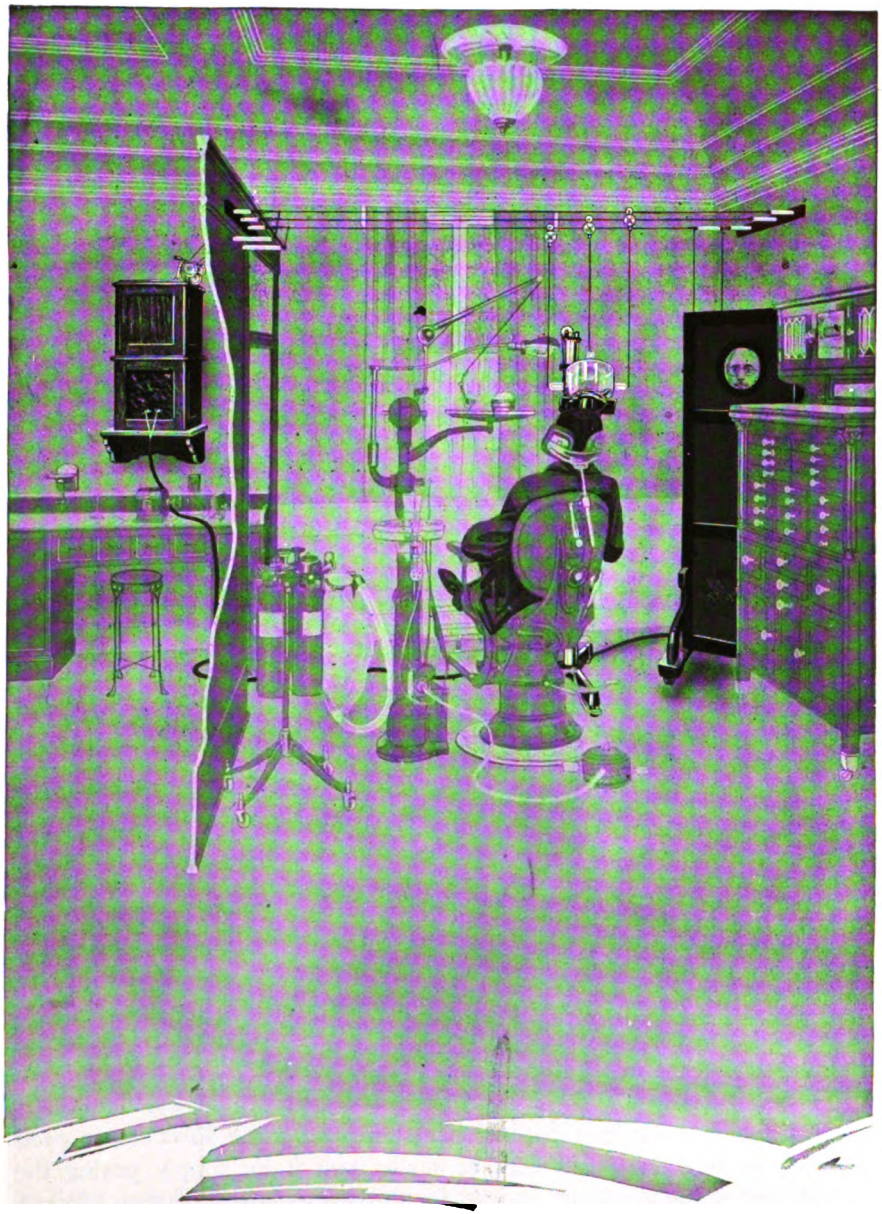

Figure 361.—Overhead wiring system.

gives the usual green color.) Third, a small glass compression cylinder is attached as part of the tube. Fourth, the regulating chamber and the cathode end of the tube are connected with a special connection the function of which connection is to allow "just enough" current to pass

Figure 362.—

through it, and so through the regulating chamber, to keep the vacuum of the tube constant, *i. e.*, to keep it from raising.

It will be seen from the foregoing that the idea of the "unit" is simplification for the operator and indeed *as long as all parts are in good working order* radiographs may be made with it by simply posing the patient and switching on the current for the proper length of time. When it becomes necessary to make some adjustments, however, the operator will then feel the need of the information set forth in the first one hundred pages of this book.



Figure 363.—Dental X-ray "Unit." Size: 18 inches wide, 18 inches deep, 46 inches high.

New Type of X-Ray Machine.

The "Hogan silent Roentgen transformer" is said, by its manufacturer, to be a transformer or interrupterless type of X-ray machine which is so constructed that it rectifies its output current without a synchronous rectifying disc or switch. Other manufacturers tell me they may put such an X-ray machine on the market.

The X-Ray Outfit Admitting of the Most Perfect and Reliable Control.

An X-ray outfit consisting of a transformer, a Coolidge X-ray tube and an automatic time switch admits of the most perfect and *reliable* control, with the least effort on the part of the operator. Such an outfit is expensive.

APPENDIX TO CHAPTER III

X-Ray Tubes and the X-Rays

Beginners in X-ray work seem unable to reconcile themselves to accept the statement that the cathode stream passes from cathode to target. See page 49. So let me emphasize the statement: *The cathode stream flows* in the *opposite direction* to the flow of the electricity through the tube.

Recently it has been satisfactorily proved that the X-rays can be reflected. This is of only academic interest, however, since no practical use of the knowledge has so far been made. The operator back of a lead screen, using a mirror to observe his tube and patient, must not think from this that the mirror will reflect the X-rays to him as it reflects the image of the tube and patient.

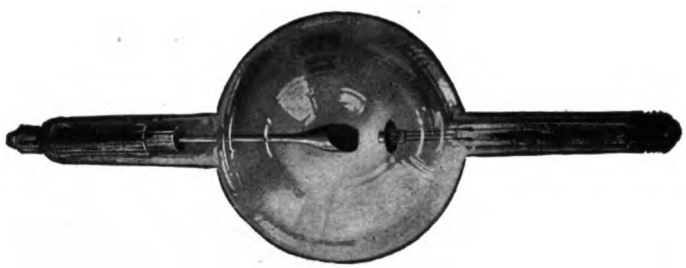

Figure 364.—Coolidge X-ray tube.

Coolidge X-Ray Tube.

The new Coolidge X-ray tube (Fig. 364) built by W. D. Coolidge in the research laboratory of the General Electric Company, differs radically from all other X-ray tubes.

Vacuum Control.

It differs from the ordinary X-ray tube described in Chapter V so much that it is difficult to compare the two. When the current will not pass through an ordinary X-ray tube, as we wish it to, we lower the vacuum of the tube by liberating gases in it, and we may then force a variable amount of milliamperage through it; depending on where we place the lever of the

X-ray machine rheostat. No current at all will pass through the Coolidge tube until the tungsten filament or coil (Fig. 365) is heated, and then not more than a certain amount will pass through, regardless of how far the lever of the rheostat of the X-ray machine is advanced. The degree of heat of the tungsten filament controls the limit of the milliamperage which may be sent through the tube.

The vacuum of the Coolidge tube is very high and remains practically the same always. Temperature of the tungsten filament—*i. e.*, ionization —and *not changes* in degree of vacuum due to gas liberation, governs the amount of milliamperage which may be sent through a Coolidge tube.

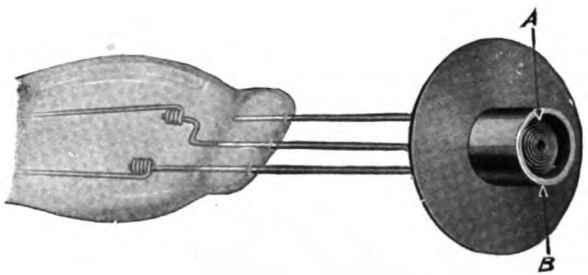

Figure 365.—Cathode of Coolidge tube.

Fluorescence. When a Coolidge tube is seen in operation for the first time the observer is surprised to find that it does not fluoresce. The heated filament is seen and, if the current is left on long enough, the target may get red or white hot, but the green fluorescence of the ordinary X-ray tube does not occur at all.

If the polarity of the machine is wrong, it will be shown by the fact that the milliammeter will register no current, regardless of how high the filament temperature may be, for the Coolidge tube allows current to pass through it in only one direction; from filament to target.

Heating. In the practice of radiodontia one need have little fear of overheating a Coolidge tube. The tube will take greater quantities of current over a longer period of time than the radiodontist will find it necessary to use, unless the Coolidge tube is one of the finest focus, when, to keep from burning the target, not more than about 25 milliamperes should be sent through the tube.

Construction of Coolidge Tube.

The Coolidge tube has no assistant anode or regulating chamber; it has only a cathode and an anode or target. Figure 365 is an illustration of the cathode.

"The filament (A) Fig. 365, which forms the cathode, consists of a flat closely wound spiral of tungsten wire. By means of a rheostat the heating current sent through the filament may be varied from 3 to 5 amperes.

"The focusing device consists of a cylindrical tube of molybdenum (B), Fig. 365, mounted concentric with the tungsten filament and with its inner end projecting about 0.5 mm. beyond the plane of the latter. Besides acting as a focusing device it also prevents any electron discharge from the back of the cathode.

Figure 366.—Anode of Coolidge tube.

"The anti-cathode or target, Fig. 366, consists of a single piece of wrought tungsten (C) attached to a molybdenum rod (D) and supported by a split iron tube (E).

Method of Heating Cathode Filament.

"The cathode filament may be heated by means of a storage battery or a small transformer. The battery is universally applicable. The transformer can be used wherever there is alternating current available, either from the supply mains or from a rotary converter. In case it is necessary to run from the same source of supply as the X-ray transformer the filament current transformer is not to be recommended for radiographic work where there is much line drop. In many cases, however, there are two separate sources of alternating current supply and then the filament transformer is to be recommended for everything.

Connections.

"In Fig. 367 the tube is shown properly connected to the storage battery and the X-ray machine. It must always be borne in mind that the entire battery circuit is brought to the full potential of the tube when the tube is energized for use and that the wires from the battery should therefore be

as thoroughly insulated from the patient and the ground as the tube itself.

"The full circuit is shown in the schematic diagram, Fig. 367, in which S is the parallel spark gap, M the milliammeter, B the storage battery, or small transformer, R the rheostat for controlling the current in the filament circuit, and A an ammeter for measuring this current. The best technic for the Coolidge tube demands the use of an ammeter in the filament circuit. The meter should have a 5-ampere scale large enough

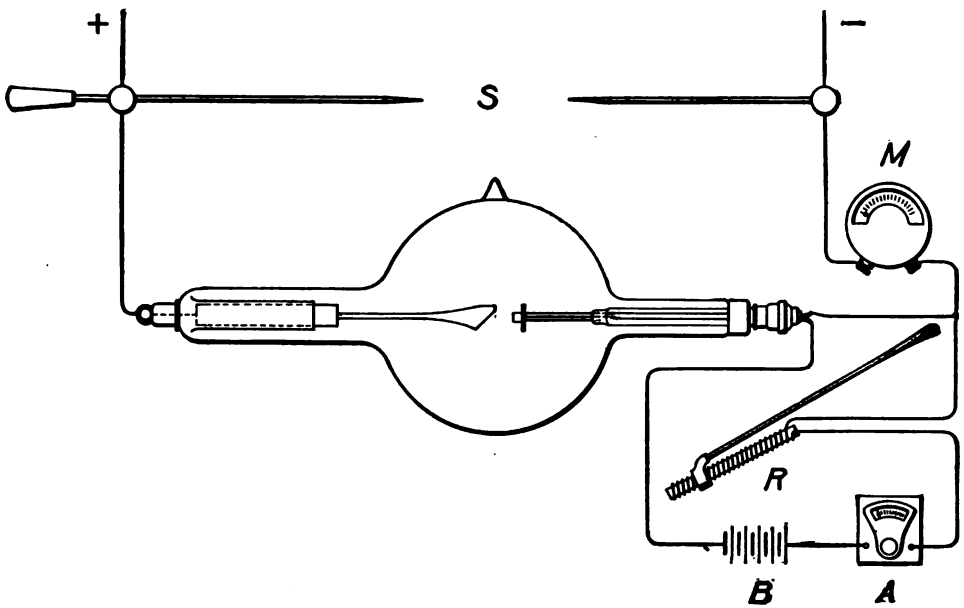

Figure 367.—Diagram of Coolidge tube connections.

to be easily and accurately read. The meter should be located as close to the operator as possible and in such a way that it can be easily read from the operating position.

Technic for Using Coolidge Tube.

"The technic of various operators and the sources of excitation of the tube vary so much that it is difficult to make detailed suggestions which are universally applicable. The following general considerations, however, may be of value:

'Bear these two things in mind: First, the higher the filament current—*i. e.*, the hotter the filament—the greater the milliamperage which can be sent through the tube. Second, the higher the voltage backed up by the tube—*i. e.*, the longer the parallel spark backup—the greater the penetration of the X-rays produced.'

"A simple method of starting radiographic work with the Coolidge tube is as follows:"

'Take a case, for example, where the operator has been doing his work with the rheostat on the 10th button with his tube drawing 30 milliamperes. In this case, all that is necessary with the Coolidge tube is to set the main rheostat on button 10, light up the filament in the tube, having the filament rheostat handle pushed as far away as possible—*i. e.*, in—flash the main switch on as often as necessary to get milliampere reading, and pull on the handle which lets amperage into the filament and heats it, until the tube is seen to be drawing 30 milliamperes. Having once adjusted the tube to this condition the operator should read and record the amperage in the filament circuit. To reproduce the condition he then needs merely to adjust the filament current to this same amperage and set his X-ray machine rheostat on the same button. In this way, after his technic is once established, he never tests his tube out by operating it, but is guided solely by the ammeter and the X-ray machine rheostat button.'

"In other cases, the radiographer will be accustomed to adjust his tube by means of milliammeter and the parallel spark gap. This procedure can be applied equally well to the Coolidge tube, and will naturally be the one first used in all cases where the operator is not familiar with his machine."

Knowing that 20 milliamperes with a 5-inch parallel spark back-up is desired, start by setting the parallel spark gap at 5 inches. Light the filament of the Coolidge tube having all the resistance of the Coolidge control rheostat in—*i. e.*, the handle of the rheostat pushed in—and so, the least possible current in the tube filament. Start with the X-ray machine rheostat on a low button. Flash the main switch of the X-ray machine whenever readings of the milliammeter are desired and manipulate the Coolidge control rheostat and the X-ray machine rheostat alternately until 20 milliamperes are passing through the tube and a spark will jump only a 5-inch parallel spark gap and no more. "Widen the parallel spark gap now and everything is set ready for the radiographic exposure to be made. As before the operator reads and records the amperage in the filament circuit and the number of the rheostat button on the X-ray machine and is subsequently guided solely by these records."

Records for each Coolidge tube must be made, as records of one tube cannot be applied to another and the same radiographic results obtained.

"The tube may be safely run with the target at white heat. If excessively high energy inputs are employed, the tungsten at the focal spot melts and volatilizes. This results in a sudden lowering of the tube

resistance and in blackening of the bulb. The instability in resistance disappears instantly upon lowering the energy input, and no harm has been done to the tube—that is, unless it is to be used for the production of the most penetrating rays which it is capable of emitting. In this case, a heavy metal deposit on the bulb is undesirable, as it interferes with smooth running at high voltages.

"The tube should not be run with voltages higher than that corresponding to a 10-inch spark gap between points (that is, it should not be made to back up more than a 10-inch parallel spark).

"For long continued running in an enclosed space and with heavy energy inputs, it will be necessary to provide some means of cooling the glass, as by a small fan or blower. The glass can, however, safely be allowed to get very hot. It is all right so long as it does not soften and draw in.

"In running the tube on an induction coil, a valve tube should be used in case heavy energy inputs are to be employed. So long, however, as the temperature of the focal spot is not made to approximate that of the cathode, the tube will satisfactorily rectify its own current.

"The tube can be furnished with three sizes of focal spots: broad, medium and fine. For therapeutic, fluoroscopic and most radiographic work the medium focus tube will be found suitable. If extremely sharp definition is desired, the fine focus tube should be used."

The Coolidge tube is not in more general use for two reasons: (1) It is so much more expensive than the ordinary gas tube. (2) It produces a great number of vagrant X-rays (the entire stem of the anode gives off X-rays) which sometimes interfere with the making of clear radiographs.

Cathode Collar or Jacket Tubes.

The two common injuries from sending too much current through an X-ray tube are: (1) Overheating of the glass and consequent puncture in the region of the cathode. (2) Burning of the target at the focal spot. To overcome the danger of puncture in the region of the cathode, tubes are now made with a cathode collar, or jacket, of steel. (See Fig. 368.) Tubes of this design are capable of transmitting much more current than the ordinary tube without danger of puncturing in the cathode region. Tubes with cathode collars, which the writer has seen in operation, show a light ring in the inactive hemisphere giving the tube somewhat the appearance of a tube with inverse current passing through it.

The finer—*i. e.*, the smaller—the focal point, the place where the cathode stream strikes the target, the more likely burning of the target

is to occur. Thus a tube with a very fine focal spot should have not more than about 20 to 40 milliamperes sent through it, while the same sort of a tube with a medium or broad focal spot may transmit 80 to 200 milliamperes without injury to the target.

Tungsten targets are capable of withstanding much more heat than platinum targets.

Figure 369 shows a ring in front of the target. The functions of the ring are: (1) To sharpen the focal spot. (2) To overcome the

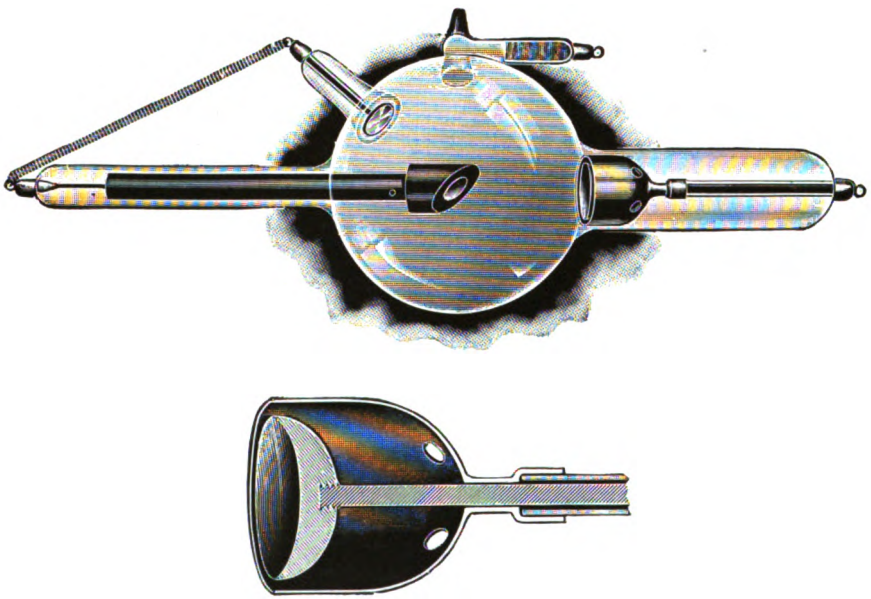

Figure 368.—X-ray tube with protection cathode collar.

initial resistance in tubes of high vacuum. (3) To decrease uneven heating at the cathode.

Valve Tube. Figure 370 is a type of valve tube differing in mechanical construction from Figs. 51 and 52. A valve tube of this type is built into the X-ray tube illustrated in Fig. 83.

Combination Tubes. Some special feature, or combination tubes are now being manufactured to operate particularly on "Radiographic Units." These tubes may have built into them as an integral part any one or all of the following: (1) a valve (2) a protection bulb of lead glass (3) a cylinder, through which

the X-rays are directed on the part being radiographed, to cut out secondary X-rays (4) a filter, consisting of a sheet of aluminum in the bore of the cylinder (5) a special vacuum-regulating device consisting of a connection between the regulating chamber and the cathode end of

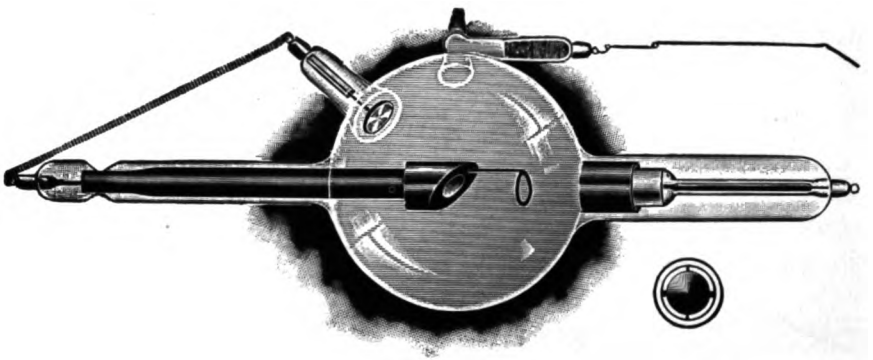

Figure 369.

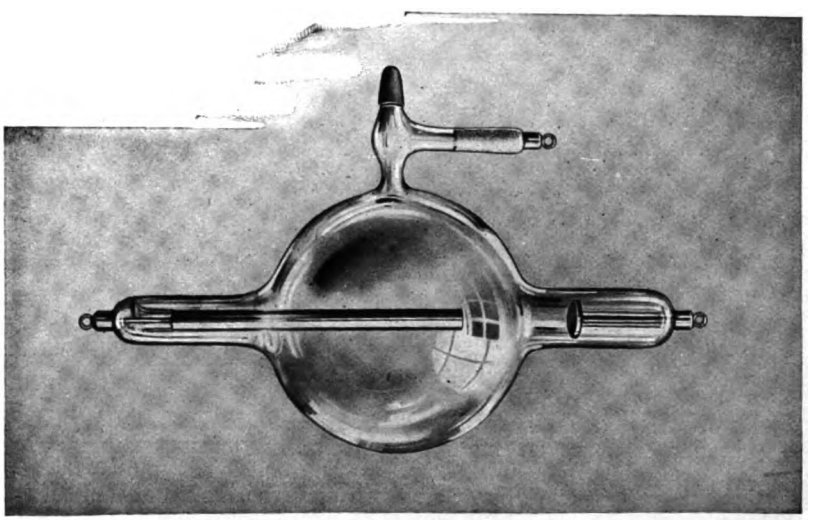

Figure 370.—Valve tube.

the tube, which connection is of the proper electrical resistance to carry the right amount of electricity to keep the vacuum of the tube the same.

In principle, the connection between the tube-regulating chamber and the cathode end of the tube is a tube-regulating spark gap which is set at a definite distance. As I have mentioned elsewhere (Chapter V) the

tube-regulating spark gap may be set at a certain distance and left there while the tube is in operation. Since the resistance of the tube-regulating spark gap, which is to be set while the tube is in operation, should be less as the tube gets older, it is not quite right for manufacturers to claim that the special connection now under consideration makes the control of the tube "absolutely automatic." When the tube is new its vacuum control may be automatic, but as it gets old manipulation (*i. e.*, lessening of re-

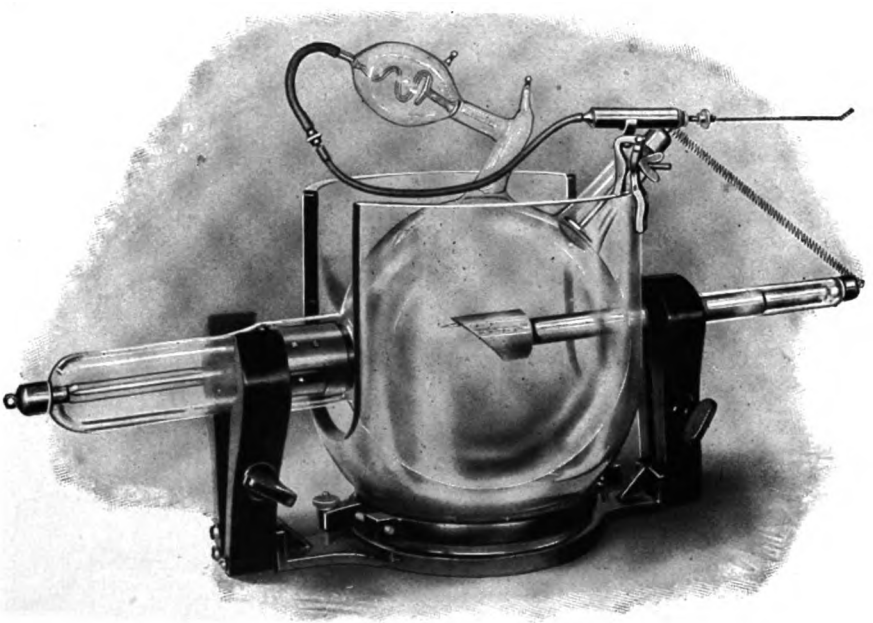

Figure 371.—Hydrogen X-ray tube.

sistance) of the special connection, between the regulating chamber and the cathode end of the tube, becomes necessary. The greatest, or as I see the thing, the only advantage of the "special automatic (?) vacuum control connection" is that it admits of reduction of the vacuum of a tube without any sparks occurring, as they do at an atmospheric tube-regulating spark gap. This is a definite advantage when the tube-regulating spark gap is at the tube, for then there is no disagreeable sparking in the vicinity of the patient, but is not an advantage if the tube-regulating spark gap is on the X-ray machine. (See page 49.)

Hydrogen Tubes.

Figure 371 illustrates a type of tube known as the "hydrogen tube" because the gas used to lower the vacuum is hydrogen. Some hydrogen tubes admit of regulation in either direction; that is, their vacuum may be either raised or lowered while others admit only a regulation of lowering. Figure 371 shows the special device by means of which the vacuum is regulated instead of the usual tube-regulating spark gap.

What Vacuum Tube to Buy.

The writer's experience with X-ray tubes has taught him, when purchasing a new tube, never to buy one which backs up *more than five* inches parallel spark. One which backs up only three inches parallel spark, with use, will soon be backing up more. But a tube which backs up more than five inches parallel spark when new will soon be backing up so much parallel spark—*i. e.*, will soon have such a high vacuum—that the best dental radiographic results cannot be obtained with it.

Making Dental Radiographs.

New Pose for Frontal, Ethmoidal, and Maxillary Sinuses.

The advantage of having a well sectioned skull, to the operator who wishes to do sinus work, cannot be overestimated. Before one becomes proficient in this work, experimentation on a skull is necessary.

A comparatively new and most excellent pose for making antero-posterior radiographs of the frontal sinuses, ethmoid cells, and antra is illustrated in Fig. 372. Fig. 373 is a diagrammatic drawing explanatory of Fig. 372.

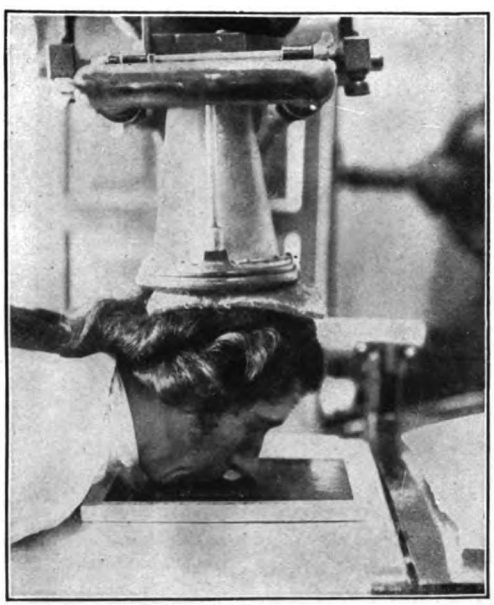

Fig. 372. Pose for frontal sinuses, antra and ethmoids. (Published by courtesy of *Interstate Medical Journal.*)

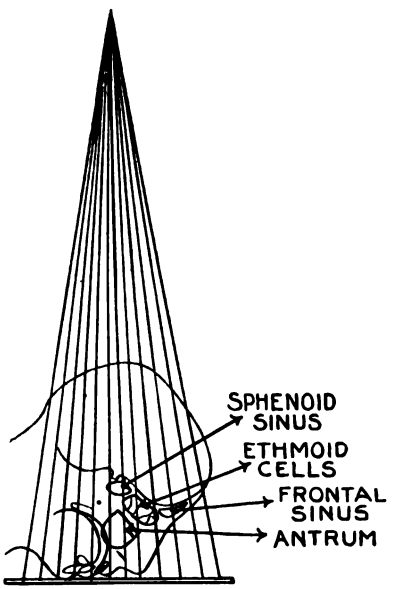

Fig. 373. Diagrammatic drawing explanatory of Fig. 372. (*Interstate Medical Journal.*)

Figure 374 is a radiograph made from the pose illustrated in Fig. 372, and Fig. 375 is a diagrammatic drawing explanatory of Fig. 374.

Sphenoid Sinus.

Figures 376, 377 and 378 illustrate poses for sphenoid exposures.

Mastoids.

Figure 379 illustrates a pose for mastoid exposures.

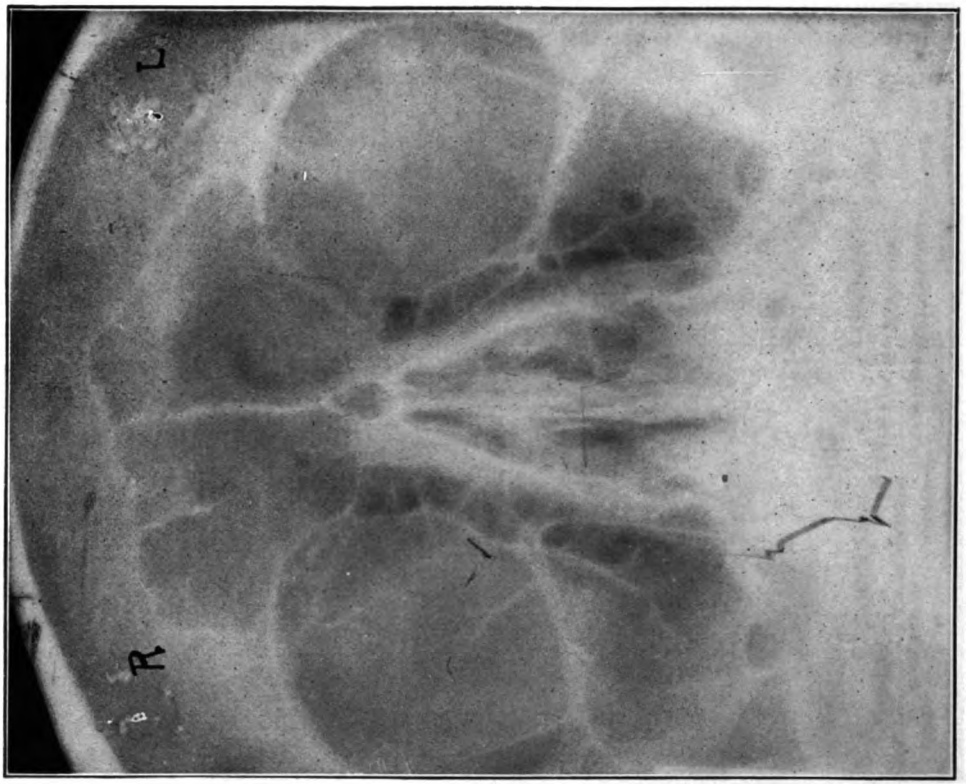

Fig. 374. Radiograph made from pose, Fig. 372. (*Interstate Medical Journal.*)

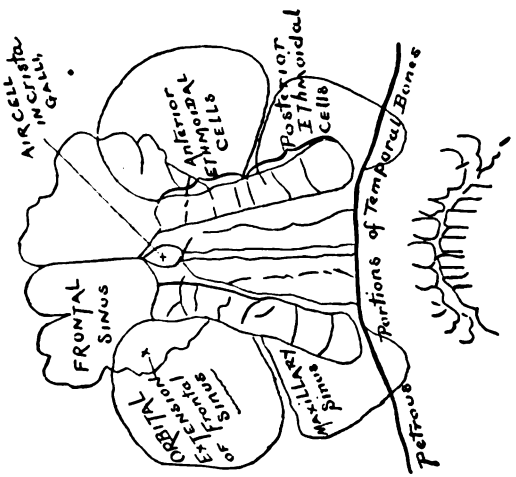

Fig. 375. Diagrammatic drawing explanatory of radiograph, Fig. 374. (*Interstate Medical Journal.*)

Fig. 378. Pose for sphenoids. (*Interstate Medical Journal.*)

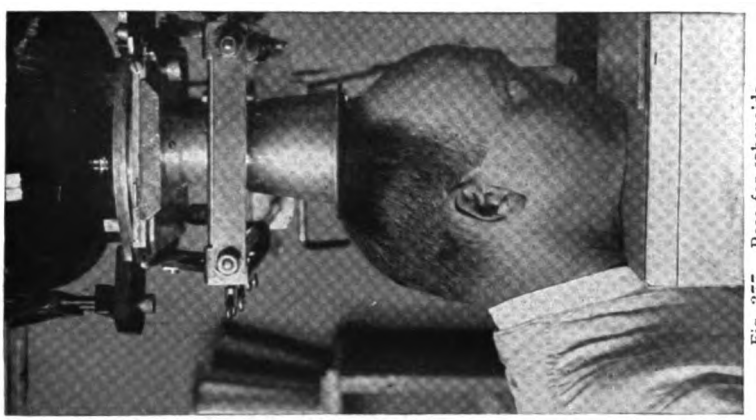

Fig. 377. Pose for sphenoids. (*Interstate Medical Journal.*)



Fig. 376. Pose for sphenoids. (*Interstate Medical Journal.*)

Frontal Sinus Intensifier.

This device (Fig. 380) facilitates the interpretation of radiographs of the head. Correct interpretation is sometimes more difficult on account of the light area around the radiographic image on the negative. The In-

Fig. 379. Pose for mastoids. (*Interstate Medical Journal.*)

tensifier is simplicity itself. It consists of heavy lead plate which fits into a surrounding heavy iron frame; both are covered with felt. Place the intensifier on the plate. The lead plate is now removed and the patient's head is placed in the frame. The exposure is made and the lead plate replaced. The iron frame is then removed carefully, leaving the lead plate covering the part which has been exposed. Two flashes of the X-rays, after the removal of the frame, exposes the photographic plate where the frame has rested and makes the negative black, except just that part of it on which the radiograph appears.

Kassett.

Figure 381 illustrates a "kassett" or plate holder which may be used instead of envelopes to protect plates from light while handling them to make radiographs. Kassetts are especially useful when intensifying screens are used.



Fig. 380. Frontal sinus intensifier.



Fig. 381. Kassett.

The Benoist Penetrometer.

The exact penetration of the X-rays can be determined accurately and easily by the use of the Benoist penetrometer. (Fig. 382.)

Lay the penetrometer on the plate where it will be exposed while the exposure for the radiograph is being made. When the plate is developed the radiograph of the penetrometer will appear as a circle of varying shades surrounding a circle or spot. The shade, counting from the darkest as number one, which matches the center or spot is the penetration of the tube on the Benoist scale.

"Very low vacuum tubes showing a penetration of only about two

will not give good radiographs of any part thicker than the hand, regardless of the length of exposure. Before such a tube is used its vacuum should be coaxed up by running a current of two or three milliamperes through it for a few minutes each day."

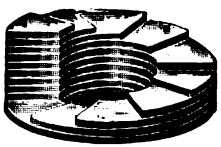

Fig. 382.
Benoist penetrometer.



Fig. 384. Ketcham film holders.

Fig. 383. Small lead protection box for films.

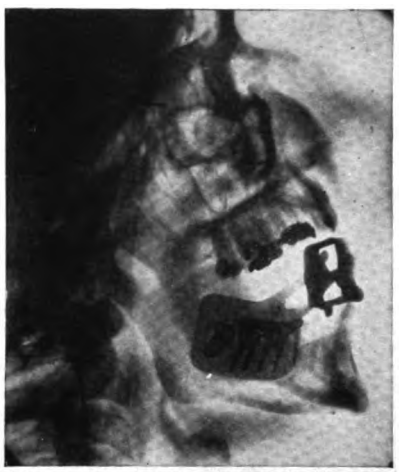

Fig. 384A. Ketchan film-holder in position for lower third molar.

Repeated and prolonged efforts to make radiographs with a tube, the vacuum of which is too low may result in producing an X-ray burn.

When a tube gives 8 or 10 Benoist penetration it will probably not make good radiographs. They will be lacking in contrast because the X-rays are so penetrating that they penetrate bone and soft parts alike. Negatives made with a tube of such high penetration sometimes, besides lacking contrast and detail, will show a brown color from the glass side of the negative. This brown color is indicative of what is called "burning up the emulsion" with a "too-high" penetration.

Small Lead Box. Figure 383 ilustrates a small lead box; inside dimensions about 5 x 6 inches, which is a most practical one for small dental films.

Ketcham Film Holders.

Figure 384 illustrates the Ketcham film holders, the most elaborate set devised. Figure 384A is a radiograph showing a Ketcham film holder in position for a lower third molar.

Fig. 385. Radiograph made on bromide paper.

Fig. 386. Dental radiograph made directly on bromide paper.

Fig. 387. The negative for this radiograph was made at the same time with Fig. 386, the film and the bromide paper being enclosed in the same packet.

Radiographs Made on Paper.

Instead of using a photographic plate or film, a radiograph may be made directly on photographic paper. This paper should be the most sensitive made, so that the exposure will be as short as possible. Glossy "bromide" paper is the best. Figure 385 illustrates a radiograph of the hand made directly on bromide paper. (Reduced one-half.)

Direction of X-rays through the Teeth Figs. 388 and 389.

Figures 388 and 389 show very clearly that directing the X-rays through the posterior teeth at right angles to the long axis of the tongue does not mean at all that the rays pass straight through the tooth from buccal to lingual.

Lines A at right angles to long axis of tongue; lines B straight through the teeth from buccal to lingual.

Fig. 388.

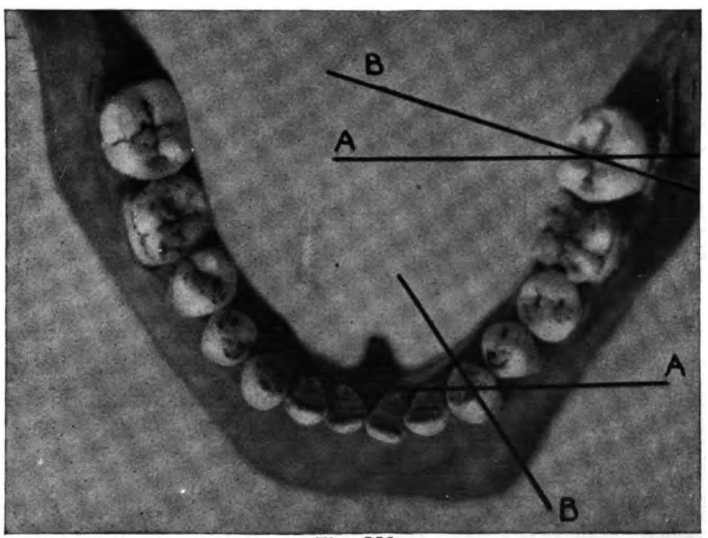

Fig. 389.

Ventilation of Dark Room.

If it is at all possible, it is certainly most desirable to have the dark room well ventilated. The writer uses a "Sirocco" suction fan to force air into the dark room and a ventilator diagramed in Fig. 390 to provide a means of egress. No light is let in by this arrangement. In very hot

weather, open the ice box or refrigerator (if the dark room is equipped with one) and direct the breeze of an electric fan onto the ice. This will lower the temperature of the room quite noticeably.

Small Extra-Oral Radiograph on Film.

Figure 391 illustrates how an extra-oral radiograph may be made on a comparatively small film.

Van Woert Film Holder and Indicator Fig. F.

By means of the Van Woert film holder and indicator, the X-rays may be directed at right angles to the surface of the film. When radiographing the upper teeth, it is not the exactly correct pose to have the X-rays strike the film surface at right angles; it is *almost* correct, however.

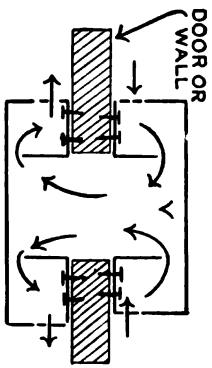

Fig. 390.

Fig. 391. Pose for extra-oral radiograph made on film, and the radiograph.

Beginners will probably find the indicator a help. Men experienced in the practice of radiodontia will not be likely to use it *except* as a means of making a series of exposures of the same part when they particularly desire to make each exposure with the rays passing through the parts and striking the film at the same angle every time. As a means of duplicating a pose exactly, an indicator of some sort is a necessity.

The Soft Tube Technic.

The soft tube technic for dental radiographic work is becoming definitely more popular. The parallel spark gap is set for only about 4 inches and the tube so reduced in vacuum, if necessary, that even this short gap is not "backed up." Splendid black and white negatives are made by this technic. It is important to know that the time of exposure necessary, and so the milliampere-second dose, is greater when the soft tube technic is employed.

Holding Film with Rubber Dam Clamp.

Both Drs. Ottolengui and Barber, each independent of the other, have suggested to the writer that a rubber dam clamp may be used to hold the film packet in position during the exposure.

Vertical Position of Films in Developer and Fixer.

The man who makes only a few film, dental radiographs will find it convenient to use a glass tumbler or cup instead of trays for his developing and fixing solutions and wash water. Fasten the exposed films to a hook clip. (Fig. 119.) Hook the clips over the side of the tumbler or cup suspending the film inside. This makes the handling of the films very easy and affords the advantage of having the films in the developing and

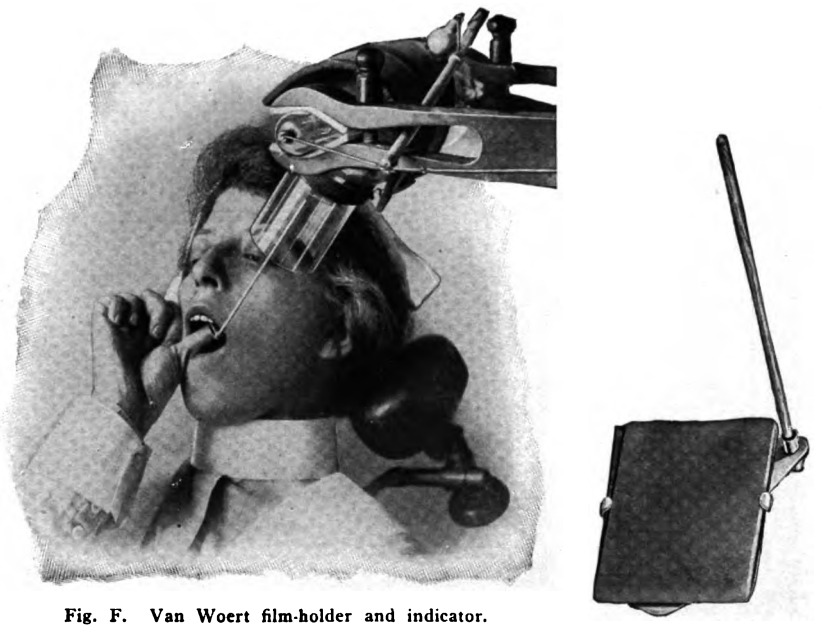

Fig. F. Van Woert film-holder and indicator.

fixing solutions in a vertical position so no sediment can settle on the sensitive surface.

Vessel for Washing Film Negatives

A vessel, something like a berry dish, will be found better than a tray for washing small film negatives, for the water falling from a faucet causes more movement of the water in such a dish and so washes the negatives better and quicker. Negatives can be picked up in such a dish with greater ease than they can from a tray. Such a dish should not be used when the tap water is warm, as the movement of the negatives will scar them.

Salivation.

In cases where there is an excessive flow of saliva, particularly when the outfit used necessitates a rather long exposure, if the films are protected from moisture only by paper, it is expedient to take the film packet from the mouth after exposure and immediately squeeze it between pieces of blotting paper. This may avoid wetting the films inside the packet.

Old Developer and Fixer. With use both the developing solution and the fixing solution will wear out and cease to act on plates or films. Wornout developer produces a weak, poor negative. Wornout fixer will not dissolve out all the unacted-upon silver.

Development When Intensifying Screen is Used. When an intensifying screen has been used "highlights" appear immediately when the plate or film is placed in the developer. The rule to develop 20 times as long as it takes for the highlights to appear does not apply when an intensifying screen has been used.

Leaving Dark Room During Development of Negative. If, while the film or plate is in the developer, it becomes necessary to leave the dark room, the tray containing the developer and the developing plate or film may be covered with a heavy board on the down side of which is tacked or glued thick felt or plush. This will protect the film or plate from exposure to light when the dark room is opened. If a light-proof drawer is available, it is better than the board; the tray may be placed in the drawer when the dark room door may be opened with safety.

"Hypo-Eliminator." Instead of washing the negative in running water for 30 minutes, after fixing, negatives may be soaked in "hypo-eliminators" for about 5 minutes, then rinsed in water, and dried. "Hypo-eliminators" may be purchased at photographic supply houses; directions for their use accompany them. The advantage in using them lies chiefly in the saving of time. They may also be used in the summer to advantage, when tap water is so warm that it softens the emulsion and washing is fraught with the liability of spoiling the negative.

Making Negatives for Identification. When, in the course of a day, a number of radiographs are made of different patients, unless each negative bears some distinguishing mark, one patient's negatives may be mistaken for another's. To avoid this confusion, number the patients as they are received, then number the negatives so: As soon as the films are unwrapped in the dark room, place the patient's number in a corner of the film, marking it on the sensitive side with a lead pencil. The lead pencil mark can be seen on the finished negative.

Lately I have seen an elaborate system of marking each negative, where several are made of the same mouth, to enable the operator, from the markings, to determine what part of the mouth each negative represents. If the sensitive side of the film presents toward the teeth at the time of exposure, as it should always, the operator should be able to determine, from the appearance of the radiograph, what part of the mouth it represents. And if an operator cannot do this, he does not know enough about radiodontia to interpret dental radiographs at all.

Fogged Plates. As the name implies, fogged negatives have a foggy appearance. Fogging may be produced in many different ways. For example (1) By the X-ray light, if the lead of the protection box is not thick enough or if it is placed too close to an active X-ray tube. (2) By a dark room lantern which gives too much light. (3) By getting the plate *too near* the dark room lantern. (4) By exposure to X-rays in some office other than your own; the postman might carry your films or plates into another office before delivering them to you. (5) By using the developing solution too warm. A fogged plate is sometimes referred to as a "light-struck" one. When the action of the fixing solution is well under way, but not complete, the negative appears to be fogged.

Dark Room Summertime Tip. " In extremely hot or damp weather or in hot dark rooms, plates will dry quicker, and stand a very warm wash water if you will put them into a tray containing a solution of 1 oz. of chrome alum to 10 ozs. water for a couple of minutes after removing them from the developer solution.

"The developer temperature, remember, should always be between 65° and 68° Fahr. to give the finest results."

If you do not have a thermometer to determine the temperature of the developer, get one.

An ice box in the dark room in the summer is worth more than it costs.

Faults in Plate Negatives. Along with much other valuable information Geo. W. Brady gives the following in his excellent pamphlet "Paragon X-ray Pointers:"

" Ninety-nine per cent. of plate defects are due to careless manipulation in the dark room.

"*Pitted negatives* are due to too slow drying. The gelatine swells and gelatine eating microbes settle on the plate, leaving transparent spots of blotches.

"*Stains* are generally due to improper fixing. The hypo may be decomposed or the bath may not contain sufficient acid. If the plates are not rinsed thoroughly, sufficient alkali would soon be carried over from the developer to neutralize the acid in the hypo bath. This may cause green or blue stains, even though the plate is fixed in absolute darkness. Stains may be due to insufficient washing. Greenish stains, pink by transmitted light, are usually due to too warm developer, or too long development of under exposed plates. Examination of the plates by a bright light before fixation is complete should be avoided.

"*Pin holes* are always a defect in the handling of the plate. They are never the result of defect in manufacture. They may occur in either tank or tray development. The remedy is to go over the surface of the plate with cotton or to rock the plate vigorously when first put into the developer.

"*Semi-transparent spots* on plates developed in tanks are generally due to air in the water due to high water pressure, or to the cold and

hot water pipes running closely together. The remedy is to stir the water thoroughly and then allow it to stand long enough for the air to escape.

"Irregular transparent spots may be due to oil getting on the film, or to a scum which sometimes occurs on the surface of the developer when left standing for some time.

"Black spots, sometimes with a tail, are due to iron getting into the solution, possibly from the water pipes.

"Small dark spots with sharp edges are generally caused by water spattering on the plates before development.

"Streaky plates may be caused by an old hypo solution in a ribbed fixing box. They may also be due to always rocking the tray in one direction.

"Defective plates are so rare that the trouble can generally be located in the X-ray laboratory. If any question should arise, send the manufacturer of the plates the numbers on the bottom of the box, together with a few of the unexposed plates, or allow some fellow radiographer to expose and develop some of your plates without telling him what your troubles are."

A small film dental negative which is finely checkered with little dark lines is one which has been spoiled by warm solutions or warm wash water.

Danger of Fogging From Dark Room Lantern.

"It is not good policy to have the ruby light shining into the tray throughout the entire course of development; in fact, it is advisable that the red light be only allowed to shine on the plate when the developer is poured on to see that it is properly covered and then the tray kept shaded from direct light till development is nearly completed.

"Remember that very few lights are safe. To test yours, take a small plate, lay a bunch of keys on it directly under the light at a distance of about a foot for a couple of minutes, then develop the plate in darkness with your regular developer for four or five minutes. If your light is an unsafe one, the bunch of keys will show distinctly on the plate."*

Making Prints Glossy.

Photographic prints made on paper from negatives may be made more glossy and altogether more beautiful by placing them on a ferrotype, or squeegee board. The ferrotype is a sheet of metal on one side of which is baked black enamel. After the prints are washed they are laid face down on the enamel side of the ferrotype, and rolled with a rubber covered roller made for this purpose. The ferrotype is now set on end, and as the prints dry they fall off or can be picked off. Before placing the prints on the ferrotype the enamel surface should be polished with ferrotype polish. Ferrotype polish is a solution of paraffin in benzine. It is put on the ferrotype, allowed to dry for a few minutes, then the enamel surface polished with chamois skin. If the prints do not come off the ferrotype as they should, but stick tightly, more paraffin may be added to the polishing solution. Several things may cause prints to stick to the ferro-

* "Paragon X-ray Pointers," by Geo. W. Brady.

type. If left in the wash water too long or if too much pressure is brought to bear on them with the roller they will stick. Washing the ferrotype with soap and water will assist in preventing sticking of the prints. Occasionally a ferrotype will be found on which the prints always stick and it must be discarded and another ferrotype obtained.

Lantern Slides. Lantern slides may easily be made from a good negative. A lantern slide plate is a photographic plate 3¼x4 inches, manufactured especially for the purpose. Like all other photographic plates, it should be "worked" in the ruby, never the orange, light. The negative is placed in the printing frame, sensitive side up, and the slide laid over it, sensitive side down. (We are making what is called a "contact" lantern slide; the lantern slide plate is in contact with the negative.) The average celluloid, dental, radiographic negative is of such density that the time of exposure of the plate to a 16-C. P. electric light, at a distance of two feet, is about 1 second. Allow the slides to remain in the developer a few seconds after the radiograph shows best, until it shows a little too dark. Rinse in water quickly and transfer to the fixing bath, where it should remain until the picture shows clearly as desired. The writer uses Imperial lantern slide plates and Seed's prepared metol-hydrochinone developer. After fixing, the slide is washed and dried the same as any photographic plate. When dry a piece of transparent glass, the same size as the slide, is laid on the film side of the slide and the two stuck together at their edges with binding tape, such as is used for passe-partout work. The piece of clear glass is used to protect the emulsion of the slide against scratching.

When a lantern slide of a negative larger than the lantern slide plate is desired, a contact lantern slide cannot be made. An apparatus similar to the one illustrated in the Appendix to Chapter X for enlargement, must be used. Light is directed through the negative, then through a reducing lens onto the lantern slide. When the lantern slide desired is from an extra-oral dental radiograph, even though the plate used is as large as 8x10, the size of the lantern slide will usually cover the part of the negative of interest and so the lantern slide plate may be placed over the area of interest and a contact lantern slide made of that part of the negative.

Dr. Kells makes lantern slides of, instead of from, his celluloid dental negatives. This is accomplished as follows:

On a clear glass 3¼x4 inches place a piece of black paper the same size, with a hole in the center large enough to show all of the negative that the operator wishes to exhibit. Place the negative directly over this hole in the paper. Place another piece of glass 3¼x4 inches over the whole and bind the two pieces of glass together at their edges with binding strips. The advantage of this method over making photographic slides is: The ease and dispatch with which they may be made—a dark room and equipment is not necessary—and, since we are using the negative itself, there is no loss of detail such as might occur when the other method is employed and a new picture is made on the photographic slide. The disadvantage is that the negatives with good detail are often so dark that the light from the lantern is not strong enough to penetrate them.

Negatives made with the transformer (interrupterless) X-ray machines are best for lantern slides because they are usually not so dense as those made with the other types of X-ray machines.

Milliampere-Second Table for Exposure.

Within a limit, the time of exposure necessary varies inversely according to the milliamperes sent through the tube. Thus the more milliamperage sent through a tube the shorter the time of exposure necessary, or conversely the longer the exposure given the less milliamperage need be sent through the tube. The action on the photographic emulsion on the plate or film would be *about* the same from a 2-second exposure with 30 milliamperes passing through the tube as from a 3-second exposure with 20 milliamperes passing through the tube. So we have come to measure exposures in milliampere-seconds. (M. A. S.)

Obtain the milliampere seconds by multiplying the number of milliamperes passing through the tube by the number of seconds the current is turned on.

If the distance between target and film or plate varies apply the rule that the time of exposure necessary varies directly with the square of the distance. (See Page 124).

The following is a dental M. A. S. table for exposure:

KIND OF RADIOGRAPH	CONDITION OF TUBE	DISTANCE FROM TARGET TO FILM OR PLATE	FILM OR PLATE	TIME OF EXPOSURE WITH ORDINARY GAS X-RAY TUBE	TIME OF EXPOSURE WITH COOLIDGE TUBE
Dental Intra-Oral	Back up about 5 inches parallel spark	15 inches	Eastman slow	About 60 Milliampere seconds	8/10 of that necessary with gas tube
Dental Intra-Oral	Back up about 5 inches parallel spark Penetrometer Benoist about 5	15 inches	Eastman fast	About 15 milliampere seconds, (about ¼ the exposure necessary for slow films)	8/10 of that necessary with gas tube
Dental Extra-Oral	Back up about 5 inches parallel spark Penetrometer Benoist about 5	18 inches	Paragon	About 90 Milliampere seconds	8/10 of that necessary with gas tube
Frontal Sinuses, Ethmoids, Antra, also Sphenoids and Mastoids	Back up about 5½ parallel spark Penetrometer Benoist about 6	20 inches	Paragon	About 200 Milliampere seconds. (This milliampere-second exposure can be reduced to ½ or less by the use of an intensifying screen)	8/10 of that necessary with gas tube

It is of passing interest to compare the dental milliampere-second table with a milliampere-second table for other parts of the body.* (After Geo. W. Brady.)

KIND OF RADIOGRAPH	CONDITION OF TUBE	DISTANCE FROM TARGET TO PLATE	MAKE OF PLATE	TIME OF EXPOSURE WITH ORDINARY GAS X-RAY TUBE	TIME OF EXPOSURE WITH COOLIDGE TUBE
Hand	Back up about 5½ inches of parallel spark	18 inches	Paragon	18 M. A. S.	$\frac{1}{10}$ the exposure necessary with gas tubes
Wrist, lateral	Ditto	Ditto	Ditto	27 M. A. S.	Ditto
Elbow	Ditto	Ditto	Ditto	35 M. A. S.	Ditto
Ankle, lateral	Ditto	Ditto	Ditto	44 M. A. S.	Ditto
Ankle, antero-posterior	Ditto	Ditto	Ditto	62 M. A. S.	Ditto
Knee, lateral	Ditto	Ditto	Ditto	62 M. A. S.	Ditto
Knee, antero-posterior	Ditto	Ditto	Ditto	70 M. A. S.	Ditto
Shoulder	Ditto	Ditto	Ditto	105 M. A. S.	Ditto
Kidney	Ditto	Ditto	Ditto	175 M. A. S.	Ditto

*Size of patient: 160 lbs.

The Explanation of the Short Exposure with the Small X-Ray Machines. The beginner in radiodontic work is very much surprised and confused when he learns that Dr. A., who has a large, powerful and elaborate X-ray outfit "exposes his dental films 5 seconds," while Dr. B., who has a very small outfit "exposes his dental films only 1 second." The explanation is that Dr. A. is using a tube which backs up only about 3 inches of parallel spark, while Dr. B.'s tube backs up 5 inches, or more. Dr. A.'s target-film distance is 16 or 20 inches, while Dr. B.'s target-film distance is about 5 inches. Dr. A. could, by using a tube of higher vacuum and lessening his target-film distance, reduce his time of exposure, but his negatives would not be as good; they would not be beautifully and brilliantly black and white, but would become darker, less contrasty, less distinct, less perfect.

The practice of reducing the time of exposure for dental negatives may easily be carried to the point where the quality of the negative is sacrificed.

It is impossible to make a dental radiograph with a short exposure with some X-ray machines of the transformer type, because they do not produce sufficient voltage to excite a high vacuum tube. Thus some owners and operators of such transformer machines are greatly disturbed because their neighbor, who has an induction or Tesla coil, does not find it necessary to expose so long. Such operators should be consoled by observing that they produce negatives of a finer quality; their type of machine is protecting them against the mistake of sacrificing quality for speed exposures.

APPENDIX TO CHAPTER VI.

Reading Radiographs.

Dr. Johnson's Editorial.

The following is abstracted from an editorial by Dr. C. N. Johnson, which was published in the May, 1914, edition of the Dental Review:

The Fallibility of the X-Ray.

"It is probably true that no other discovery in recent years has been of greater value to the medical and dental profession than has that of the X-ray. It has aided us in clearing up many obscure lesions and has thus been of immense value in diagnosis. In dentistry it has been of especial service in discovering impacted or delayed teeth in the jaws, and has shed light on many a puzzling case of neuralgia by showing the cause of the irritation. Although it is only a comparatively few years since its introduction it would leave us bereft of much of our usefulness if it were eliminated from our practice.

"And yet with all this it has its limitations and it is high time they were pointed out. It has been used extensively for diagnosing abscesses and bone lesions in the jaws and for showing the condition of root fillings in teeth. It is useful for these purposes up to a certain point, but it is by no means infallible and in some cases it is decidedly misleading. It may be that we have not yet advanced sufficiently in its use to correctly interpret its findings, but the fact is that when it comes to diagnosing bone absorptions and alveolar abscesses the most expert X-ray men we have are often very wide of the mark. Nor do we believe this can be relied on to tell accurately whether root canals are properly filled or not. Many a pulpless tooth has been arraigned as the culprit when the fault lay elsewhere and many an operator has been censured for poor root filling when his operation was not at fault. And the great danger is that medical men will be extensively misled about dental operations as interpreted by the X-ray. Already some of them are reading all sorts of disaster as the result of root filling. If a patient has a pain somewhere about the jaws they are making X-rays—which in itself is perfectly proper, and which in many instances will throw light on the trouble—but they are reading into these X-rays much evidence which is not compatible with fact. It does not follow that because a radiograph shows a dark area around the end of a root that the bone is all absorbed at that

point or that there is an abscess cavity there. It does not prove that a root canal is not well filled because the radiograph fails to show a filling to the apex. We must be more discriminating in reading radiographs than we have been in the past if we are to avoid doing harm to the patient.

"A single instance, illustrative of many others which might be mentioned, will serve to prove the present contention. A patient had pain in the region of the left upper cuspid. This tooth was banded as the middle pier to a bridge. A radiograph was made of the region, and the verdict of the radiographer was that there was an extensive abscess cavity around the cuspid with the bone all absorbed. His remark was: 'If you cut the band the cuspid will drop out. Nothing holds it in place but the gold band.'

"The band was cut and the cuspid was found perfectly firm—the thing that nearly dropped out was the bridge, the cuspid having been its chief support. Thinking from the evidence of the radiograph that there must at least be an abscess on the cuspid it was drilled into—only to find a live pulp. Here, with the best intentions, a wrong was done the patient, on the evidence of the X-ray, and it is probably not an isolated case.

"This article is not intended as a reflection on the great utility of the X-ray, which is cheerfully acknowledged, but merely to counsel caution on the part of those who invariably 'see things' in every radiograph that is taken."

Abstract from the Writer's Reply to Dr. Johnson's Editorial.

The writer's answer to Dr. Johnson's editorial which was published in the June, 1914, issue of the Dental Review is now given:

INDIANAPOLIS, IND., April 9th, 1914.

MY DEAR DR. JOHNSON:

Your editorial, "The Fallibility of the X-Rays," creates in me a degree of cerebral unrest which, reduced to ink and paper, is as follows:

First, let me say I agree with practically everything you say, and I am gratified to have you take such comprehensive editorial notice of the matter. I agree with practically everything you say, and yet, if I were writing on the subject, my title would be "The Infallibility of the X-Rays" instead of "The Fallibility of the X-Rays."

That the radiograph has its "limitations" and that it is sometimes "decidedly misleading" I grant you, but it is absolutely infallible; i. e., incapable of error. It is always the product of definite physical and chemical laws.

You say "it may be that we have not yet advanced sufficiently in its use to correctly interpret its findings." There you hit it. The apparent fallibility of the radiograph lies in our interpretation of it, in our lack of attainable knowledge which would explain "decidedly misleading" appearances; and, in our unwillingness to admit that it does have "limitations."

You cite an illustrative case. Allow me to cite one also; a case which I handled a number of years ago when very little dental radiographic work was being done and it was an "event" to make an "X-ray picture of the teeth." A patient suffering from neuralgia was sent to me for radiographic examination. I found a shadow in the region of the pulp chamber of a lower molar and made a diagnosis of pulp stone. The next day the man who referred the case indignantly informed me by 'phone that, on the strength of my diagnosis, he had opened the molar tooth and there was no pulp stone in it.

With no further explanation you would count this case as one demonstrating the fallibility of the radiograph. But then, as I have said, the radiograph is infallible; it is always the product of definite physical and chemical laws. Why then, was there a shadow in the region of the pulp chamber of the lower molar? Something made that shadow. What was it? Perhaps an air bubble attached itself to the film at the time of its development. That would cause a spot. But the shadow I saw did not have the characteristic appearance of an air bubble spot, and, in further disproof of the air-bubble explanation, the spot occurred on two different negatives in exactly the same place. I asked to see the patient again and, upon examination, found a filling on the buccal surface, at the gingival line. I had mistaken the shadow cast by the cement filling for a pulp stone.

It was my mistake. The radiograph had done what it may be depended upon to do; it had unerringly recorded densities.

You may ask if a man is not always liable to make the same mistake I made. No. Once his attention is directed to the possibility of such an error he should never make it.

And so one may trace the mistakes in his radiographic diagnosis, from the radiograph, to the man who read the radiograph, in all cases where mistakes have been made. You mention the most productive cause of mistakes when you close your editorial by saying, "This article is not intended as a reflection on the great utility of the X-ray, which is cheerfully acknowledged, but merely to counsel caution on the part of those who invariably 'see things' in every radiograph that is taken."

As a man who has worked to develop the field of dental radiography, I feel grateful to you for the remark, for the greatest menace to a more general use of the radiograph is the radiographer who never says, "this radiograph shows us nothing." The radiograph is the most efficient diagnostic aid at our command, but it does not always enable us to make a diagnosis. Radiographers must admit this and quit reading a definite diagnosis in every radiograph, whether it is there or not, else men like you, Dr. Johnson, will blame the radiograph for the fallibility of the radiographer. H. R. R.

In further general consideration of this subject I quote from my report to the Sixth International Dental Congress, London, 1914:

"I cannot consider the subject of the advantages of radiography as an aid to diagnosis without calling attention to the fact that the good derived from its use depends very much on the *manner* in which it is used. It is unfortunate that it is not always used in vain by the man who has no idea of the etiology of the patient's malady, and makes, or has made, radiographs, expecting them to reveal, as on a written page, the disease, its exciting cause and a paragraph or two describing treatment. I say it is unforunate that the radiograph does not always disappoint this man who expects too much of it, who forgets all other methods of diagnosis and lazily depends on the radiograph to do all his diagnostic work for him. It is unfortunate because it leads men to believe that the radiograph has arrived to replace all other means and modes of diagnosis, when in reality it has come not to take the place of, but to take its place with, the probe, the history, the symptoms, the signs, and diagnostic tests.

"A tentative diagnosis should always be made before the case is radiographed. Thus, for example, from the signs and symptoms, you suspect an impacted tooth. Radiographs are made to verify or disprove this diagnosis. If the diagnosis is verified by the radiograph a great element of doubt as to the correctness of this diagnosis is removed from the diagnostician's mind. If the tentative diagnosis is disproved by the radiograph, an important step has been made in diagnosis by elimination.

"Another example: from signs, symptoms, probing and tests we make a diagnosis of alveolar abscess of an upper cuspid tooth.

"A radiograph is made, and we learn that we have not only an abscess of the cuspid but of the first bicuspid also. The radiograph has verified our diagnosis and elaborated on it.

"To epitomize: if you would derive the greatest benefits from the radiograph, use it only to verify, or disprove, and elaborate on tentative diagnoses."

A List of Mistakes.

No set of rules can be given which will prevent mistakes in judgment rendered from radiographic readings. However, as I have said elsewhere, the radiograph is no mere fad—it is here to stay—and so it is well that we should learn as soon as possible the mistakes one engaged in radiodontic work is liable to make. Accordingly the following list is given.

It is incomplete, as perforce any list of mistakes in radiographic interpretation must be, for someone is making some new mistake every day.

The List:

(1) To mistake the mental foramen for an abscess cavity at the apex of a lower bicuspid. (2) To mistake the anterior palatine foramen for an abscess cavity. (3) To mistake the nasal cavity for necrosis of the palate. (4) To mistake the maxillary sinus for an abscess cavity at the apices of the upper bicuspids and molars. (5) To mistake the inferior dental canal for a fistulous tract. (6) To mistake the mandibular foramen for osteoporosity, due to disease. (7) To fail to bear in mind that there is such a thing as a normal periapical space. (8) To mistake a dark spot, due to somewhat unusual porosity, for an alveolar abscess. (9) To mistake a shadow caused by the spinal column for necrosis of the mandible. (10) To mistake the lingual tubercle for a bone whorl or the shadows on either side of the lingual tubercle for osteoporosity due to infection. (11) To mistake the hyoid bone for " some " pathologic lesion. (12) To mistake the larynx for an abscess cavity in the neck. (13) To make a diagnosis of antral empyema because one antrum happens to be smaller than the other. (14) To mistake the coronoid process for the root of a third molar. (15) Without taking into account the angle at which the X-rays were directed toward the tooth and film, to assume that a canal filling does not reach the apex of a root when it does. (16) Without taking into account the angle at which the X-rays were directed toward the tooth and film, to assume that the buccal roots of upper bicuspids and molars are much shorter than the lingual roots of the same teeth. (17) To assume that a perforation through the side of a root does not exist because it cannot be seen to the mesial or distal. (18) To assume that a broach is following a canal because it cannot be seen extending too far to the mesial or distal. (19) To mistake a canal filling passing into a crooked root for a canal filling material passing through a perforation through the side of the root. (20) To state definitely from the appearance of flat radiographs (not stereoscopic radiographs) that impacted teeth lie to the lingual or facial of the other teeth. (21) To mistake a small cervical filling for a pulp stone. (22) To assume that a

filling in the crown of a tooth enters the pulp chamber when it does not. (23) To assume, from the appearance of flat radiographs (not stereoscopic radiographs) that the root of an upper posterior tooth penetrates the antrum. (24) To fail to take into account that an abscess cavity may lap to the lingual or facial of the adjoining teeth giving the radiographic appearance of their involvement but without involving them. (25) To fail to consider the element of depth when judging the size of an abscess cavity. (26) To mistake normal resorption of bone, due to age, for pyorrhea alveolaris. (27) To fail to take into account the effect the tipping of a tooth to the lingual or facial will have on the appearance of the tooth in the radiograph. (28) To state *definitely* that a rarefied area at the apex of a root represents infection without considering the anatomy of the parts and the symptoms and history of the case. (29) To state that no infection exists because no abscess cavity can be observed. (30) To fail to bear in mind that osteodensity as well as osteoporosity may be caused by infection. (31) To assume, when observing an abscess cavity at the apex of a tooth with a well-filled canal, that the abscess occurred after canal filling. (32) To expect to see a fistulous tract. (33) To give a positive diagnosis of pulp stones from the appearance of one radiograph. (34) To try to make one radiograph do the work of two or several. (35) To mistake hypercementosis for a poorly made radiograph. (36) Not to know the difference between a good radiograph and a poor one. (37) To make just one radiograph of a part and stop, calling it a radiographic examination. (38) To depend on intra-oral radiographs alone, especially in cases of neuralgia, facial fistula, impacted third molars, and abscess of the lower bicuspids. (39) To fail to use a reading-glass when studying negatives and so avail one's self of the great assistance rendered by the practice. (40) To fail to use the electric test for vitality of pulps in connection with radiographic examinations. (41) To make radiographs of every tooth in the mouth in all cases where the teeth are being examined to locate foci of infection.

We will now proceed with a short consideration of each of the foregoing mistakes:

1. To Mistake the Mental Foramen for an Abscess Cavity at Apex of a Lower Bicuspid.

Figure 392 shows the mental foramen. The location of this foramen varies greatly in different individuals. It may occur in such a position in a radiograph as to have the appearance of an abscess cavity at the apex of the second or first, lower bicuspid (Fig. 393). When the radiograph is made on a small film held in the mouth and the rays have been directed from below upward this is especially likely to occur.

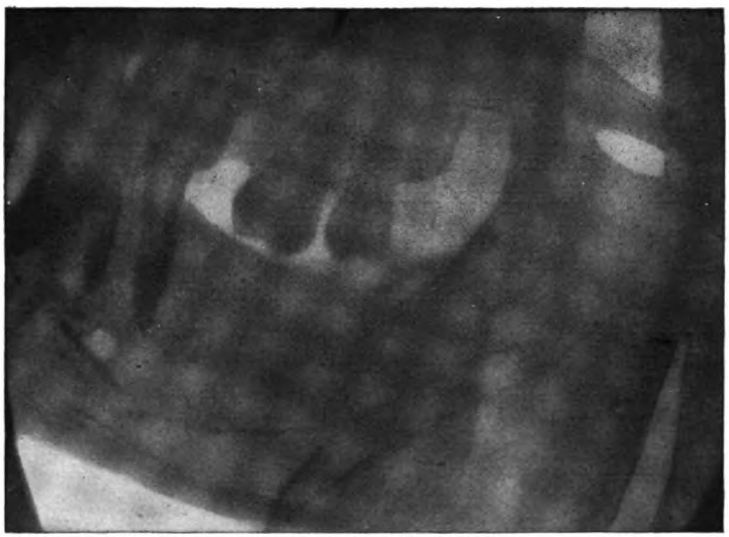

Fig. 392. The mental foramen below and between the apices of the roots of the lower bicuspids. (Radiograph by Cole and Beeler, Indianapolis.)

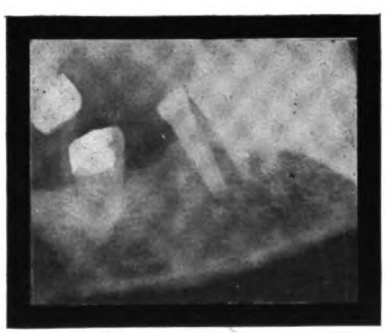

Fig. 393. The mental foramen at the apex of the lower second bicuspid, having the appearance of abscess cavity.

Plates are better than films to differentiate between the mental foramen and an abscess cavity because the radiographic shadows on them are less likely to be distorted and because they take in a greater field for observation. In a plate one can see *both* the mental foramen and the abscess cavity if one exists. If a spot having the appearance of an abscess cavity is observed at the apex of a lower bicuspid and the mental foramen

Fig. 394. The anterior palatine foramen having the appearance of an abscess cavity at the apex of an upper central incisor.

Fig. 395. Nasal cavity spots which have been mistaken for abscesses of the upper anterior teeth and necrosis of the palate.

Fig. 396. Showing the antrum which is sometimes mistaken for an abscess of the upper posterior teeth. The shadow of the antrum may occur even as far forward as the apical region of the cuspid. Fig. 459A.)

cannot be observed elsewhere, in a large extra-oral radiograph, it is probable that the spot at the apex of the tooth is the mental foramen. The tooth should be tested with the electric test, for pulp vitality, if possible. If this test cannot be made, an exploratory, diagnostic opening may be made into the tooth of sufficient depth to ascertain whether or not the pulp is vital.

2. To Mistake the Anterior Palatine Foramen for an Abscess Cavity.

Figure 394 shows the anterior palatine foramen. Depending on the

angle of the rays and the position of the film, this foramen, which is in the region of the apices, and between the roots, of the upper central incisors, may have the radiographic appearance of an abscess cavity at the apex of one of the central incisors.

3. To Mistake the Nasal Cavity for Necrosis of the Palate.

Figure 395 shows nasal cavity spots which have been mistaken for abscesses of the upper anterior teeth and necrosis of the palate.

4. To Mistake the Maxillary Sinus for an Abscess Cavity at the Apices of the Upper Bicuspids and Molars.

Figure 396 illustrates the appearance of the antrum which is sometimes mistaken for a large abscess cavity. It is sometimes difficult, to the point of being impossible, to differentiate between the antrum and an abscess cavity by the study of *radiographs alone;* use the electric test for pulp vitality. See diagram Fig. 397. (See Fig. 459A.)

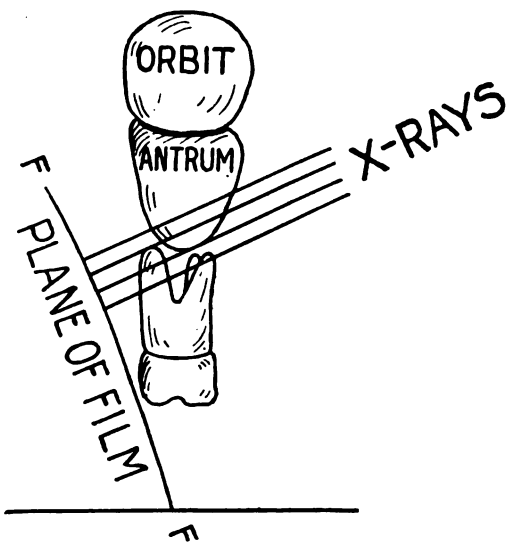

Fig. 397. Diagram showing why the shadow of the antrum occurs at the apices of the roots of the upper posterior teeth.

5. To Mistake the Inferior Dental Canal for a Fistulous Tract.

Figure 398 shows the inferior dental canal leading forward from the unerupted third molar. This canal was mistaken for a fistulous tract.

6. To Mistake the Mandibular Foramen for Osteoporosity, Due to Disease.

At the mandibular foramen the ramus is thin and so this area may appear dark in the radiographic negative.

7. To Fail to Bear in Mind That There is Such a Thing as a Normal Periapical Space.

It should constantly be borne in mind that there is such a thing as a normal periapical space and that this space may be much larger in some cases than in others. A large periapical space has about the same appearance as a small abscess cavity. To differentiate between a small abscess cavity and a large periapical space learn whether or not the pulp of the

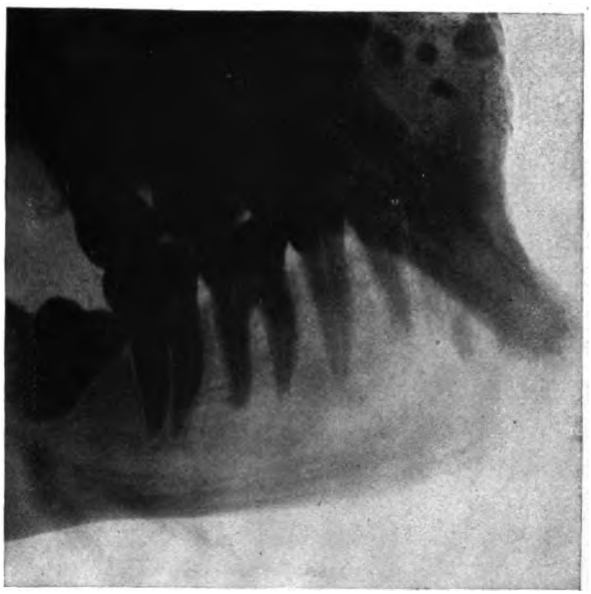

Fig. 398. The inferior dental canal leading forward from the apical region of the lower third molar. It was mistaken for a fistulous tract.

tooth is vital by the electric test or by making an exploratory opening. In this connection I may say that infection may cause hypercementosis and abnormal osteodensity, i.e., osteosclerosis, in the region of the infection, which knowledge will assist in differentiating between small abscess cavities and normal, large periapical spaces. Figure 399 illustrates an unusually large periapical space at the roots of a lower molar while Fig. 400 illustrates a small abscess cavity no larger than a large periapical space at the apices of the lower third molar. The filling material seen to enter the pulp chamber admits of a differential diagnosis in this latter case. (See Fig. 444, which is the same as Fig. 400 but shows the filling in the pulp chamber much better.)

8. To Mistake a Dark Spot, Due to Somewhat Unusual Porosity, for an Alveolar Abscess.

Figure 401 shows what seems to be an abscess at the apex of the

distal root of a lower molar. Figure 402, however, of this same tooth, made at a different angle, shows this spot to be simply a cancelous spot in the bone.

Some men have a tendency to call any dark area in a radiographic negative an abscess. Figures 401 and 402 show how careful one must be not to mistake a normal dark spot for a pathologic one. The bone is nor-

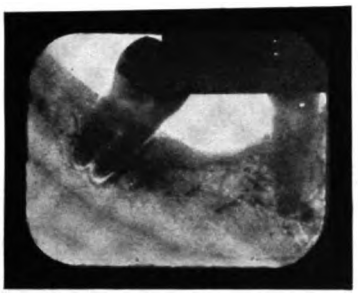

Fig. 399. Unusually large periapical space at the apex of the roots of the lower molar; appearance similar to that of a very small abscess.

Fig. 400. Very small abscess at apices of roots of lower third molar; appearance similar to that of large periapical space.

Fig. 401. Spot at the apex of the distal root of the anterior lower molar; has the appearance of an abscess.

Fig. 402. Same as Fig. 401, taken at a different angle. The spot shows now as a cancelous area to the distal of the apex of the distal root of the anterior molar.

mally much more cancelous in some individuals than in others, and the same bone may be more cancelous in some regions than in others.

Figure 403 shows suspicious (?) areas in the apical region of the central and lateral incisors. These areas are the nostrils, which may be mistaken for bone rarefication, due to infection. It is unlikely that the half-tone will show it well, but the original negative of Fig. 403 shows the outline of the end of the nose distinctly.

9. To Mistake a Shadow Caused by the Spinal Column for Necrosis of the Mandible.

Figure 404 shows overlapping of the ramus and the spinal column in such a manner as to give the ramus the appearance of being diseased to one not proficient in the reading of radiographs. I recall also a case in which the shadow of a vertebra was mistaken for an unerupted tooth in the ramus.

10. To Mistake the Lingual Tubercle for a Bone Whorl or the Shadows on Either Side of the Lingual Tubercle for Osteoporosity, Due to Infection.

Fig. 403. Radiograph showing the tip of the nose and the two nostrils, which latter have somewhat the appearance of abscesses of the lateral incisors. (Retouched.)

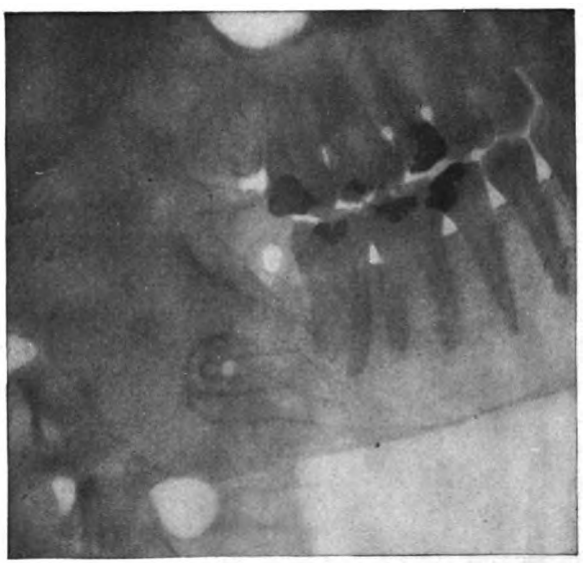

Fig. 404. Superimposition of the spinal column and the mandible, giving the latter an abnormal appearance.

Figure 405 shows the lingual tubercle, as it sometimes appears in radiographs, simulating the appearance of a bone whorl.

11. To Mistake the Hyoid Bone for "Some" Pathologic Lesion.

The hyoid bone, especially when it and the mandible overlap, is sometimes thought to represent some abnormal condition of the mandible or the neck. The hyoid bone can be seen below the mandible in Figs. 255 and 287.

12. To Mistake the Larynx for an Abscess Cavity in the Neck.

The larynx will appear as a dark area in the radiographic negative and should not be mistaken for a pathologic lesion.

13. To Make a Diagnosis of Antral Empyema Because One Antrum Happens to Be Smaller Than the Other.

It should be borne in mind that one antrum may be much smaller than the other and, if the radiographer does this, he will not mistake a small antrum for a diseased one just because it happens to be smaller than its mate on the opposite side.

14. To Mistake the Coronoid Process for the Root of a Third Molar.

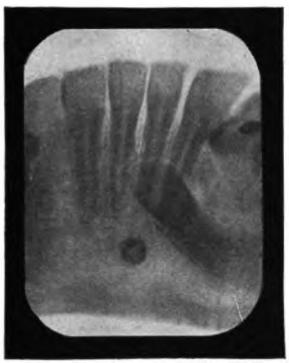

Fig. 405. Radiograph of the lingual tubercle.

Fig. 406. Case in which the coronoid process was mistaken for a root of an upper third molar.

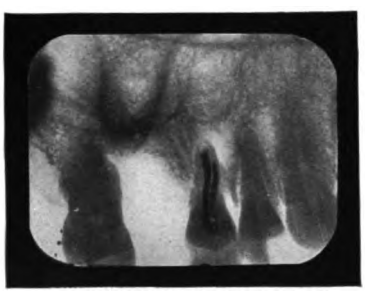

Fig. 407. In this bicuspid, one canal filling seems to reach farther than the other.

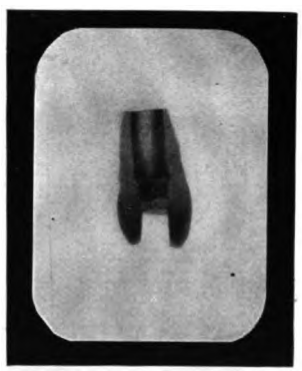

Fig. 408. Same bicuspid, same canal fillings illustrated in Fig. 407.

Figure 406 is a radiograph of a case in which the coronoid process was mistaken for a root of an upper third molar.

15. Without Taking Into Account the Angle at Which the X-rays Were Directed Toward the Tooth and Film, to Assume That a Canal Filling Does Not Reach the Apex of a Root When it Does.

Figure 407 is an experimental case. In Fig. 407 one canal filling

reaches the end of the excised bicuspid root while the other seems to fall short of the end. Figure 408 is of the same bicuspid, removed from the alveolus, and shows that both canal fillings reach the end of the resected root.

Figure 409 diagrammatically illustrates why one canal filling has the appearance of not reaching as far as the other in Fig. 407.

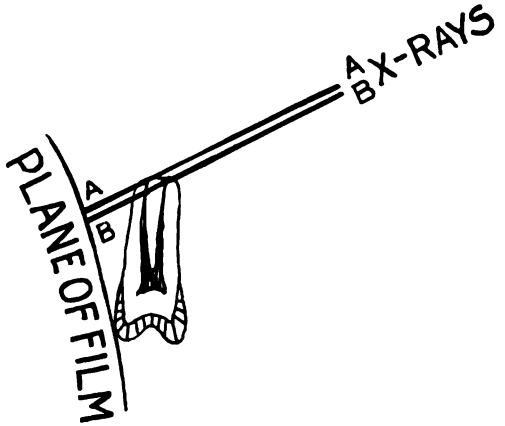

Fig. 409. Diagram explanatory of Figs. 407 and 408. A, where the shadow of the end of the canal filling in the lingual canal is cast on film. B, where shadow of the end of the canal filling in the buccal canal is cast on film.

Fig. 410. One canal filling seems too short and to pass to the distal too far.



Fig. 411. Same as Fig 410 after removal of bicuspid from alveolus.

Figure 410 shows one canal filling apparently reaching the end of the root while the other falls a little short. However, observe Fig. 411, which is of the same tooth removed from the mouth.

Figure 412 diagrammatically illustrates how the buccal canal is thrown to the mesial or distal of the lingual canal in Figs. 407 and 410. By directing the rays mesio-lingually (X-rays No. 1 of Fig. 412), the buccal canal is thrown to the mesial: Fig. 407. By directing the rays

disto-lingually (X-rays No. 2 of Fig. 412), the buccal canal is thrown to the distal: Fig.

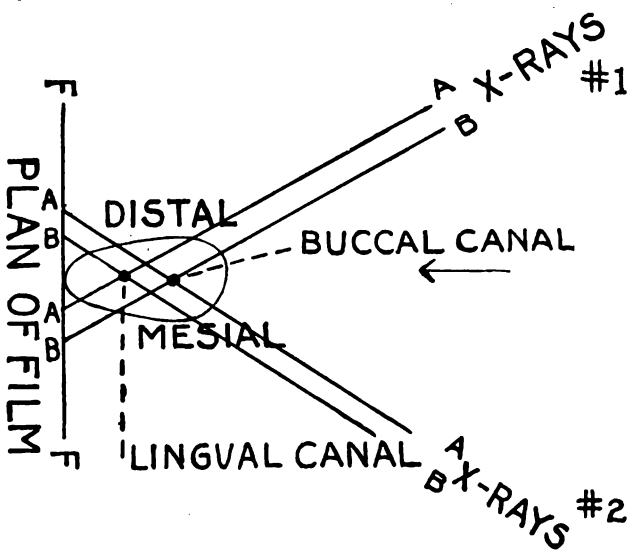

Fig. 412. Cross section of an upper bicuspid tooth showing how the buccal canal may be thrown to the mesial (X-rays No. 1), or the distal (X-rays No. 2), of the lingual canal. With the rays passing through the tooth as indicated by "X-rays No. 3," the shadows of the buccal and lingual canals lie one on the other and appear as one in the radiograph.

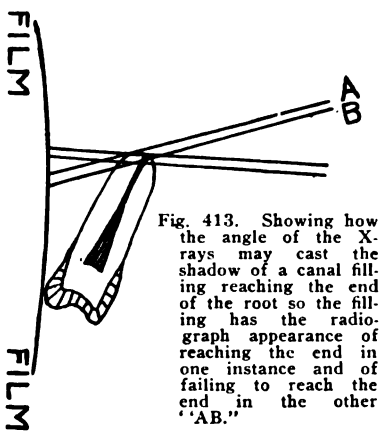

Fig. 413. Showing how the angle of the X-rays may cast the shadow of a canal filling reaching the end of the root so the filling has the radiograph appearance of reaching the end in one instance and of failing to reach the end in the other "AB."

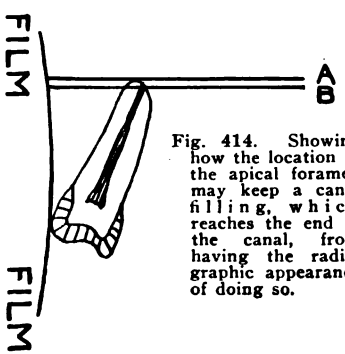

Fig. 414. Showing how the location of the apical foramen may keep a canal filling, which reaches the end of the canal, from having the radiographic appearance of doing so.

Figs. 413 and 414.

Figure 413 diagramatically illustrates how, by changing the angle at which the X-rays are directed through the parts onto the film, a canal filling which reaches the end of the root may appear to reach the end or to fall short of reaching the end. With the X-rays directed as lines A and B indicate, the canal filling, as it appears on the radiograph, will not reach the end of the root; with the rays directed as indicated by the unmarked lines, the

resulting radiograph will show the canal filling reaching to the end of the root.

The lines marked A and B then may be considered to represent an incorrect angle for the X-rays, while the unmarked lines represent the correct angle. However, when the apical foramen happens not to be in the bucco-lingual center of the root, but stands somewhat to the buccal, what would ordinarily be the correct angle for the rays will cast the shadow of the canal filling short of the extreme apical end. Fig. 414.

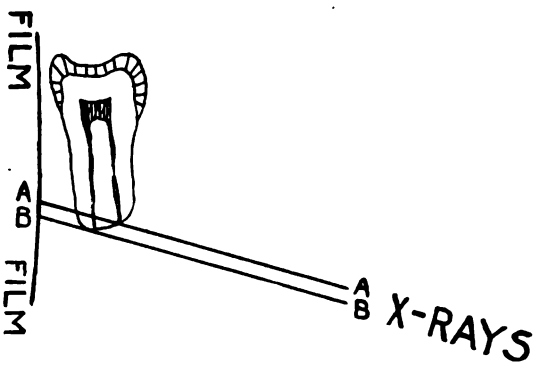

Fig. 415. Showing how the canal filling in the mesio-buccal root of a lower molar may seem not to reach the end of the root when it does.

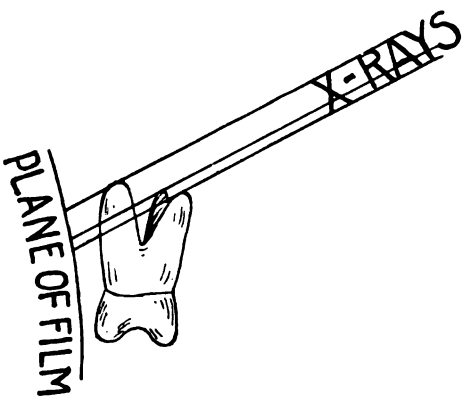

Fig. 416. Showing how the angle of the X-rays may make the buccal roots of upper molars seem much shorter than the lingual.

The thickness of the tooth, bucco-lingually, governs to a great degree the possibility of distortion in such a manner as to cause a canal filling which reaches the end of the root to have the appearance of failing to do so. Thus the mesio-buccal canal of lower molars as well as the buccal canal in upper bicuspids is especially liable to this distortion (Fig. 415),

while the more cone-shaped roots (roots narrow from facial to lingual at their apices) are almost free from the liability of such distortion.

16. WITHOUT TAKING INTO ACCOUNT THE ANGLE AT WHICH THE X-RAYS WERE DIRECTED TOWARD THE TOOTH AND FILM, TO ASSUME THAT THE BUCCAL ROOTS OF UPPER BICUSPIDS AND MOLARS ARE MUCH SHORTER THAN THE LINGUAL ROOTS OF THE SAME TEETH.

Figure 416 diagrammatically illustrates why the buccal roots sometimes appear so much shorter than the lingual roots. As the X-rays are directed from a higher point in a more downward direction this distortion is increased.

17. TO ASSUME THAT A PERFORATION THROUGH THE SIDE OF A ROOT DOES NOT EXIST BECAUSE IT CANNOT BE SEEN TO THE MESIAL OR DISTAL.

It is a mistake to state that a perforation does not exist because it cannot be seen to the mesial or distal. I have seen cases of perforation, to the facial and lingual, with posts passing through them which could not be observed radiographically. In such cases as these efforts may be made to show the perforation by directing the rays through the tooth at different angles, i.e., *mesio*-lingually and *disto*-lingually. (Fig. 419B.)

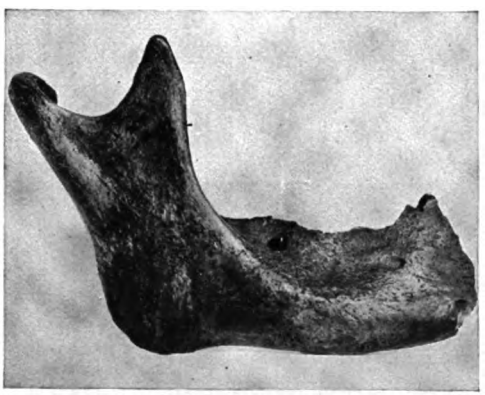

Fig. 417. Showing hole in bone caused by abscess of lower second molar.

If the perforation itself cannot be observed, bone destruction caused by it can sometimes be seen.

In this connection I direct your attention to Fig. 417. Though the teeth are missing, observe the hole in the bone caused by a dento-alveolar abscess of the lower second molar. Figure 418 is a radiograph of Fig. 417. Observe now that the hole caused by the abscess is seen where the roots of the lower second molar bifurcate. So in the practice of radio-

dontia the operator will often find, when looking for an abscess of a lower molar (particularly the second) a dark area in the region of the bifurcation of the roots and little or no bone involvement at the apices of the roots of the tooth under observation. The dark area in the region of the bifurcation will be looked upon as suspicious of a perforation through the

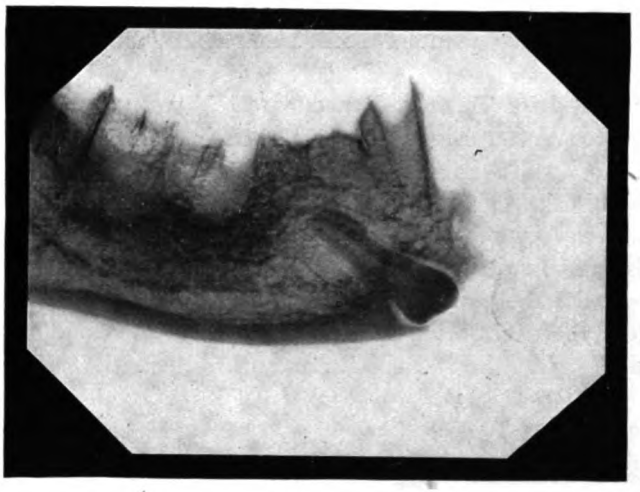

Fig. 418. Radiograph of Figure 417.

Fig. 419. What seems to be a post passing through the side of the root.

floor of the pulp chamber if the tooth is one in which there has been an effort made to open its canals. But the liability of the presence of a hole in the external alveolar plate near the region of bifurcation should not be lost sight of. The opening occurs in this region following the path of

least resistance, the path directly buccally or buccally and downward being through the very dense bone of the external oblique ridge. Abscesses at the apices of the lower molars often show the dark area representing the abscess indistinctly, the negative having a light haze thrown over it due to the density of the oblique ridges. Thus care must be exercised or abscess areas at the apices of the lower molars—particularly the second and third, will be overlooked.

Figure 419 shows what might easily be mistaken for a post passing through the side of the root. Notice, however, there is no bone destruction about the post which seems to penetrate the osseous tissue. What seems to be a post penetrating the osseous tissue is a bar for a Gilmore attachment, for a partial plate, resting on the gum tissue.



Fig. 419A. Radiographs of an extracted crowned tooth, made by directing the X-rays through the tooth from different angles. (By R. Ottolengui.)

Figure 419A shows three radiographs of an extracted, crowned upper cuspid, with the post of the crown passing through a perforation on the labial. The radiographs were made at different angles. Number one seems to show the post following the canal; number two seems to show the post passing through the distal side of the root, while number three shows the post passing through the labial side of the root.

Number one was made by directing the X-rays straight through the tooth from labial to lingual (X-rays No. 2, Fig. 419B). Number three was made straight through from mesial to distal and number two was made with the rays passing through the tooth in a disto-lingual direction (Fig. 419B, X-rays No. 3).

Figure 419C is a case from practice. Both centrals are perforated. The two radiographs show these perforations and fail to show them as the angle of the X-rays is changed. A careful study of both radiographs, using a rough study sketch similar to Fig. 419B, enabled the writer to state definitely that one post passed through the labial wall of the root while the other passed through the other tooth to the lingual. Examination after extraction verified the diagnosis.

18. To Assume That a Broach or Wire is Following a Canal Because it Cannot be Seen Extending Too Far to the Mesial or Distal.

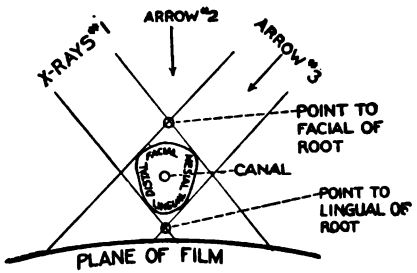

FIG. 419 B.

Fig. 419B. Diagrammatic cross section of a tooth root showing how the angle at which the X-Rays pass through the tooth may cast a shadow of a post passing through a perforation to the facial or lingual so it will have the radiographic appearance of passing to the mesial or distal or following the canal. With the rays passing through the tooth as indicated by "X-rays No. 1," a post passing far enough through the root to the facial will have the radiographic appearance of passing to the mesial while, if the post passes through the root on the lingual far enough, it will have the radiographic appearance of passing through the side of the root to the distal.

Direct the rays through the tooth as per arrow No. 3 and the reverse is true, i. e., a facial perforation has the radiographic appearance of being on the distal, while a lingual perforation has the appearance of being on the mesial.

With the rays passing through the tooth as per arrow No. 2, a post passing to the facial or lingual will have the radiographic appearance of following the canal.

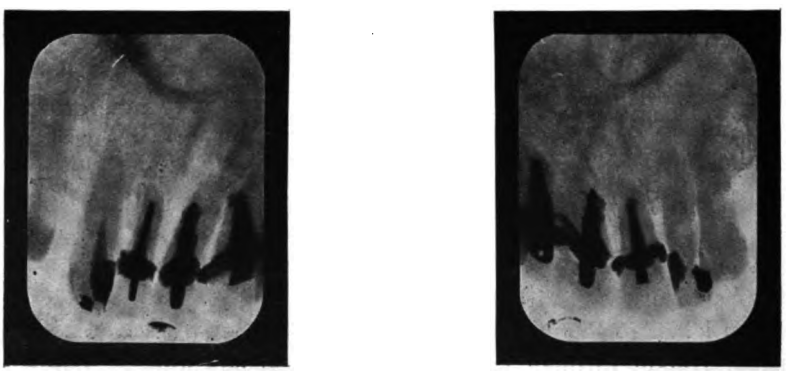

Fig. 419C. Two central incisors in the same mouth. The posts in the two centrals pass through perforations, one to the labial, one to the lingual. The two radiographs respectively both show and fail to show the posts passing through the perforations.

Figure 420 shows a wire apparently following the canal in a lower bicuspid. Figure 421 is of the same tooth and wire, but made at a different angle; the wire seems to be too far distally. In reality it is too far buccally. Study Figure 422.

19. To Mistake a Canal Filling Passing Into a Crooked Root For a Canal Filling Material Passing Through a Perforation Through the Side of the Root.

Figure 423 shows canal filling material passing into a crooked buccal root of an upper first bicuspid. The outline of the buccal root cannot be

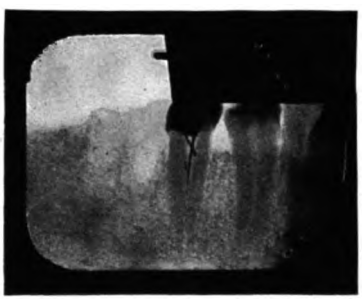

Fig. 420. Wire apparently following canal in lower bicuspid.

Fig. 421. Same case as Fig. 420 made at different angle. Wire seems to pass to distal, but in reality passes too far to the buccal. (See Fig. 422.)

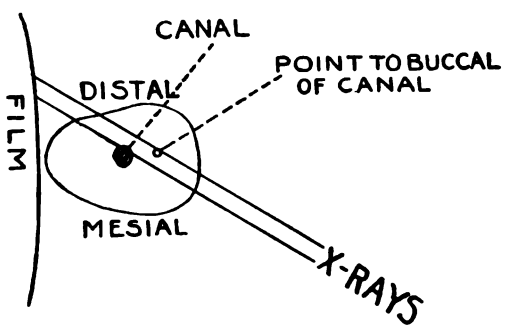

Fig. 422. Diagram explanatory of Fig. 421.

seen clearly and the case was diagnosed a perforation through the side of the root with the canal filling passing through it.

20. To State Definitely, From the Appearance of Flat Radiographs (Not Stereoscopic Radiographs) That Impacted Teeth Lie to the Lingual or Facial of the Other Teeth.

It is practically always impossible to determine, from a single flat negative, the facio-lingual location of an impacted tooth. The radiodontist should make stereoscopic radiographs or he should refrain from

making himself absurd by making definite statements regarding something of which he has no definite knowledge.

21. To Mistake a Small Cervical Filling For a Pulp Stone. See Fig. 178 and the description of it.

22. To Assume That a Filling in the Crown of a Tooth Enters the Pulp Chamber When it Does Not.

Fig. 423. The canal filling in the crooked buccal root of the first bicuspid was thought to be canal filling material passing through the side of the root; the outline of the buccal root is not distinct and so was not seen by the diagnostician.

Unless the filling enters the pulp chamber as in Fig. 444 or unless the cavity is a simple occlusal one without buccal or lingual extensions it is usually impossible to determine whether a filling in the crown of a tooth encroaches on the pulp or not. Proximo-occlusal fillings and fillings on the buccal and lingual surfaces often have the appearance of encroaching on the pulp when their shadow only *overlaps* the pulp in the radiograph. When it is suspected that a filling encroaches on the pulp, an ocular study of the tooth and filling should be made. This was done in the case of Fig. 444, for example, and the outline of the cavity in the tooth was such as to fail to explain at all the projection which seems to enter the pulp chamber. Hence, it was assumed that the filling did extend into the pulp chamber, and this diagnosis was accordingly made. Had there been an extension of the filling onto the buccal or lingual of the shape of the material, which, in this case, passes into the pulp chamber, this extension would have been held responsible for the appearance of filling material passing into the pulp chamber.

23. To Assume, From the Appearance of Flat Radiographs (Not Stereoscopic Radiographs) That the Root of an Upper Posterior Tooth Penetrates the Antrum.

It is impossible to determine from the appearance of a flat radiograph whether the root of a tooth penetrates the antrum or not. The ap-

pearance of the radiograph would be the same if the root passed to the buccal or lingual of the antrum as it would if it entered it. In radiographs made on films held in the mouth the roots of teeth may seem to enter or lap the antrum when they do neither. (Fig. 397.)

Fig. 424. Dark area in apical region of upper cuspid. This tooth is not abscessed; the bone change is due to abscess of the lateral incisor.

Fig. 425. Note that a radiograph would give no record of the labio-lingual depth of the abscess cavity. (Courtesy *Ash's Monthly.*)

24. To Fail to Take Into Account That an Abscess Cavity May Lap to the Lingual or Facial of the Adjoining Teeth, Giving the Radiographic Appearance of Their Involvement but Without Involving Them.

In Fig. 424 an abscess at the apex of the lateral incisor seems to involve the cuspid, but this is due to lapping of the abscess cavity to the lingual. The cuspid is a vital tooth. It is of normal color and responds normally to the electric test for pulp vitality.

25. To Fail to Consider the Element of Depth When Judging the Size of an Abscess Cavity.

Figure 425 is made from a photograph of a skull. Note the labio-lingual depth of the abscess cavity and how a radiograph would fail to indicate the true size of the cavity. This limitation of the radiograph must be constantly borne in mind.

26. To Mistake Normal Resorption of Bone, Due to Age, For Pyorrhea Alveolaris.

The fact is well established that the sharp point of bone seen in radiographs between teeth is lost as age advances. This change, due to age, should not be confused with pyorrhea alveolaris.

27. To Fail to Take Into Account the Effect the Tipping of a Tooth to the Lingual or Facial Will Have on the Appearance of the Tooth in the Radiograph.

Figure 426 shows a lower molar which seems to have very short roots. When extracted the roots of this tooth were found to be of normal length. Figure 427 illustrates why the roots of the molar in Fig. 426 appeared short—" the tooth was tipped lingually."*

Fig. 426. The roots of the lower first molar seem very short, but, upon extraction, they were found to be of normal length.

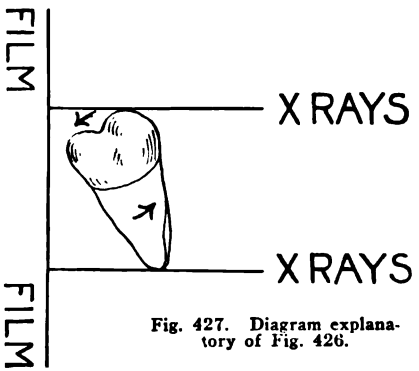

Fig. 427. Diagram explanatory of Fig. 426.

To obtain a true radiographic shadow of a tooth like the molar illustrated in Fig. 426 and diagramed in Fig. 427, it is necessary to direct the X-rays lingually and *downward* so as to pass through the tooth at right angles to its long axis.

28. To State Definitely That a Rarefied Area at the Apex of a Root Represents Infection, Without Considering the Anatomy of the Parts and the Symptoms and History of the Case.

It is very common practice for those unskilled in the interpretation of radiographs to consider nothing at all except the lights and shadows in the radiograph and to blandly call any rarefied area at the apex of a tooth " an abscess."

That things other than infection arising from the tooth may cause a rarefied spot at its apex has been pointed out elsewhere—See Figs. 393, 394, 395, 396, 399, 401, 403 and others.

When a rarefied area occurs at the apex of a root with an imperfect canal filling, the imperfection of the canal filling causes us, *almost* regardless of any other consideration, always to look upon the rarefied area as one which very probably indicates infection.

Do abscess cavities, which have been freed from infection, fill with new bone or do they fill with fibrous tissue? The question was discussed extensively a couple of years ago. Much evidence has been brought forth in the form of post-operative radiographs to prove that there is a recon-

* Dr. Ottolengui.

struction of bone in abscess cavities. The fact is established: bone will fill abscess cavities after proper treatment. But this proves only that we *do* get bone reconstruction in some cases; it *does not* prove that abscess cavities *do not* fill with fibrous tissue. Perhaps they do; perhaps they do not; the question is not settled.

An abscess cavity filled with uninfected fibrous tissue would have practically the same radiographic appearance as one filled with infectious material.

Since there is no doubt at all about the possibility of getting bone reconstruction in abscess cavities, and there is some doubt as to whether such cavities ever become filled with uninfected fibrous, cartilage-like tissue (it has not been conclusively proved that they ever do) we must consider it at least a *bad sign* when we fail to get bone reconstruction; then *take into account* the *local and general symptoms* and be governed accordingly in our conclusions. (See Appendix, Chapter XI.)

Knowledge of what treatment, if any, has been given will assist in determining whether or not a shadow at the apex of a tooth represents infection. As the size of the originally infected area increases the method indicated for overcoming the infection changes. A small area of infection can be overcome by forcing some disinfectant, such as phenolsulphonic acid or a three per cent. solution of tincture of iodine in water through the tooth into the infected area; a larger area can be disinfected by the ionization method; a still larger area may necessitate curettement and root resection; while extensive infection may necessitate extraction. Thus if a shadow persists at the apex of a tooth after treatment with phenolsulphonic acid, when the original infection was such as to indicate extraction or at least curettement, the shadow may be said to represent infection. After a case has been treated, when in doubt as to whether or not a shadow indicates infection it is well to ray the part repeatedly at intervals of two or three months. If the shadow gets larger, a diagnosis of infection may be made; if it gets smaller we may assume infection has been overcome for the time being, at least; if it remains the same it is very probable that infection has not been overcome, though, in the light of our present knowledge of the subject, the radiograph proves nothing conclusively one way or the other in this latter event. Noticeable bone reconstruction takes place usually within three months and large cavities are filled in about six months to a year.

When making a series of radiographs of the same case, great care should be taken to have the poses for the different radiographs as near the same as possible as change in viewpoint of observation of the part may change appearances greatly.

29. To State That No Infection Exists Because No Abscess Cavity Can Be Observed.

Infection in the end of an unfilled canal and in the periapical space may exist *without* destruction of bone. Just because there is not a sufficient amount of the right kind of infection to produce bone destruction

Fig. 428. Bone destruction and osteosclerosis at apex of upper first bicuspid.

does not mean that there is no infection at all. If the symptoms, local or general, indicate infection, unfilled canals should be looked upon with great suspicion, even if the bone is not destroyed. In such cases dense areas in the bone and hypercementosis may be taken as contributing evidence of infection.

A small abscess cavity just beyond the end of the root will always show in a well-made radiograph, but a *small* abscess cavity *at* the apex, on the facial or lingual side of the root, *may* fail to show. Visualize a *small* abscess on the buccal, *at* the apex, but not extending above it, in Fig. 414. It would fail to register—unless it were considerably wider than the root of the tooth mesio-distally—with the rays passing through the tooth as per arrow "X-rays No. 3," Fig. 412. With the rays passing through the tooth as per "X-rays Nos. 1 and 2," Fig. 412, it would very likely show in the negative. Hence, as I have pointed out elsewhere, the necessity of radiographing the same field at different angles. A single radiograph of a part does not, by any means, always represent a good *radiographic examination* of the part.

30. To Fail to Bear in Mind That Osteodensity as Well as Osteoporosity May be Caused by Infection.

As I have already stated (See under Mistakes 7 and 29) some osteodensity as well as osteoporosity may be caused by infection. This knowledge will often assist in rendering a correct judgment regarding radiographic findings.

Figure 428 shows both destruction and eburnation or sclerosis of bone. The bone destruction is just at the apex of the first bicuspid. Im-

mediately surrounding the area of bone destruction is a rim of dense bone. (In this case the permanent cuspid is missing, the temporary cuspid is shell crowned and about all of the root is resorbed.)

Figure 429 is a case in which we see an imperfect canal filling, and evidence of osteoblastic stimulation—which is probably infective in nature —at the apex of the second bicuspid. In this case it seems that we have practically no bone decalcification. While the canal filling in this case reaches the end of the root, I consider it imperfect because, judging from the buckled, bent condition of the gutta percha point, the canal filling does not fill the canal solidly full.

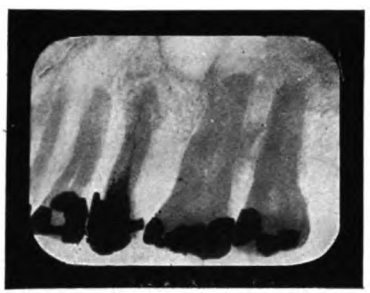

Fig. 429. Osteosclerosis apex upper second bicuspid.

Fig. 430. Bone destruction, bone eburnation and hypercementosis distal root, lower first molar.

Figure 430 shows (1) bone destruction, (2) osteosclerosis, (3) hypercementosis in the region of the apex of the distal root of the lower first molar.

31. To Assume, When Observing an Abscess Cavity at the Apex of a Tooth With a Well-Filled Canal, That the Abscess Occurred After Canal Filling.

It is such faulty reasoning that I may say it is lack of reasoning to point to a well-filled canal at the end of which is a large abscess cavity, and say, "This canal filling has failed. It is useless to fill canals as this one is filled." Of course, the abscess cavity may have existed for years before the canal filling was placed in the tooth, but the universal tendency is to assume that it did not, but that it developed *after* the canal filling was inserted.

It should also be remembered that there is something more to the treatment of pulp canals than the mere mechanical filling. No difference how mechanically perfect a canal filling may be it will fail unless the proper aseptic and antiseptic measures have been taken. Mechanical perfection of the canal filling is only *one factor* which contributes to the successful treatment of teeth; and, important as it is, it is not, in my

present opinion, as important as asepsis, antisepis and disinfection. A canal filling which simply reaches the end of the root but does not fill the canal full is, of course, not a good one, though it is often accepted as such.

32. To Expect to See a Fistulous Tract.

It is a human characteristic to see the things we are looking for and rather expect to see, or want to see. Hence, the many misinterpretations of radiographs. It is very seldom possible to observe a fistulous tract unless it is injected with some agent such as bismuth paste.

33. To Give Positive Diagnosis of Pulp Stones From the Appearance of One Radiograph.

Even when the finding can be observed quite clearly the writer usually deems it expedient to re-ray the part before giving a diagnosis of pulp stones.

34. To Try to Make One Radiograph Do the Work of Two, or Several.

It is not an uncommon mistake to try to make one small film negative take in, say, for example, the central incisor, the lateral incisor, the cuspid and the first bicuspid. While all of these teeth might be radiographed on one negative, some or all of them would be distorted. It would be better to make two negatives.

It is a mistake to radiograph one side of the jaw looking for, say, an unerupted bicuspid, and assume that the presence or absence of the unerupted tooth as revealed in the one radiograph, is sufficient to indicate the same condition in the other side of the jaw. (Fig. 302.)

One radiograph of a part is simply *one* view of the part from *one* viewpoint. No one thing contributes more to mistakes in diagnosis than pinning one's faith implicitly upon the appearance of a single radiograph. The more radiographic work I do the more I find myself radiographing the same part again and again before venturing an opinion.

35. To Mistake Hypercementosis For a Poorly Made Radiograph.

In some cases of hypercementosis it is impossible to show the outline of the root of the tooth distinctly. (Fig. 431.)

36. Not to Know the Difference Between a Good Radiograph and a Poor One.

Figure 432 shows a wire apparently in the canal of an upper lateral. Figure 432, however, is a distorted radiograph due to the angle of the X-rays and bending of the film. Figure 433 is of the same tooth, is a good radiograph, and shows the wire passing through a perforation to the distal.

Figure 434 shows the outline of the roots of a lower, first molar very indistinct. Figure 435 is of the same tooth but this time the rays

Fig. 431. Hypercementosis of upper bicuspids. The outline of the roots of the bicuspids is not distinct, due to the hypercementosis, not to some fault in technic.

Fig. 432. Wire apparently following canal in upper lateral root. Distorted radiograph.

Fig. 433. Same as Fig. 432. Radiograph not distorted. See wire passing through side of root to the distal.

have been directed through the tooth at a different angle (arrow No. 3, Fig. 436) and the outline of the roots is comparatively distinct.

Fig. 436. When the X-rays pass through the tooth as indicated by arrows 1 and 2, Fig. 436, the outline of the roots will be more or less indistinct; when the rays pass straight through the tooth, as indicated by arrow No. 3, Fig. 436, the outline of the roots in the radiograph will be distinct unless there is hypercementosis, osteodensity, or tipping of the tooth to the buccal or lingual.

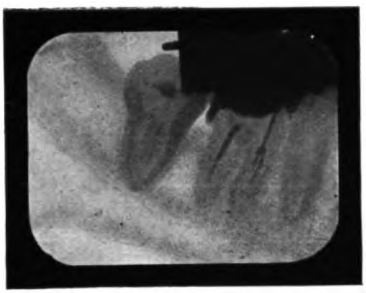

Fig. 434. Outline of roots of lower first molar indistinct. (Rays passed through tooth as per arrow No. 1, or No. 2, Fig. 436.)

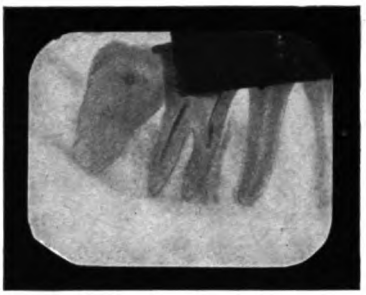

Fig. 435. Outline of roots of lower first molar more distinct than in Fig. 434. (Rays passed through tooth as per arrow No. 3, Fig. 436.)

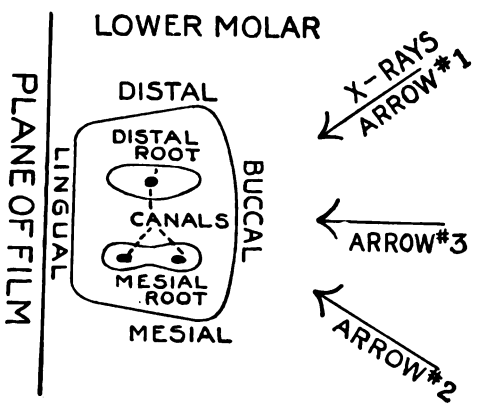

Fig. 436. Diagrammatic cross section of a lower first molar through the pulp chamber.

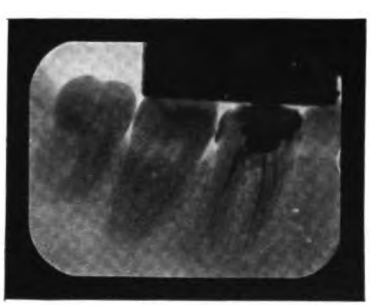

Fig. 436A. Wires in lower first molar. X-rays passed through tooth diagonally; arrows No. 1 and No. 2, Fig. 436.

Fig. 436B. Same case as Fig. 436A, made with X-rays passing through tooth as indicated by arrow No. 3, Fig. 436. The wires in the mesial canals are superimposed throughout most of their length.

With the rays passing through the tooth as per arrow No. 1, the shadow of the mesio-buccal canal will be thrown to the mesial of the mesio-lingual canal (see Fig. 436A), with the rays passing through the tooth as per arrow No. 2, the mesio-buccal canal will be thrown to the distal of the mesio-lingual canal and the appearance of the radiograph will be similar to Fig. 436A; with the rays passing through the tooth as per arrow No. 3 of the two mesial canals will be superimposed, one over the other—Fig. 436B.

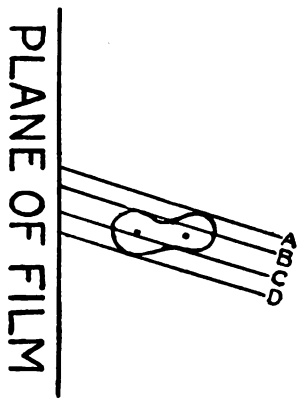

Fig. 436C. Cross section of mesial root of lower molar. See text.

Fig. 436C. In this connection it may prove profitable for the reader to study Fig. 436C, which diagrams a cross section of the mesial root of a lower molar with the X-rays passing through it as indicated by arrows one and two in Fig. 436. Note that the shadow cast on the film between lines B and C would be denser than between the lines A-B or C-D. Thus on the radiograph the outline of the root would be either not well defined (Fig. 434) or the root would have the appearance of having a necrotic surface (Fig. 205 is a fine example).

Fig. 436D. Figure 436D shows two radiographs of a lower first molar. The radiograph made on the small film shows two very short canal fillings in the mesial root, one of which seems to pass through the side of the root to the mesial. In the large radiograph, made on a plate, the two canal fillings in the two mesial roots are superimposed one on the other, and they do not have the appearance of passing through the mesial side of the root. The canal filling in the small film radiograph seems to pass through the side of the root because where the filling ends the shadow of the root outline is faint as between lines A-B and C-D, Fig. 436C.

Fig. 436D. Two radiographs of the same lower first molar. In one the canal filling seems to pass through the side of the root; in the other it seems to follow the canal.

Figs. 437 and 438. Figure 437 shows what seems to be a tumorous growth in the upper molar region. It is not a tumor; it is the malar process thrown in the position it occupies because the X-rays were directed through the parts from a posi-

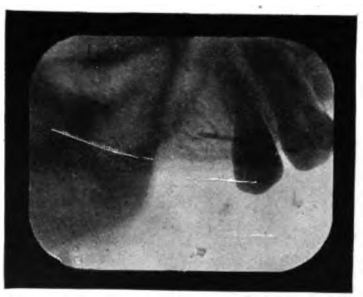

Fig. 437. Malar process having appearance of tumor.

Fig. 438. Same as Fig. 437, made at different angle.

tion which was too high. Figure 438 is of the same case, made with the X-rays properly directed through the parts.

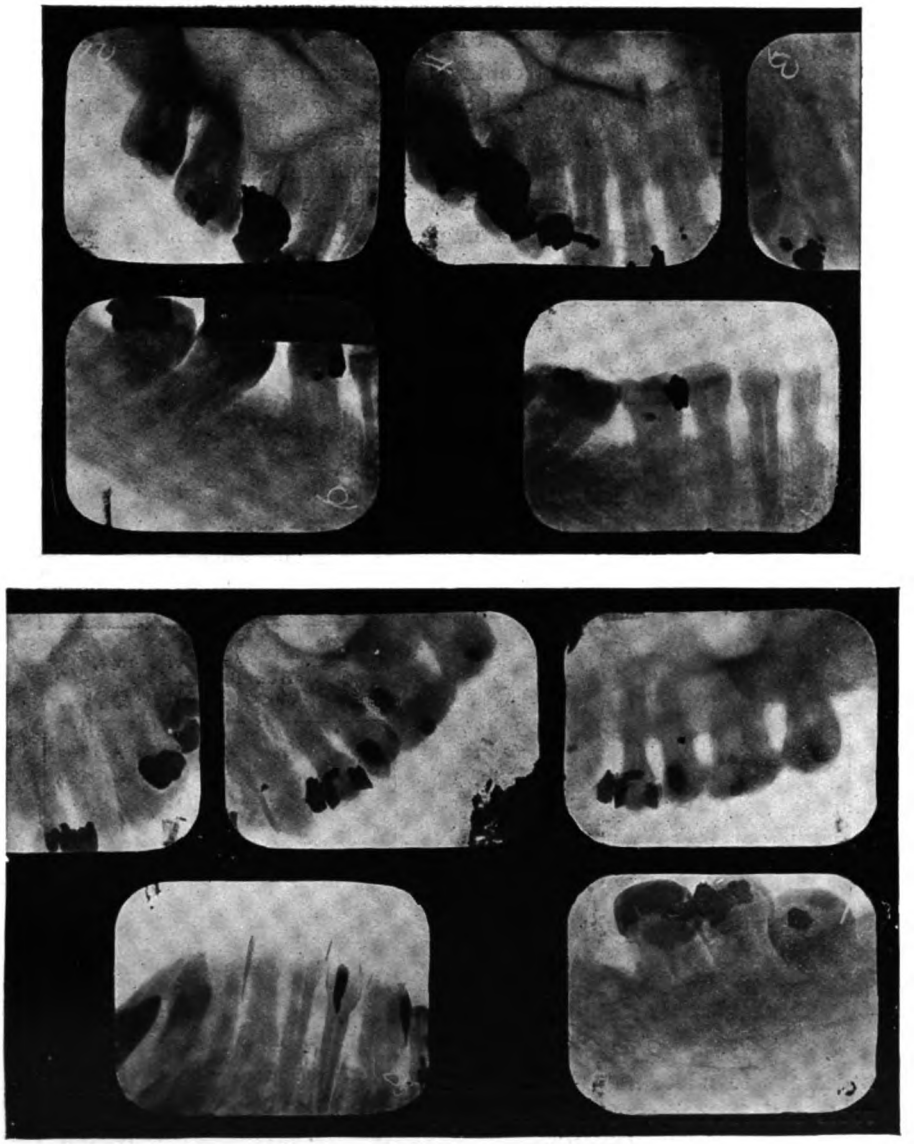

Fig. 439. "Horrible Example." A number of radiographs intended to be a radiographic examination of all the teeth in the mouth. In reality it is a radiographic examination of only a very few teeth.

37. To Make Just One Radiograph of a Part and Stop, Calling It a Radiographic Examination.

The inexpedience of depending too implicitly on the appearance of one radiograph has already been demonstrated in this chapter.

Figure 439 shows the result of applying the principle of making just one exposure of a part and calling that a radiographic examination of the part. Figure 439 is intended to be a radiographic examination of all of the teeth, but most of the radiographs are so poor that it is really a radiographic examination of only a very small number of teeth.

I cannot impress this point too strongly, the making of a radiograph is equivalent to having a look at the part from one viewpoint. It is often necessary, if we wish to make a thorough radiographic examination, to view the part from different viewpoints. It is very often, in fact, usually

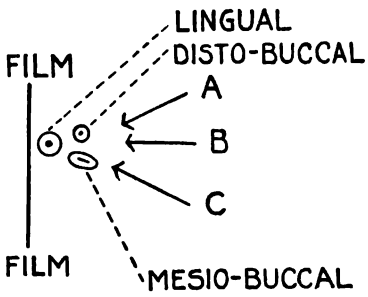

Fig. 440. Cross section upper first molar.

Fig. 441. Angle of X-rays, arrow B, Fig. 440.

Fig. 442. Angle of X-rays, arrow A, Fig. 440.

Fig. 443. Angle of X-rays, arrow C, Fig. 440.

necessary to make more than one radiograph to view the upper molar roots satisfactorily. Study Fig. 440.

Figs. 440, 441, 442 and 443.

Directing the rays through the part indicated by arrow B will usually throw the mesio-buccal root a little to the mesial of the lingual root as seen in Fig. 441.

Directing the rays through the part as indicated by arrow A, will throw the mesio-buccal root farther to the mesial of the lingual root. (Fig. 442.)

Directing the rays through the part as indicated by Arrow C, will throw the disto-buccal root to the distal of the lingual root. (Fig. 443.)

Quite often, when the disto-buccal root is thrown to the distal of the lingual root, the end of the disto-buccal root still cannot be seen—it seems to be absorbed. (See Fig. 429, The First Molar.) This appearance is due to the fact that the root is so small that it does not throw a shadow of sufficient density to be seen clearly. This must be kept in mind or the radiodontist will mistake normal conditions for disease in the apical

Fig. 444. Uneruptcd, malposed, lower cuspid. Age of patient about 40.

region of the disto-buccal roots. There is also sometimes a normal porosity of bone in the apical region of the mesio-buccal root which may be mistaken to indicate disease if the operator does not know that such a condition *may* be normal. To differentiate, apply the electric test to the tooth to determine pulp vitality, look for osteosclerosis and take into account the *degree* of darkness in the suspicious area.

The roots of the second and third upper molars are often so close together, and the malar process is so likely to cast a shadow over them, that it is not infrequently impossible to distinguish the different roots.

38. To Depend on Intra-Oral Radiographs Alone, Especially in Cases of Neuralgia, Facial Fistula, Impacted Third Molars and Abscess of the Lower Bicuspids.

Case: Facial fistula. A radiograph, made on a small film, showed very small spots indicating a slight infection at the apices of the roots of a lower second molar. Continued treatment of the tooth did not benefit the case. It was decided that the molar should be extracted, but before doing this another radiograph was made; this time on a large plate. The second radiograph, made on the plate, revealed the presence of an abscess at the apex of the lower first bscuspid, *which tooth had no carious cavity in it.* This tooth, the lower, first bicuspid, was opened and treated and the case recovered promptly. The large plate should have been made in the first place, which would have enabled the operator to get at the seat of the infection without delay.

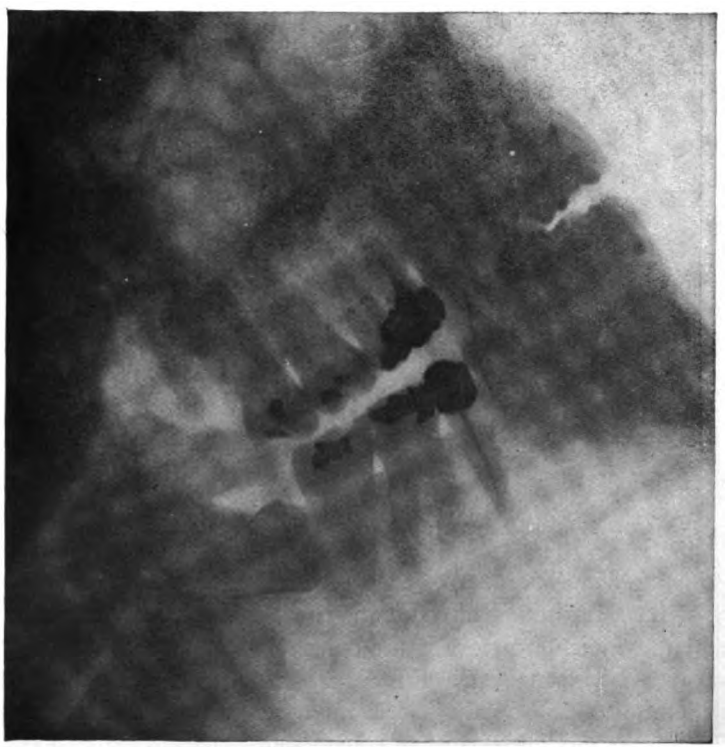

Fig. 445. Unerupted, malposed, upper and lower third molars.

Figure 444 is the radiograph made of a case of neuralgia of many years standing. The shadow in the anterior region of Fig. 444 is an un-

erupted lower cuspid. Note also the very small abscess of the lower third molar. The abscess is no larger than an unusually large periapical space, but observe the filling in the crown of the tooth enters the pulp chamber and there is no canal filling in the canals. Had a small film been used and the condition of the lower third molar disclosed it is highly improbable that the examination would have been carried further and so the real cause of the trouble would not have been located. I say the real cause of the trouble would not have been located, because removal of the malposed tooth, without treatment of the third molar, effected a cure.

When making radiographs for impacted third molars, there will be less distortion, and the radiograph is more likely to show *all,* instead of just a part, of the unerupted tooth and the surrounding parts, if it is made on a plate.

Figure 445 is a radiograph of a case of neuralgia, in which both the dentist and the patient insisted that the lower third molar had been extracted. The radiograph was made in a search for an upper third molar. It shows both an upper *and a lower third* molar. Of course, the lower third molar would not have been discovered had the radiograph been made on a small film.

The advantage of the large extra-oral radiograph over the small intra-oral one for radiographing the lower bicuspids is given in the discussion of mistake No. 1.

39. To Fail to Use a Reading Glass When Studying Negatives and So Avail One's Self of the Great Assistance Rendered by the Practice.

The advantage in using a reading-glass to study dental radiographs is so great, and the inconvenience of obtaining and using such a glass so slight, that it must be considered a mistake not to avail one's self of this valuable aid.

40. To Fail to Use the Electric Test for Vitality of Pulps in Connection with Radiographic Examination.

*The use of some electric machine to test the vitality of the pulp, I find absolutely indispensable in the practice of radiodontia. Likewise it will be found indispensable to the general practitioner of dentistry once he learns to use it and depend on it. The technic of applying this test is extremely simple.

Figure 446 is a small machine, of the writer's design, which may be used to test teeth to determine the vitality of their pulps. In principle of construction it is a Faradic machine. The source of the current to excite the machine is the ordinary dry cell, such as can be obtained anywhere

* The electric test for pulp vitality is not original with the writer.

in the civilized world. By means of a little step-up transformer or coil the current of high amperage and low voltage, from the dry cell, is transformed into a current of comparatively low amperage and high voltage or pressure. The amount of output current delivered by the machine is controlled by a rheostat, or a metal sheath, which slides in between the primary and secondary winding of the coil. With the sheath in the current is weakest. This control is such that the output current can be gradually increased from practically nothing to the capacity of the machine.

Technic for Using Electric Pulp Testing Machine.

Plug cords, to which the "hand" and "dental" electrodes are attached, into machine. (There are three places or sockets into which the cords may be plugged, marked "L," "M" and "R," Fig. 446. With the cords plugged

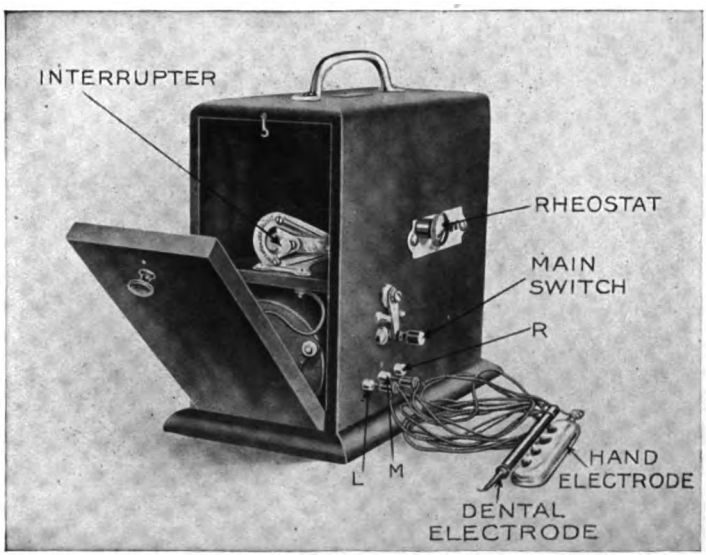

Fig. 446. Author's machine for testing teeth for vitality of the pulp. Size 8½ inches long, 4½ inches wide, 7 inches high. To date, Dec. 6, 1917, this machine has not been perfected to conform fully with the writer's ideal.

into "L" and "M," as in Fig. 446, the output current is weakest. With the cords plugged into "L" and "R" the output current is strongest. Figure 446 is, at this time, still in the process of construction. It is my aim to have the machine constructed so that the operator will, except in the rarest cases, always plug into "L" and "R" and find, with this attachment to the machine, that he can get all the gradation of current strength he desires.)

Polarity: It makes no practical difference about polarity; either electrode may be attached to either socket.

The dental electrode is insulated save for the metal point at the end. Wrap the metal point with cotton and moisten the cotton with water or sodium chlorid solution.

Have the patient hold the hand electrode.

Turn the main switch, when there should be a humming noise. If there is no humming noise, adjust the interrupter screw.

Start with the resistance of the rheostat in, that is, with the current weak, and touch the tooth to be tested with the dental electrode. Advance the rheostat as necessary to get sensation. The sensation will occur in the tooth only—not in the hand—providing the pulp is vital. If the pulp is not vital there will be no sensation with the machine operating at its capacity. Use enough current to cause the patient to jump or flinch slightly but definitely.

Take care not to touch the patient with the dental electrode anywhere except on the tooth to be tested, as the sensation would be unpleasant.

Limitations and Points in Technic.

Crowned teeth cannot be tested.

Teeth with large metal fillings: Sometime teeth with large metal fillings in them do not respond to the electric test when their pulps are vital; because the stimulus of the metal filling has caused the pulp to recede so far. Sometimes, but less frequently, teeth with large metal fillings *do* respond to the electric test when their pulps are not vital, because the current is conveyed through the tooth from the place where the dental electrode was applied into the metal filling, through it, into the gum tissue or pericemental membrane or approximating tooth.

Teeth with pulp stones and teeth where the pulp has receded, due to the age of the patient, are less sensitive to the electric test.

Teeth with abraded surfaces are usually quite sensitive when the electrode is applied to the exposed, or nearly exposed, dentin. However, in some such cases the pulp has receded, when the teeth are less sensitive to the test.

In spite of the limitations enumerated, the fact remains that the electric test for determining the vitality of the dental pulp is by far the best we have. Coupled with the use of radiographs it enables us to determine the vitality of the pulps of most teeth.

When testing a tooth with a proximo-occlusal or proximo-incisal filling, or any filling passing beneath the gum margin, *do not* touch the filling—touch the enamel only. When testing such teeth, two or more

thicknesses of rubber dam may sometimes be placed between the filling and the tooth approximating the filling. If kept dry, the rubber acts as an insulation, keeping the current from passing into the approximating tooth.

A tooth with a simple filling, which does not come in contact with the gum tissue or an approximating tooth, may be tested by touching the dental electrode to the filling. When this is done, the current should be weak.

The teeth being tested should be kept dry; with cotton rolls, if necessary, otherwise the current will pass into the gums, pericemental membrane and approximating teeth, through the saliva.

Electrophobia. When the electric test is suggested most patients will offer some objection, saying they "can't stand electricity." You will gain your patients' confidence and co-operation by telling them that you can control perfectly the amount of current used. Then prove this to them. Close the main switch, which will start the mechanical interrupter and cause a humming noise. Throw in all the resistance of the rheostat, or have the metal sheath clear in, and say to the patient: "Now I am using so little current you will scarcely feel it, *if you feel it at all.*" Touch a tooth; most any tooth except the lower incisors. (The amount of current necessary to produce sensation varies directly according to the size of the tooth. Thus, the patients would be less likely to feel a weak current on an upper central or cuspid than they would on the smaller teeth just mentioned.) With the current weak the patients will not feel it or the sensation will be very slight and not really painful. Now instruct the patients that you will use only enough current to produce a momentary, warm, stinging sensation in the tooth, and proceed to do so. As soon as you show the patients that you can control your machine, the dread of its use is practically gone. A good psychic effect will be gained by calling the patients' attention to the fact that you do not wish them to try to endure pain, but simply to let you know as soon as pain is produced so you may stop it immediately.

Liability of Accident. A machine of the nature of the tester under consideration has an advantage over any switchboard attachment or any machine deriving its electricity from some powerful supply in that, in case of accident or improper use, no serious accident can occur, because the source of electric supply, the dry cell, is so small. One dry cell cannot produce enough electricity to cause a serious or very painful accident. This should appeal to anyone, but particularly to men whose knowledge of electricity is limited.

Case in Practice. Figs. 447A and B.

The extreme value of the electric test for pulp vitality can best be illustrated by recounting its use in the following case: The end of the root of an upper lateral was resected to cure an abscess. The wound made at the time of the operation did not heal normally. A radiograph was made, Fig. 447A. It seems to show that the central is involved in the lateral's abscess cavity. The central was tested for vitality of its pulp. It responded to the electric test, indicating a vital pulp. Another radiograph was made, Fig. 447B. This second radiograph, made at a different angle, shows no involvement of the central, and what may or may not be an involvement of the cuspid. The shadow passing to the apex of the cuspid

Fig. 447A. The central incisor seems to be involved in the abscess.

Fig. 447B. Compare with Fig. 447A of the same case.

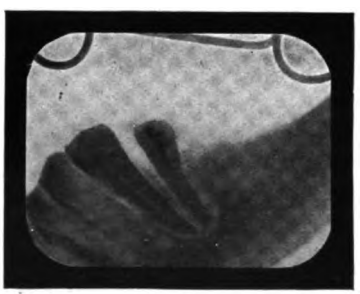

Fig. 448. An abscess which seems to involve both the lower first bicuspid *and the cuspid.*

Fig. 449. A very small abscess of an upper bicuspid.

does not show clearly. The cuspid was tested and its pulp did not respond to the application of the current. It was opened and found to contain a putrescent pulp. Neither the central incisor, at first suspected, or the cuspid, finally opened, had carious cavities in their crowns. A

satisfactory diagnosis in this case would have been impossible without the use of the electric tester, as well as the X-rays.

Fig. 448. Another case: Figure 448. From the appearance of the radiograph alone, one inexperienced in reading radiographs would be likely to say that two teeth, the lower first bicuspid and the approximating cuspid, are involved in an abscess, since the evidence of bone destruction seems to include the apices of the roots of both teeth.

However, the application of the electric test to the cuspid proved it to have a vital pulp and treatment of the bicuspid alone effected a cure.

Fig. 449. Case: The evidence of bone involvement at the apex of the bicuspid in Fig. 449 is so slight that a definite diagnosis from the radiograph alone should not be made. The appearance of the radiograph, coupled with clinical signs and symptoms and the fact that the tooth did not respond to the electric test, however, enables the diagnostician to state definitely that the pulp in the tooth is not vital and that an abscess is forming.

41. To Make Radiographs of Every Tooth in the Mouth in All Cases Where the Teeth Are Being Examined to Locate Foci of Infection.

In cases of arthritis, endocarditis, neuritis, gastritis, becteremia and other "systemic" diseases, now attributed to focal infection, it is not *absolutely necessary* to radiograph *all* of the teeth in *all* cases. Where the test can be applied, the electric test for pulp vitality may be made and, if positive, a radiographic examination is usually unnecessary, *unless* one wishes to observe, for example, the extent of bone destruction, due to pyorrhea. Thus the number of teeth which should be rayed may, in some mouths, be greatly reduced. This is advantageous to the patient in that the cost of the examination is reduced, and advantageous to the operator in that he reduces the dose of X-rays. It is always wise to expose the patient to the rays as little as possible, and likewise it is the sensible thing for the operator, for his own welfare, never to light his tube unnecessarily. Regions from which teeth are missing should always be radiographed to see that there is no piece of gum-covered root or unerupted tooth. (See Appendix to Chapter VII under heading "Oral Foci of Infection," page 416.)

In concluding this subject of radiographic misinterpretation, let me repeat what I said at the outset lest I be grossly misunderstood: The use of the radiograph is an absolute necessity in the practice of dentistry. This extensive discussion of its shortcomings is, to the man who can see

past his nose, a recognition of the fact that radiographs must be used. It is not a harangue against their use, but an effort to stop their misuse and abuse.

Oral Foci of Infection.

I realize that, in the foregoing rather exhaustive consideration of the interpretation of radiographs, I have not answered, to the point of setting his mind at ease, the man who is asking, " how to read radiographs " for the very simple and apparent reason that the man who is asking " how to read radiographs " not only wants to know how to interpret radiographs but he also wants to know *how to treat infection revealed by radiographs.* For the answer to this latter query it is a pleasure to be able to refer my readers to such an excellent text as Thoma's " Oral Abscesses."

Allow me, however, to express myself briefly on this subject. The radiograph gives a very good idea of the amount of bone destruction in cases of dento-alveolar abscess and pyorrhea if intelligently interpreted. The treatment indicated varies greatly according to the amount of bone destruction. But granting that we know the exact amount of bone destruction, different operators will always have somewhat different opinions as to the course of treatment indicated. One operator will excise the root end of an abscessed tooth, while another operator will treat by ionization. Both operators may be able to overcome infection in their respective ways. The treatment indicated depends not only on the condition of the case to be treated, but upon the personality and ability of the operator. It is not good sense to assume that the same treatment of an infected tooth is indicated regardless of the operator. Some operators should extract teeth which other operators should save. The object, when treating infected teeth and contiguous parts, remains the same, namely, eradication of infection. Men of ordinary ability simply cannot follow the methods of men of extraordinary ability. (Some results of treatment of abscesses by forcing disinfectants through the canal into the abscess area, by ionization and by root resection are illustrated in the Appendix Chapter XI, which will give the reader some idea of what can be accomplished by these methods and so help him decide which one to employ in certain cases.)

It is extremely difficult to say any definite thing which will apply to all cases in a general way. However, I believe I am conservative when I make this statement: If a tooth, showing bone involvement at its apex, is to be treated through the pulp canal, the canal must be open through the end; it must be filled just to, or through, the end, and post-operative

radiographs must be made at intervals of two or three months for about a year, or until the abscess cavity is filled with new bone. An abscess cavity which shows no constructive bone change at all at the end of six months after treatment is very probably still a source of infection. As a generality, it may be stated that if new bone ever will be built into an abscess cavity, some reconstruction will take place within the first six months or sooner, and the reconstructive change will be practically complete in about a year.

What should be done with teeth, the canals of which are not well filled but which show radiographically no bone involvement at their apices? is a most disturbing question. The idealist's answer would be,

Fig. 450. Cement fillings.

"insert perfect canal fillings or extract the teeth." This advice may, or may not, be good. The question is debatable, with *everything in favor of the idealist,* however. But certainly, when a patient is very seriously ill with some disease which might be attributed to a focus of infection, all of the pulpless teeth in such a patient's mouth should, at least, have a well-filled canal or they should be extracted.

Patient's Physical Condition

It is not idealistic, perhaps, but it is practical, to be governed in the treatment of infected teeth by the patient's physical condition. When the physical condition is good, more conservative treatment can be given the teeth. When the physical condition is bad and the patient is suffering from some disease which may be attributed to mouth infection, more radical treatment (freer surgical interference) must be given for mouth infection.

Rambling Discourse.

Do the Various Canal Filling Materials Show in Radiographs?

The writer filled canals in dissociated teeth with fifteen different canal filling materials, most of them proprietary pastes. All of these materials showed in radiographs. One year later the teeth were again radiographed and still all the different kinds of canal filling material showed unchanged. Had the teeth been in the mouth, it is not impos-

Fig. 451. Case of antral empyema.

sible that some, at least, of the paste canal filling materials would have shown some change one year after insertion. That the presence of most

any sort of canal filling can be demonstrated radiographically immediately after its insertion is a fact, but whether the various pastes, cement and paraffin combination fillings can be observed some time after insertion, is a matter as yet not definitely settled. The writer's experience at

Fig. 451A. The arrows point to a shadow which has the appearance of a tooth just starting to form in the antrum. The shadow is caused by the dense bone along the lower border of the malar bone.

this time leads him to believe that some cannot, which would seem to indicate that they are not permanent.

Gutta-percha is a permanent canal filling which is always radiographically visible.

Cotton with iodoform on it can be observed radiographically in canals.

Paraffin, as a canal filling, unmixed with anything else, can not be radiographed successfully.

Silicious Cement. Figure 450.

Silicious cement is more penetrable to the X-rays than oxyphosphate of zinc, colorless copper or black copper cements. (See Fig. 450.) The filling on the extreme right is silicious cement.

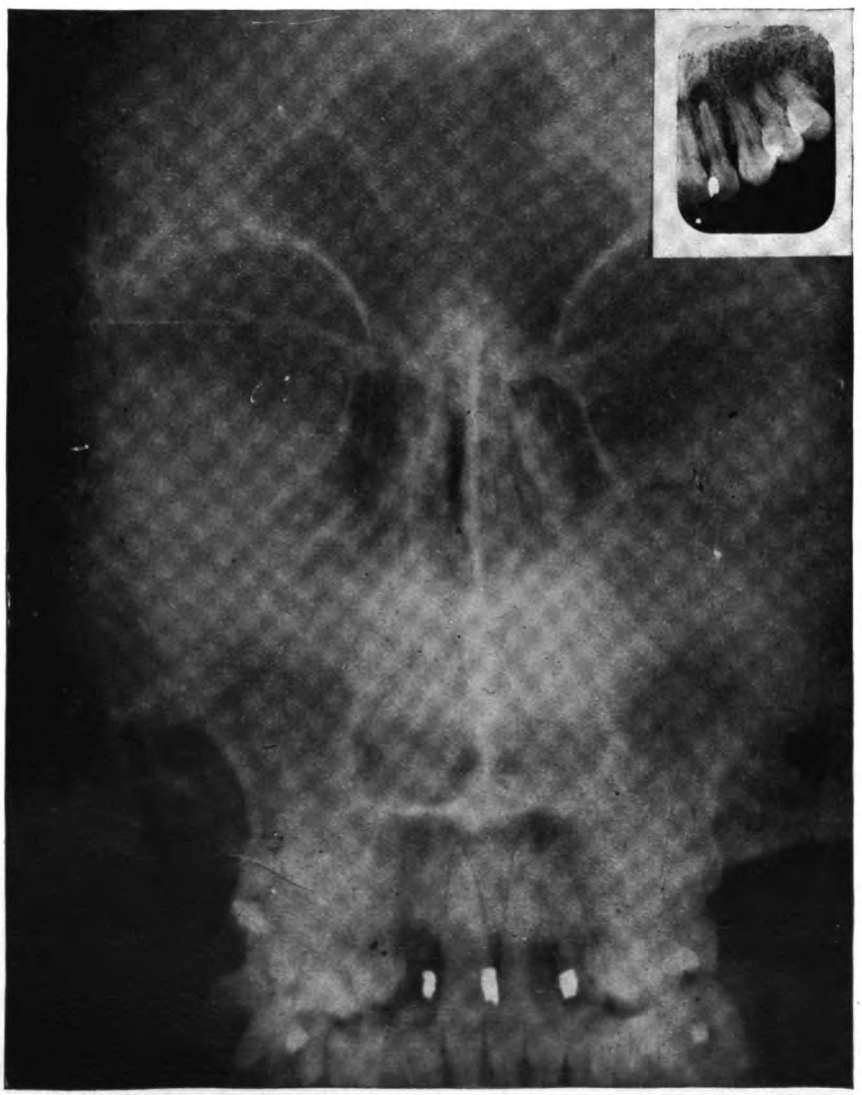

Fig. 452. Case of suspected frontal sinus or antral empyema. An abscessed upper lateral incisor located.

Cases from Practice.

To demonstrate the skill one may acquire from reading a great number of radiographs, observe Figure 451. It is highly improbable that one not familiar with head radiographs will be able to observe anything of significance

Fig. 452A. From the time of the first acute attack, for four years, this tremendous dental abscess had caused the patient no pain whatsoever.

in this plate, yet from a careful study of it, a diagnosis of antral empyema was made, the verity of which was proved by operation.

Figure 452 was of a case of suspected antral or frontal sinus empyema. The frontal sinuses show clear, and the antra are clear save for the shadow cast over them by the petrous portion of the temporal bone,

(Figure 452 was made from a pose with the head against the plate as in Figure 111 but with the X-rays directed diagonally forward from a point just back of the base of the occipital bone. Such a pose gives a very hazy view of the anterior teeth, a good view of the frontal sinuses and a view of the antra obscured by the shadow of the petrous portion of the temporal bone.) Observe a small spot at the apex of the lateral incisor on the right. A small intra-oral radiograph was made and shows an abscess cavity at the apex of this lateral. The patient would not consent to root resection; the lateral was therefore extracted and the pus discharge from the nose ceased. (See Figure 425.) The diagnosis in this case



Fig. 453. Diagnostic illuminating or view box, for observing X-ray negatives.

resulted from a thorough study of the large plate (Figure 452), in which the suspicious area at the apex of the lateral was first observed. A careless, or thoughtless examination of the antero-posterior plate would have resulted in failure to make the correct diagnosis.

Chronic Abscess and Pain.

It is a well-known fact among most dentists that a chronic abscess may exist without causing any pain or any local sensation at all for that matter. But all dentists do not know this as well as they might, nor do near all physicians; and the public scarcely knows it at all. It is a fact which

should be repeated again and again. I have seen a case recently with half of the palatal portion of the superior maxillary bone destroyed, the only symptom given by the patient being, "one side of the roof of my mouth seems a little softer than the other." When explaining these things to patients I have found that I can overcome incredulity by



Fig. 454. Special dental view box for observing small X-ray negatives.

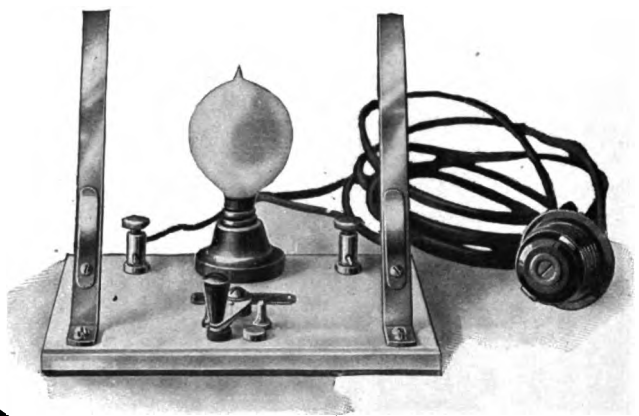

Fig. 455. Special dental device for observing dental X-ray negatives.

directing attention to the well-known fact that large parts of the lungs may be lost from tuberculosis with little or no pain in the lungs. (See Fig. 452A.)

View Boxes. Figure 453 is a type of view box which has entirely replaced the type illustrated in Figure 122.

Special dental view boxes and illuminating devices are illustrated in Figures 454, 455 and 456.

Marking Negatives. Dr. Edmund Kells, Jr., offers a scheme for marking small film negatives for identification by punching a small hole in the negative with a plate punch and tying a string, with a small price-tag-like label on it, to the negative which will certainly eliminate the possibility of "mixing" negatives by getting the negatives from one patient's envelope into another patient's envelope.

Filing Boxes or Cabinets.

I would earnestly advise that some sort of filing box or cabinet be used by all who use radiographs. Otherwise negatives will be lost or so chaotically distributed about the office that they can never be found when needed.

Dr. Ottolengui's New Words.

While it is true, in a general, inaccurate way, that X-rays penetrate substances inversely in proportion to their density, it is rather a loose way of stating the action of the rays. Dr. Ottolengui has accordingly coined the following words: Radioparent and radioparency, radiolucent and radiolucency,



Fig. 456. Special dental illuminating device for displaying and observing dental X-ray negatives.

radiopaque and radiopacity from the words transparent and transparency, translucent and translucency, opaque and opacity. Thus we might speak of a shadow in a radiograph something like this: "The small radiopaque area is, I believe, a piece of tooth root." Or instead of referring to a rarefied area at the apex of a tooth we would say: "There is a radioparent or a radiolucent (depending on the degree of X-ray penetration) area at the end of such and such a tooth."

It seems to me these words will prove to be most useful.

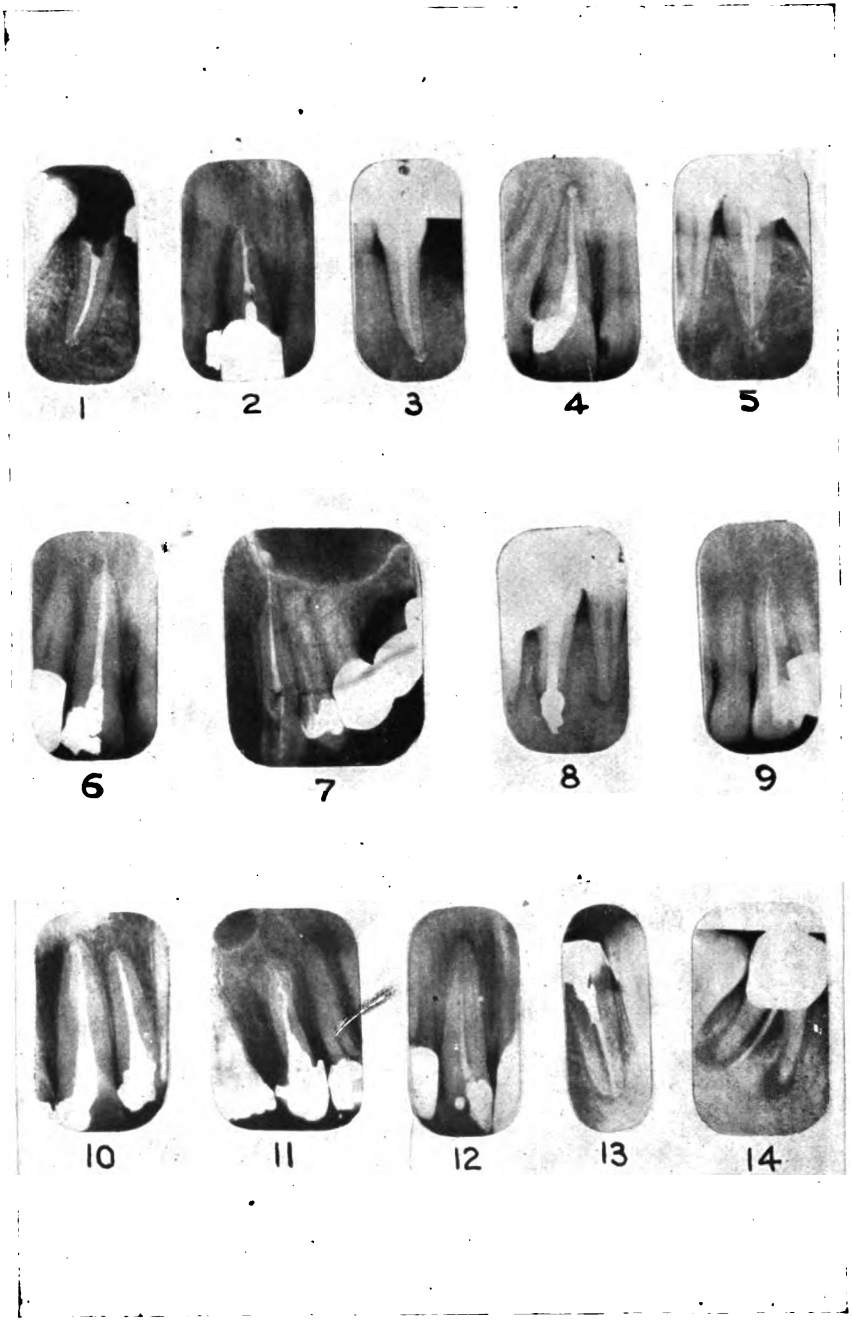

Chart A A

Chart AA

Illustrating different sorts of canal fillings as seen in radiographs

The arrangement is somewhat in the order of the excellency of the filling.

No. 1. Canals filled full. Three apical foramina filled just through the end of the root.

No. 2. Canal filled just through end. Auxiliary canal, to the mesial, filled.

No. 3. Canal filling material encapsulating the end of root. We see through the encapsulating material. When the material encapsulating the root is thicker—as it usually is—the radiograph appears to show a body of gutta-percha beyond the end of the root instead of a cap over it.

No. 4. Root end encapsulated and a little body of gutta-percha in periapical space.

No. 5. Canal filling material through end of root and filling into cancellous places in bone. More material through than desirable.

No. 6. Gutta-percha point passing through apical foramen intact, differing from Nos. 3, 4 and 5 where mushy eucalyptopercha or chloro-percha has "mushed" or "oozed" through apical end. Not so desirable because perhaps apical foramen is not filled full—perhaps gutta-percha point just passes through without filling the opening through which it passes.

No. 7. Too much canal filling too far through apical foramen. In this particular case, however, no evidence of irritation developed.

No. 8. The practice of filling abscess cavities full of the Callahan gutta-percha-rosin mixture is being tried by some. The expediency of this course has neither been proved nor disproved.

No. 9. This canal filling *very probably* reaches the end of the root of the tooth, but we cannot be *certain* of this from the appearance of the radiograph. We cannot be absolutely certain any canal filling reaches the end unless a little passes through.

No. 10. These canal fillings *very probably* do not quite reach the end of the root but we cannot be absolutely certain they do not.

No. 11. The "cork screw" or "buckled" canal filling which does not fill the canal solid full. . . . A very faulty filling.

No. 12. A filling of one gutta-percha point which neither fills the canal full nor reaches the end of the root.

No. 13. A filling of one gutta-percha point which reaches well toward the end of the root but does not fill the canal full. . . . A very faulty filling.

No. 14. A point inserted through a perforation between the roots of a lower molar. We may have little respect for the operator's ability who did this; but he tried, and so we have more respect for him as a man than for the operator with greater ability who doesn't even try.

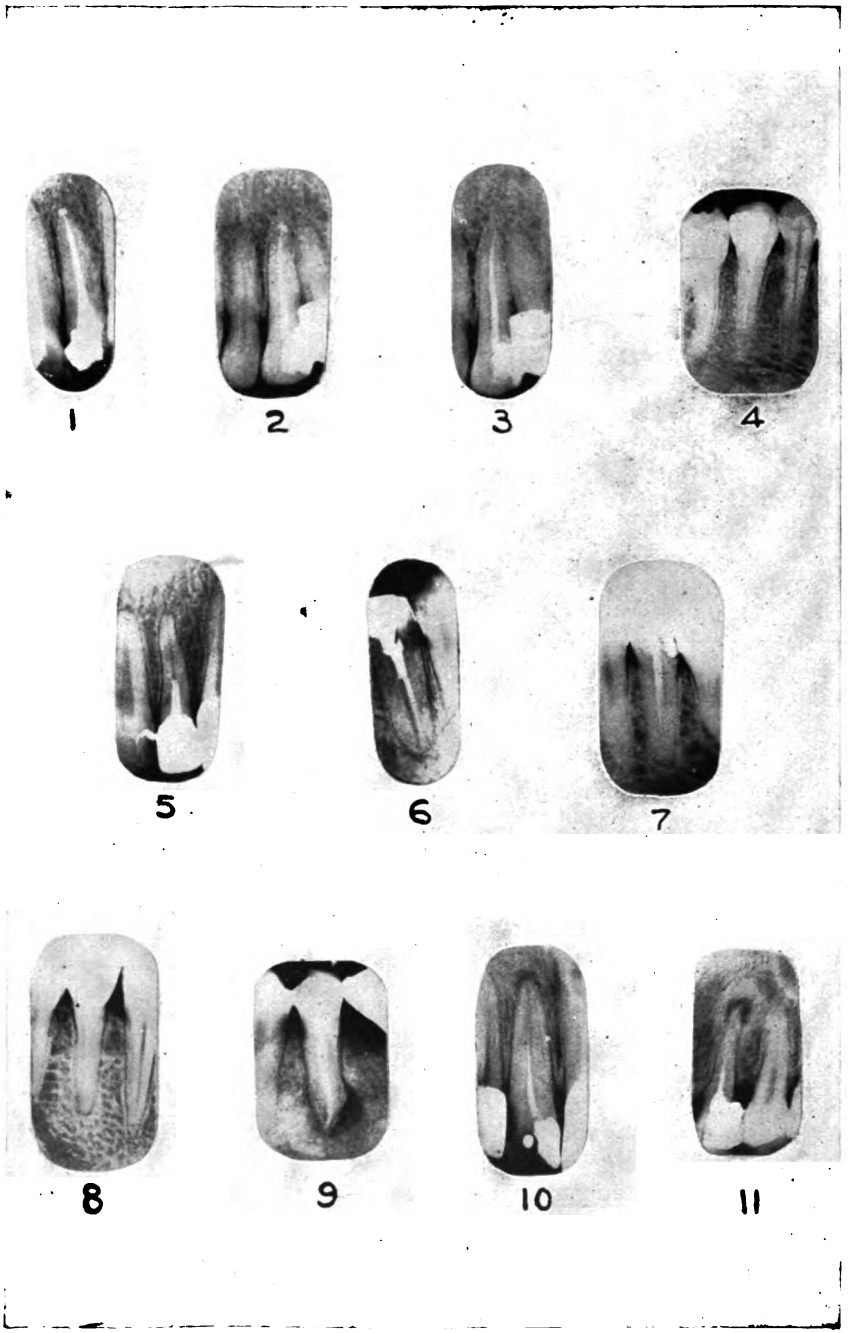

Chart B B

Chart BB

Illustrating different degrees of evidence of infection seen in radiographs

Nos. 1 and 2. No radiographic evidence whatever of infection. The canal fillings are perfect as far as we are able to see and the bone in the apical region has the appearance of healthy bone.

No. 3. No definite evidence of infection. However we cannot be as certain that the canal is filled to the end as in the cases of Nos. 1 and 2, where a little canal filling material passes through the end of the root. There is no evidence of bone change in the periapical tissues.

No. 4. The only evidence of infection is the evidence that the canal filling does not reach the end of the root. There is no periapical bone change.

No. 5. Like No. 4, the evidence of infection is only the evidence that the canal filling does not reach the end of the root. In this case we see also the unfilled part of the canal standing open. Perhaps the lumen of the unfilled part of the canal in No. 4 is very small, but we know it is large in No. 5.

No. 6. Though the canal filling reaches well toward the end of the canal, it does not fill the canal full and is, therefore, a faulty canal filling. The only evidence of infection is the evidence that the canal filling is imperfect.

Nos. 7 and 8. The canal fillings are imperfect and there is evidence of bone change in the apical region. The evidence of bone change—rarefication and sclerosis—is so slight that it would not be looked upon as evidence of infection if it were not for the fact that the teeth are pulpless and the canal fillings faulty.

No. 9. Definite evidence of bone destruction and hypercementosis, both indicative of infection. However, the canal filling seems to be perfect. The history of the case governs my opinion here. The tooth has just been treated; there has been no time for bone reconstruction to occur.

No. 10. The evidence of infection is quite definite; canal filling is faulty and there is destructive bone change in the apical region.

No. 11. Definite evidence of infection, (1) faulty canal filling, (2) bone destruction, (3) osteosclerosis.

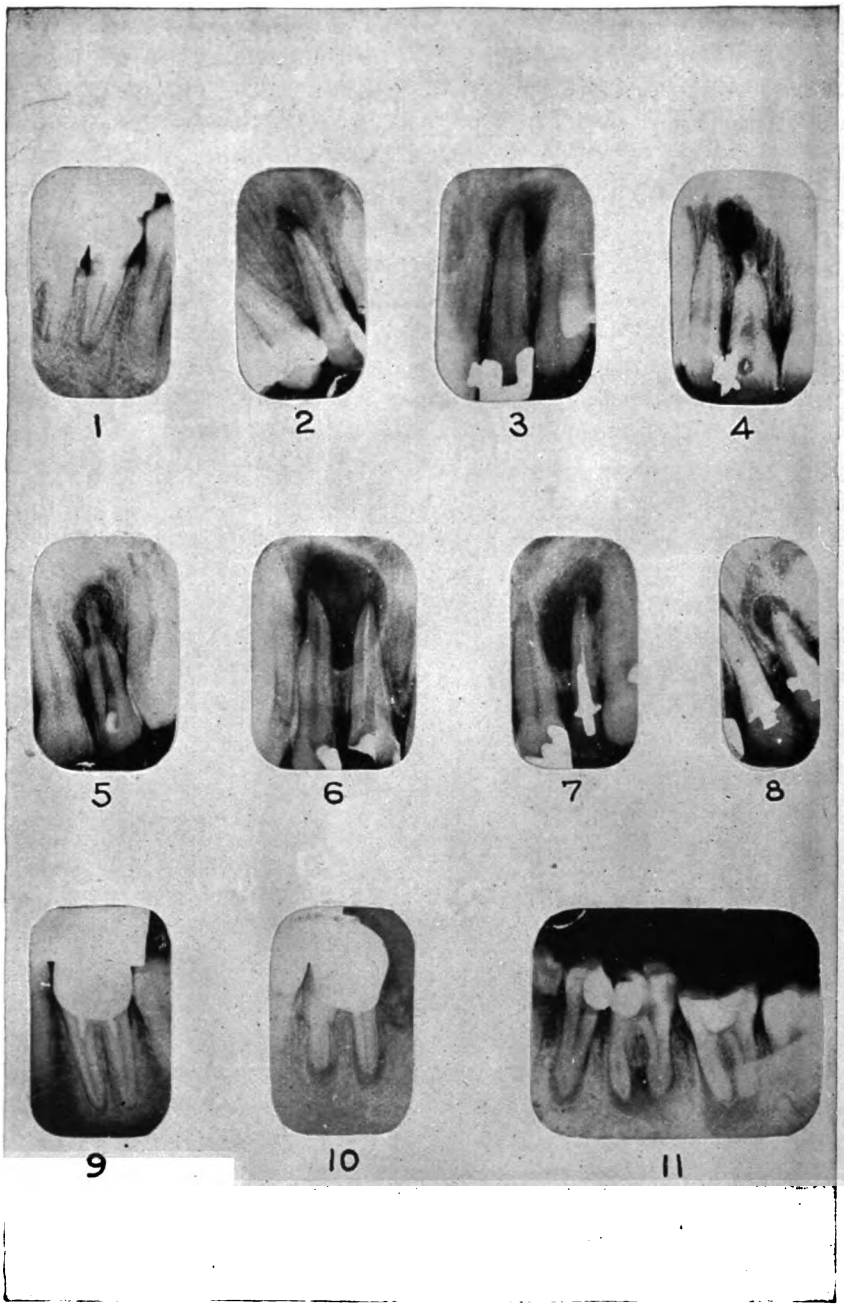

Chart C C

Chart CC

Illustrating how the radiograph helps the operator to determine the nature of the treatment indicated

No. 1. Considering the tooth involved and the slight amount of bone change, treatment through the canals would be the writer's choice.

No. 2. Different operators would disagree as to the treatment indicated. Some would treat through the canals, others would resect and curette. Certainly the resection-curettement operation is a more reliable means of eradicating infection, but I have seen cases like No. 2 yield to treatment through the canals and show a bone reconstruction following such treatment.

No. 3. Compared with No. 2, the resection-curettement operation is becoming more imperative.

No. 4. Root resection is, I believe, definitely indicated here.

Nos. 5 and 6. Treatment through canals contra-indicated. Prognosis for root resection, somewhat doubtful.

Nos. 7 and 8. Prognosis for root resection, very doubtful. Too much bone destruction too far down on the mesial in No. 7, and too much loss of osseous tissue at the cervical in No. 8.

No. 9. Prognosis for treatment through canals good, if the canals can be opened to the end.

No 10. What the writer now considers as about the limit of the extent of bone destruction at the apex of a molar which *may* be treated successfully through the canals.

No. 11. The number of teeth involved often governs the treatment indicated. I should say, arbitrarily, extract the molars; treat the bicuspid.

N. B. In the foregoing the writer has not taken into consideration the physical condition of the patient. In practice this is a most important factor.

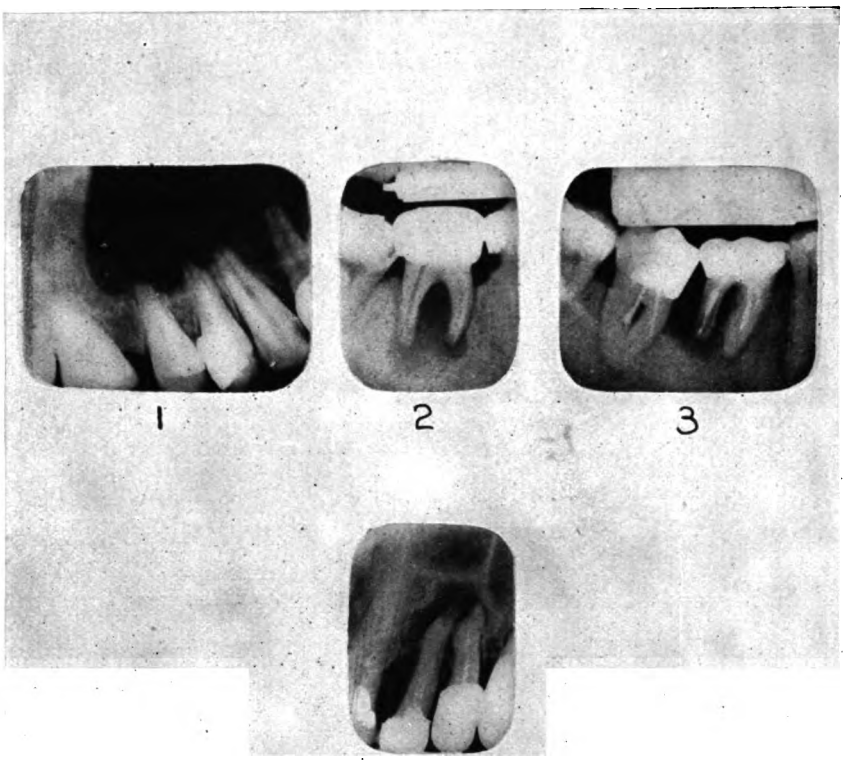

Chart D D

Chart D D

Illustrating a number of different cases where extraction is indicated

No. 1. The abscess is so large—i. e., there is such extensive bone destruction—the case looks as though it might be syphillitic, but is not. Extraction of all the teeth involved was deemed the best procedure.

No. 2. So much bone destruction that treatment of any sort calculated to lead to the retention of the tooth would probably fail to eradicate infection.

No. 3. The bone about the distal root of the first molar is entirely gone; the canal fillings in the mesial root are faulty and probably could not be made perfect. (It is very difficult to open canals of molars to the end when opening the tooth for the first time. When the canals have already been partially filled by a previous operator, the chance of opening such canals to the end is greatly lessened.)

Two perforations with canal filling passing through them in the second molar.

Extraction of both first and second molars indicated.

No. 4. The first bicuspid is hopelessly diseased; the bone destruction at the apex extends down along the sides of the root to the cervical.

No. 5. The extraction of the central incisor is indicated because there is so much destruction of its root that root resection would very probably be unsuccessful.

No. 6. Only by extraction can the abscess, caused by the post passing through the distal side of the second bicuspid, be cured.

No. 7. There were only ten teeth left in this mouth. All of them showed bone destruction at the apex or at the cervical, or at both places (the lateral).

APPENDIX TO CHAPTER VII

Uses of Radiography in Dentistry.

The temptation to submit more radiographs to illustrate the uses of the radiograph in dentistry is intense. I could now illustrate some of the uses with better radiographs than are shown in Chapter VII, but most of the uses are already sufficiently well illustrated to teach the principle of the application of the radiograph, and that is as far as I should go, otherwise there would be no limit to the number of radiographs which might be shown, each having some interesting peculiarity of its own.

In other words, I will not attempt to exhaust the subject for reasons so cleverly set forth in the following excerpt from "Life": "Writers should early learn not to try to exhaust a subject. If there is one thing above another thing that a subject will not stand for it is to be exhausted. It is the one tireless thing extant. In every other way subjects are amiable and tractable. If you go at a subject in the right spirit you can say nearly anything you wish about it, but immediately you try to get a rope around a subject's neck and chase it around a ring until it is absolutely used up, the said subject takes on a dry, dogged, stubborn air and refuses to be interesting, and, of course a writer who cannot keep his subject interesting is lost.

"Think of the most uninteresting books you ever read. They were written by men who quite evidently sat down with the mental resolution: 'Now I'll just clean up on this subject once for all, so that it will henceforth be clear to all posterity, even unto the day of judgment.' But, of course, no such aim was ever realized. The only sure result of trying to exhaust a subject is to prove that it is exhaustless."

The subject of the Uses of the Radiograph in Dentistry is certainly exhaustless; so I shall be satisfied to treat the subject in this appendix as concisely as possible.

Oral Foci of Infection.

Perhaps the most extensive use of the radiograph in the practice of dentistry today is as a means of examining the mouth for infection in cases of bacteremia, arthritis, neuritis, endocarditis, gastric ulcer, appendicitis, enteritis, dermatitis, cholecystitis, nephritis and other constitutional diseases; also in cases of diseases of the eye, ear, nose and throat, which we now believe may be caused by some focus of infection. For this purpose the use of the radiograph is absolutely indispensable.

The practice of simply making ten film radiographic negatives and

then calling it a complete examination of the mouth is a much abused one. Usually it is impossible to obtain good radiographs of *all* of the teeth on ten negatives, and often it is not absolutely necessary to make radiographs of *all* of the teeth. (It is sometimes more necessary to ray all the teeth in other classes of cases, such as obscure neuralgias, for example, than it is when the examination is made in a search for infection.)

It has been said that, in many cases where a search is being made for oral infection, it is "*entirely unnecessary*" to radiograph all of the teeth. I cannot agree that it is "entirely unnecessary," though it is very often *largely unnecessary*. A radiodontist of keen judgment may eliminate certain parts of mouths from the radiodontic examination and not make a mistake by so doing once in fifty cases, but the fact that it is possible that he may make a mistake at all should keep us from condemning the practice of radiographing all teeth as "*entirely unnecessary.*"

To make an examination of the mouth to determine whether or not the teeth and jaws are a source of infection, the use of the radiograph is only a part—true, the most important part but, nevertheless, only a part—of the examination.

Careful ocular, instrumental and digital examination should be made. Then the teeth should be tested for pulp vitality with the electric test and records made of the result of these tests. Now radiograph, *at least,* the following regions: (1) Regions from which teeth are missing, to locate pieces of roots or unerupted teeth. (2) Teeth which do not respond to the electric test and teeth which cannot be satisfactorily tested with the electric test. (This always includes crowned teeth.) (3) Teeth affected with pyorrhea, to observe the extent of the loss of osseous tissue. (4) Any region of tenderness, localized pain or abnormal appearance.

An area of infection frequently overlooked is illustrated in Fig. 457. In a case such as Fig. 457, pus can often be pressed into view with the finger, pressing with the index finger from below upward on the lingual and just to the distal of the third molar. Because there is less distortion, lesions like the one illustrated in Fig. 457 can be seen to better advantage in extra-oral radiographs than in the intra-oral ones.

Dr. Eisen makes it his practice to radiograph both sides of the mouth on plates first, then re-ray on a film any suspicious areas found in the plate if necessary to get a better view. This practice is certainly to be commended.

Impacted Teeth.

I have made the statement repeatedly that an impacted tooth may cause no trouble at all or it may produce the most disastrous results. Allow me to illustrate this: Figure 458A and 458B show two impacted upper cuspids

in the same mouth. One (Fig. 458A) shows no evidence of pathologic condition of the surrounding tissues while the other (Fig. 458B) shows a great deal of bone destruction, due to suppuration. However, an un-

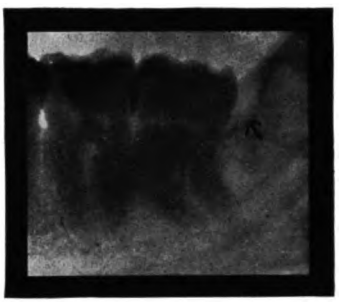

Fig. 457. The arrow points to a V-shaped area, indicating bone destruction back of a lower third molar. (Eisen and Ivy.)

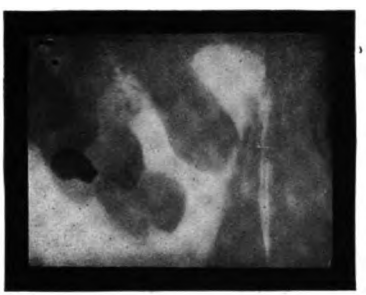

Fig. 458A and 458B. Unerupted cuspids, both in the same mouth, one causing much bone destruction, the other none.

erupted tooth must be looked upon always as a source of possible suppuration, even when the radiograph shows no destruction of bone.

Unerupted Cuspid Made to Erupt.

Fig. 459a.

Figure 459 is the same case illustrated in Figures 150, 151 and 152 with the cuspid in its proper place.

Never having seen the case illustrated in Fig. 207, the writer certainly is not in a position to take issue with Dr. Rhein, who treated the case, and Dr. Ottolengui, who wrote the history of the case on pages 195 and 196. However, I may say simply this; the shadow over the cuspid illustrated in Fig. 207 has, to me, the radiographic appearance of being the antrum. Figure 459A is a case having a similar appearance to Fig. 207. In Fig 459A I feel quite certain that the shadow over the cuspid is the antrum.

Root Resection Cases. I can perhaps impress you with the value of making radiographs before operating to excise root ends by relating this experience. Dr. Carl D. Lucas, who was to give a clinic on apical excision before the Indianapolis Dental Society, asked that a patient be selected for him from the Indiana Dental College clinic. The demonstrators in the college clinic were advised of this and asked to select a suitable case and send it to me for a radiographic examination. Thus, the cases which came to me were those in

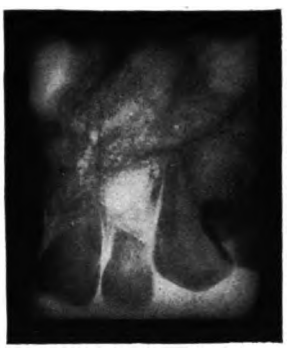

Fig. 459. The same case illustrated in Figs. 150, 151 and 152, after eruption of the cuspid. (Radiograph by Kells.)

Fig. 459A. The shadow of the antrum over the cuspid gives the cuspid somewhat the appearance of being abscessed.

which the symptoms were such as to indicate apical excision. Apical excision was seen to be contra-indicated, however, in the first case, when the radiograph showed the root of the tooth to be abnormally short; in the second case, when the radiograph disclosed the presence of a perforation; and in the third case in which the destruction of bone was too extensive. In the fourth case, the radiographic finding, indicated apical excision, thus finally substantiating the conclusions based on a knowledge of symptoms. In the light of this unusual but instructive experience I would insist that the operator should always make a radiographic examination before operating to excise a root end.

Facial Fistula Cases. Figure 460 shows a malposed, unerupted, partially formed upper second bicuspid. In this case the pus discharged just beneath the eye. Removal of the malposed bicuspid effected a cure. Figure 461 is a photograph of the case one month after operation. (Operators, Drs. Page and Cofield.)

The use of radiographs in cases of fistulas pointing on the face is attended almost always with the most gratifying results. While the radiograph will usually show some bone involvement in these cases it should be remembered, however, that infection of the soft parts surrounding

a lower third molar may result in the formation of a fistula on the face with practically no bone involvement at all. Neither should one lose sight

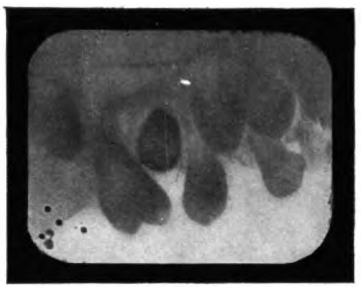

Fig. 460. Malposed, unerupted, partially formed upper second bicuspid. Photograph of case, Fig. 461.

Fig. 461. Post operative photograph of facial fistula case. Scar under eye. See Fig. 460.

of the fact that an ordinary skin abscess—i.e., a boil—may have a clinical appearance somewhat similar to an abscess of dental origin.

Hidden Dental Caries. Figs. 462, 463 and 464

I have been surprised to find radiographs of such value in locating hidden carious cavities in teeth.

Figure 462 is a case in which the patient was suffering considerably. The pain seemed to be localized in either the second bicuspid or the first molar. The radiograph shows nothing wrong with the second bicuspid, an abscess at the mesio-buccal root of the first molar and, most important of all from the standpoint of relieving pain, a carious cavity in the distal of the second molar. The cavity was entirely covered with gum tissue. When access was gained to it, it was found that the pulp was exposed. A sedative treatment was applied and pain was relieved immediately.

Figure 463 shows caries at the cervical margins of the fillings in the distal of both the first and second molars. Such cavities as these are very seldom found at all unless located radiographically. (In this particular case, Figure 463, both of the molars are abscessed.)

The history of Figure 464 is rather long but quite interesting. A man of middle age, multimillionaire, awoke one morning with the tooth-

ache. Straightway he visited a dentist, who examined his mouth, told him there was nothing the matter with his teeth and that he had neuralgia. The patient, still believing he had toothache, visited another dentist who examined his mouth and told him in substance the same thing. And the patient who still believed he had the toothache visited a third dentist who,

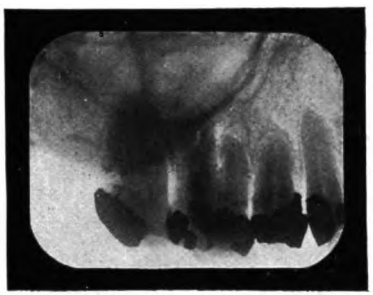

Fig. 462. Gum-covered carious cavity in distal of upper second molar.

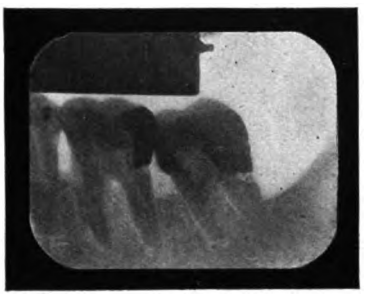

Fig. 463. Fillings failing at the cervical margin.

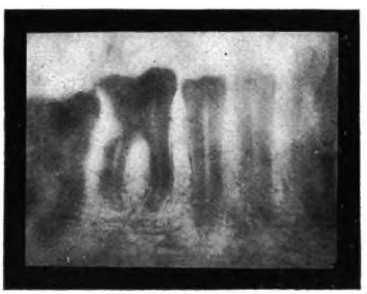

Fig. 464. Hidden carious cavity in distal of lower first molar.

like the others, examined his teeth and told him his teeth needed no treatment. In despair, since his dentists had failed him, the man next visited a bar-tender and then another bar-tender, and another, and another, until his friends took him to the hospital that he might recover from delirium tremens. In due time he recovered from his delirium and as soon as he did, he complained of the toothache. A dentist was called in. He examined the mouth and found nothing wrong with the teeth. It happens, however, that this particular dentist is a radiodontist of no mean ability, and, so he asked to be permitted to make a radiograph of the region where the pain seemed to be located. This was granted promptly—though at the time all this occurred very few radiographs of teeth were being made —for the physicians in charge of the case were helpless.

Figure 464 was made and shows a carious cavity in the distal of a lower first molar! The case was simply one of pulpitis! There are doubt-

less those who will say that the cavity should have been discovered without the aid of the radiograph, by instrumentation. Perhaps, but, the fact remains, it was not. And so impressed were the medical men with

Fig. 465. Slight destruction of osseous tissue in apical region of lower first molar following use of arsenic.

Fig. 466. Case in which the patient suffered from attacks of sneezing.

the dentist who finally made a diagnosis and cured the patient, they put him on the hospital staff, a member in full standing; a thing that had never happened to a dentist in that city before.

The Effect of Arsenic. Figure 465 illustrates a slight bone destruction at the apices of the roots of a lower first molar immediately following devitalization of the pulp with arsenic. However, I cannot state definitely that the slight bone destruction is not due to infection, for I do not know in detail the conditions under which the work was done.

Very Unusual Case. Symptoms: Periodic sneezing attacks. The radiograph (Figure 466) shows an abscess of an upper central incisor, communicating with an abscess sinus in the apical region of the extracted lateral. Up to the present time, I have been unable to hear from the case since the radiographic examination, but I feel quite certain the condition of the teeth *could* be responsible for the sneezing attacks.

Pieces of Tooth Root. It used to be the writer's opinion that a piece of root would always "work" to the surface of the gum in time. Radiographic experience is teaching me, however, that not infrequently the gum heals over tooth roots and they remain in the jaws for years without appearing at the surface of the gum tissue. Such roots are usually a source of irritation and infection, though not always.

APPENDIX TO CHAPTER VIII

The Danger of the X-Rays.

The following factors must be considered when determining the dose of the X-rays: (1) The time of exposure. (2) The milliamperage passing through the tube. (3) The distance between target and skin. (4) The action of a filter. (5) The quality of the X-rays. (6) The temperature of the X-ray tube. (7) The kind and working condition of the X-ray machine. (8) The sensitivity of the skin exposed.

It will be seen from the foregoing that the problem of administering exact doses of the X-rays is one fraught with great difficulties. It is the writer's opinion that general practitioners of dentistry and medicine should not use the X-rays for therapeutic purposes unless they are willing to give the matter the great amount of study necessary to enable them to administer definite doses.

It is the writer's further opinion that both the general practitioner of dentistry and medicine *may* find it to their advantage to use the X-rays for radiographic purposes. When using the X-rays for radiographic purposes it is not necessary that the operator know all there is to be known about dosage. He should, however, know enough so he will not expose his patients to the point of producing dermatitis.

It is with the idea of imparting only such knowledge as will enable men to practice radiodontia without danger of producing X-ray dermatitis that we take up a consideration of X-ray dosage. Only the most important and most variable factors governing dosage will be considered.

Time of Exposure and Milliamperage. The effect of the X-rays on the skin varies directly according to the length of time of exposure; thus, other things remaining the same, the effect is twice as great if the exposure is two seconds as it would be if the exposure were for one second.

The effect of the X-rays on the skin also varies directly according to the number of milliamperes passing through the tube; for example, other things remaining the same, 10 milliamperes produce twice the effect produced by 5 milliamperes.

To obtain the same effect on the skin as the time is lessened the milliamperage must be increased, or as the milliamperage is lessened the time must be increased. For example, 10 milliamperes for 6 seconds will have practically the same effect as 6 milliamperes for 10 seconds. In other words, the milliampere-second dose is the same, i.e., 60 milliampere-

seconds. The milliampere-second unit is obtained, recall, by multiplying the number of milliamperes passing through the tube by the number of seconds exposure.

Though it would not do for the X-ray therapeutist, the milliampere-second is perhaps the best unit of measurement of X-ray dosage for the radiographer.

Distance Between Target and Skin.

The effect of the X-rays on the skin varies inversely with the square of the distance or, to state the same thing differently, in order to obtain the same effect on the skin the size of the milliampere-second dose varies directly with the square of the distance. To elucidate: The dose necessary to produce erythemia of the skin of the face with the skin-target distance 8 inches, is about 1200 milliampere-seconds. With the skin-target distance increased to 16 inches the erythemia dose is about 4800 milliampere-seconds. This conclusion is reached as follows: the square of 8 is 64, the square of 16 is 256, 256 is four times as much as 64. Therefore, the dose at 16 inches is four times as much as at 8 inches, for the dose necessary to produce the same effect varies directly with the square of the distance.

The Filter.

The use of a filter of one millimeter of aluminum necessitates doubling the dose to get the same skin effect.

Limit of Exposure of Patients.

We are now ready to consider a limit of the dose of X-rays to be given to radiodontic patients. I would suggest that operators never exceed one-half the erythemia dose.

Suppose now, for example, that the distance between the target and the skin is 16 inches—which is, however, probably greater than the average distance for radiodontic work—and no filter is used; do not exceed what I shall call the safe dose of 2400 milliampere-seconds (4800 milliampere-seconds is the erythemia dose, recall).

If the distance is only about 8 inches between target and skin—which perhaps is a little nearer the average distance for radiodontic work as practiced—then do not exceed the safe dose of 600 milliampere-seconds, unless a filter of one millimeter of aluminum is used, when the dose may be doubled, that is made 1200 milliampere-seconds.

If a full *safe dose* is given wait two weeks or a month before making any further exposure and so guard against a cumulative effect.

Making radiographs of one side of the mouth has, of course, very little effect on the skin of the other side of the face.

Suppose now we take a case from practice and see how a man would figure his dosage. He makes measurements and finds the distance from target to skin to be 12 inches. The safe dose at 8 inches is 600 milliampere-seconds. Apply the rule now that the dose may be increased directly with the square of the distance. The square of 12 is 144, the square of 8 is 64; 144 is 2¼ times as much as 64. Two and one-fourth times 600 milliampere-seconds equals 1350 milliampere-seconds.

Small X-Ray Machines.

Without going into a detailed description of "the why and the wherefore" of the fact, it may simply be stated that it requires a greater skin-dose of X-rays to make a radiograph with a very small X-ray machine than it does with a medium or large machine. Hence the number of radiographs which can be made with safety varies somewhat with the size of the X-ray machine. With the smaller machines fewer radiographs can be made without exceeding the safe dose.

Men with small machines should be particularly careful, or they will exceed the safe dose and may produce dermatitis. Likewise men who employ the "soft tube technic" must remember that the low vacuum of the tube necessitates a greater millianpere-second exposure. Dr. Geo. M. MacKee* reports having seen, "in sixteen months, eight cases of radiodermatitis," i.e., X-ray burn, which were produced incident to radiographic examination of the teeth.

Dentists must equip themselves with the right kind of machine, and they must know how and must keep tab on their dosage if they expect to do much radiographic work. It is dangerous to attempt to examine all the teeth in a mouth with a small X-ray machine, then follow this with re-examinations as canal work is being done, unless the operator keeps careful track of the dose he is giving and stops when he reaches the safe dose limit.

Many dentists who are doing all of their own X-ray work should either get bigger machines and use them more intelligently or they should refer most of their work to specialists and do only the simpler, easier work themselves.

Influence of Fees on Danger.

As long as the fee for dental radiographs remained high the probability of excessive dosage due to the making of many radiographs was not great. But, as more of the work is being done, the fee is getting so low in many localities that it no longer offers the protection it once afforded.

* Dental Cosmos, May, 1916

but becomes instead the chief factor in the development of careless, dangerous practices.

The Electric Test for Pulp Vitality.

As stated in Chapter VIII the first rule regarding the exposure of patients is not to expose them any longer than necessary. Conscientious and consistent use of the electric test for pulp vitality will cut down the number of radiographic exposures necessary, especially in cases where the entire mouth is to be examined in a search for infection, and it should therefore be used.

Carelessness and Ignorance.

In the past the writer has been a conscientious advocate of the belief that the dentist should do at least a part of his own radiographic work. But, as dentists commence to take up the work now, I am appalled at the degree of ignorance and carelessness displayed. Unless I can see some evidence of study of the subject before long, I shall be forced to conclude that radiodontic work should be done only by a few men who have the ambition to do it as it should be done.

I feel safe in predicting that, unless intelligence is soon displayed by dentists, a wave of disaster from X-ray lesions will sweep the country, leaving more victims than was claimed by the X-rays directly after they were discovered. These victims will be both dentists and dentists' patients, to the best of my ability to judge, mostly the former, for most dentists seem to fail utterly to appreciate the necessity of protecting themselves.

It was learned from disastrous experience that the operator should have protection. Protection was accordingly given and because this protection has proved effective the tendency among even the best X-ray men seems to be to dispense with as much of it as possible. This tendency carried too far will result in disaster. There is every reason in the world why the operator should have protection and practically no reason, unless inertia may be considered a reason, why he should not. I earnestly advise the use of the lead screen or cabinet by all operators.

Some men make it a practice to hold the film in the patient's mouth during its exposure. This is positively unnecessary and, if the practice is continued, is certain to result in injury to the operator.

Other operators have their assistant hold the film in the patient's mouth during exposure. This is worse than for the operator to hold it, for it is less fair and less humane, and also it may prove to be very expensive in case the assistant receives a burn and brings suit under the "employer's liability and compensation law" such as we have in many different States.

As I have said elsewhere, *properly handled the X-rays are harmless.*

so harmless that the tendency is to cease handling them properly when they may become woefully harmful.

Points About Protection of Operator.

Since the effect of the X-rays varies inversely with the square of the distance it is quite apparent that it is advantageous, as a means of protection, for the operator to be as far away as possible from the tube while it is in operation. A foot switch (Fig. 467) or any other form of extension control



Fig. 467. A foot-switch by means of which the operator may stand any desired distance from the X-ray machine and tube when the current is turned on.

leading from the machine may be used to enable the operator to increase the distance between himself and the tube. It is common and good practice to have the X-ray machine controls mounted on a stand back of the screen or on the back of the lead screen (Fig. 468). Wires lead from the X-ray machine to the screen, which wires may be made of any desired length and so the operator may stand as far away from his tube and machine as the size of his room will permit. Also the controls may be mounted on the X-ray machines and, by means of an overhead wiring system (Fig. 361), the tube removed any desired distance from the machine.

The operator should not only make it a rule to stand as far away from the tube as possible while it is in operation, but he should always see to it that the active hemisphere of the tube presents *away* from him, and incidentally I may say also away from his supplies of films and plates.

Figure 83 shows a protection cover for the top of lead glass bowls.

Alopecia.

I wish to modify the remarks on page 278 referring to the possibility of baldness being produced in operators due to the continuous small dose of X-rays they unavoidably take.

Recent experiences and observations lead me to believe that X-ray operators not infrequently lose hair due to the action of the X-rays.

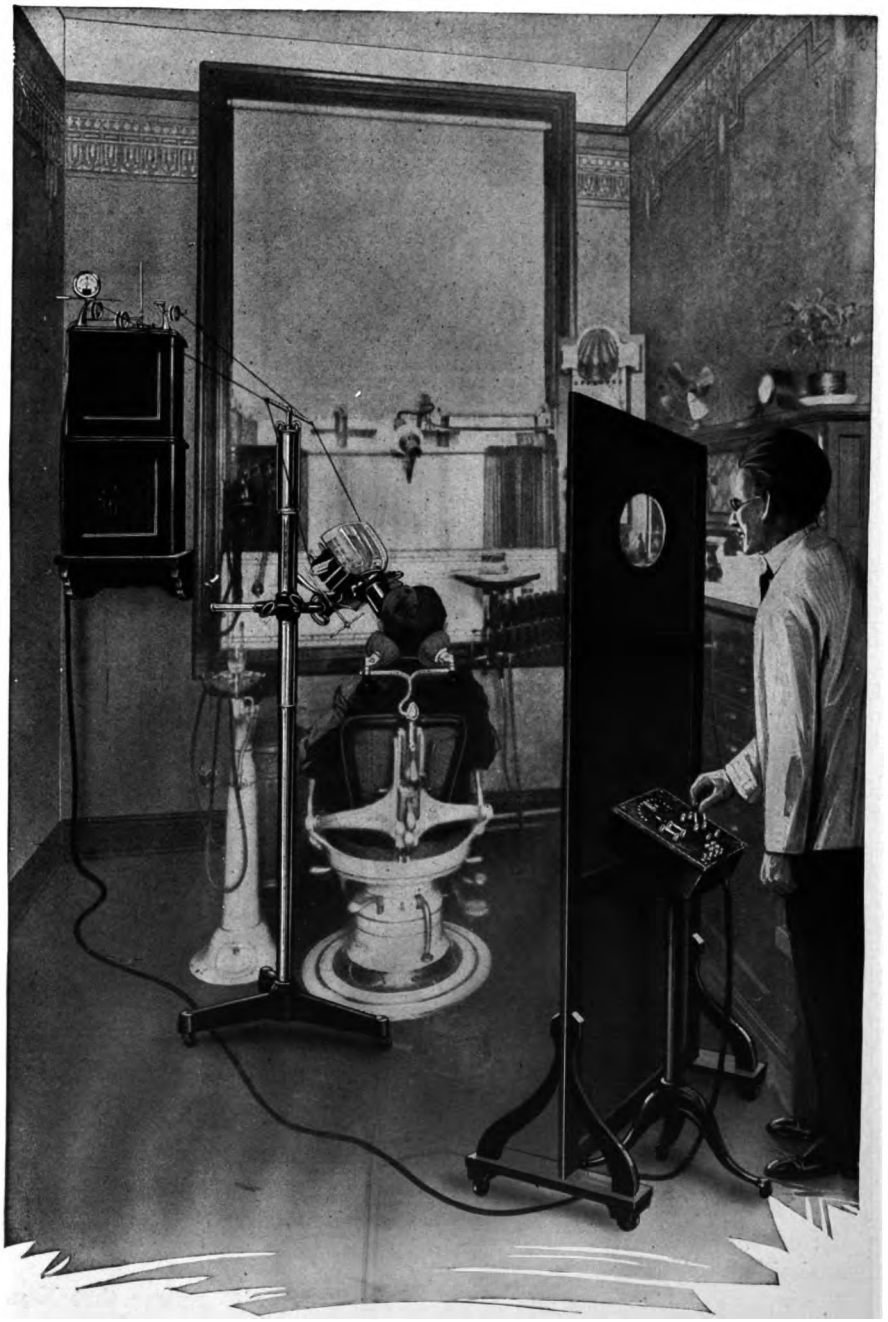

Fig. 468. A movable pedestal with "controls" mounted on it.

Figure 469A shows alopecia in a patient following radiographic examination of the frontal sinuses and antra. Figure 469B is the same case about three months later showing a new growth of hair.

I know so little of the history of this case I shall not attempt to give it further than to say that there was never any dermatitis.

I shall instead give the history of a similar case encountered in my own practice; of which unfortunately I do not have photographs. Patient:

Fig. 469A. Case of alopecia produced in effort to make antero-posterior radiograph of the antra.

Fig. 469B. Same as Fig. 469A about three months later, showing new growth of hair.

Male, age 30. Blonde, fine, thin hair. Repeated exposure for frontal sinus examination netting a dose of about 900 milliampere-seconds in three days, distance between target and skin about 9 inches, no filter used. About one month after exposure the hair commenced to come out of the region of the head exposed, continuing to come out for about two months, at the end of which time the head was quite bald. Almost immediately then the hair commenced to come in again and conditions were normal once more at the end of about two more months. There was never any dermatitis.

I have received several similar histories from various men. In one case the hair commenced to fall out 3 days after exposure and the patient was bald in about 10 days, but in this case, as well as all others, it came back.

The tendency is to say that " the hair comes back thicker than ever," but this is hardly the case. However, the hair does come back as thick as ever.

This accident of producing alopecia for a young lady patient would be extremely distressing to both patient and operator. I advise the use

of a filter of 1 millimeter of aluminum or a piece of sole leather for antrum and frontal sinus cases to guard against such an accident.

Danger of Electric Current.

Let us compare the currents of X-ray machines to the current used for electrocution and so get some idea of the danger of the former. For electrocution at the Ohio State Penitentiary the current used is 60 cycle A. C., voltage 1700 to 2500, amperage 4 to 6 for one minute.

It will be seen from this that the current of X-ray machines is never very similar to the electrocution current. The current of the primary is higher in amperage but much less in voltage; the current of the secondary is higher in voltage but much lower in amperage.

Of course one should avoid coming in contact with the wires of either the primary or secondary of any X-ray machine, for the shock may be either painful or possibly even result in injury. The sensation when receiving a considerable quantity of electricty is that of a "jolt." The "jolt" or blow may knock the victim down, and so this usually breaks the circuit, but if it should knock the unfortunate one onto, instead of off of, the "live" wire, the injury might be great.

There is very little danger of receiving a shock from the primary circuit, but both the operator and the patient sometimes inadvertently come in contact with or in too close proximity to a secondary terminal. Contact with a secondary terminal means anything from an unpleasant experience to a disastrous one, depending largely on the size of the machine. When one gets very close to—within one or two inches—but does not come in contact, with a secondary terminal a spark may jump from the terminal. This is of course unpleasant and may cause inflammation of the skin at the point of entrance of the spark. See Fig 102, which illustrates how the patient may be protected when it is necessary to bring a terminal close to the body.

APPENDIX TO CHAPTER X

Stereoscopic Radiography.

Some improvement in dental stereoradiographs has been made in the past five years but the full possibilities of this process have not yet been developed.

The idea of enlarging dental stereoradiographs was given in Chapter X, Figs. 350 and 354. In pursuance of this same idea it is the writer's practice, in some cases, to enlarge stereoradiographs as in Fig. 470. The enlargement is made on a plate—not paper—and observation of the stereoradiographs is made with a stereoscope like the one illustrated in Fig. 323. The result is sometimes very gratifying. In the case of Fig. 470, for example, it enabled me to state *definitely* that the unerupted cuspid lay to the labial of the lateral incisor root, a fact which I had failed to determine, to my complete satisfaction, by ocular and digital examination of the mouth, observation of single radiographs, and observation of unenlarged, stereoradiographs.

This method is too new for me to hazard an opinion of its value, but I can say conservatively that it seems to hold the greatest possibilities of any method thus far tried by me.

Technic. The technic outlined in Chapter X, that which is applicable to all stereoscopic work, is followed. The film-holder, Figs. 331, 332 and 333, is used, if possible, to insure placing the film packets in the mouth in the same position for the two exposures. If the film-holder cannot be used simply place the two film packets in the same position to the best of your ability to do it, having the patient hold the film with the thumb or finger, or place the film in the mouth as in Figs. 96 and 103. (See text on page 311.)

Hold the head immovable by using a device similar to Fig. 110 or with the patient in a sitting posture by bandaging the head to the head rest.

Marking Negatives. Make the two exposures, shifting the tube as directed in Chapter X. While in the dark room, before proceeding with development mark the films right (R), and left (L), the operator imagining himself in the position of the tube at the time of exposure and that one exposure has been made for the right eye and the other for the left eye. Films may be marked for identification by placing a small " R " and " L " in the corner, making the mark with a lead pencil (this mark can be seen after the negative is made) or by punching small holes in the corner of the film with a plate punch, making one hole for the right, two holes for the left.

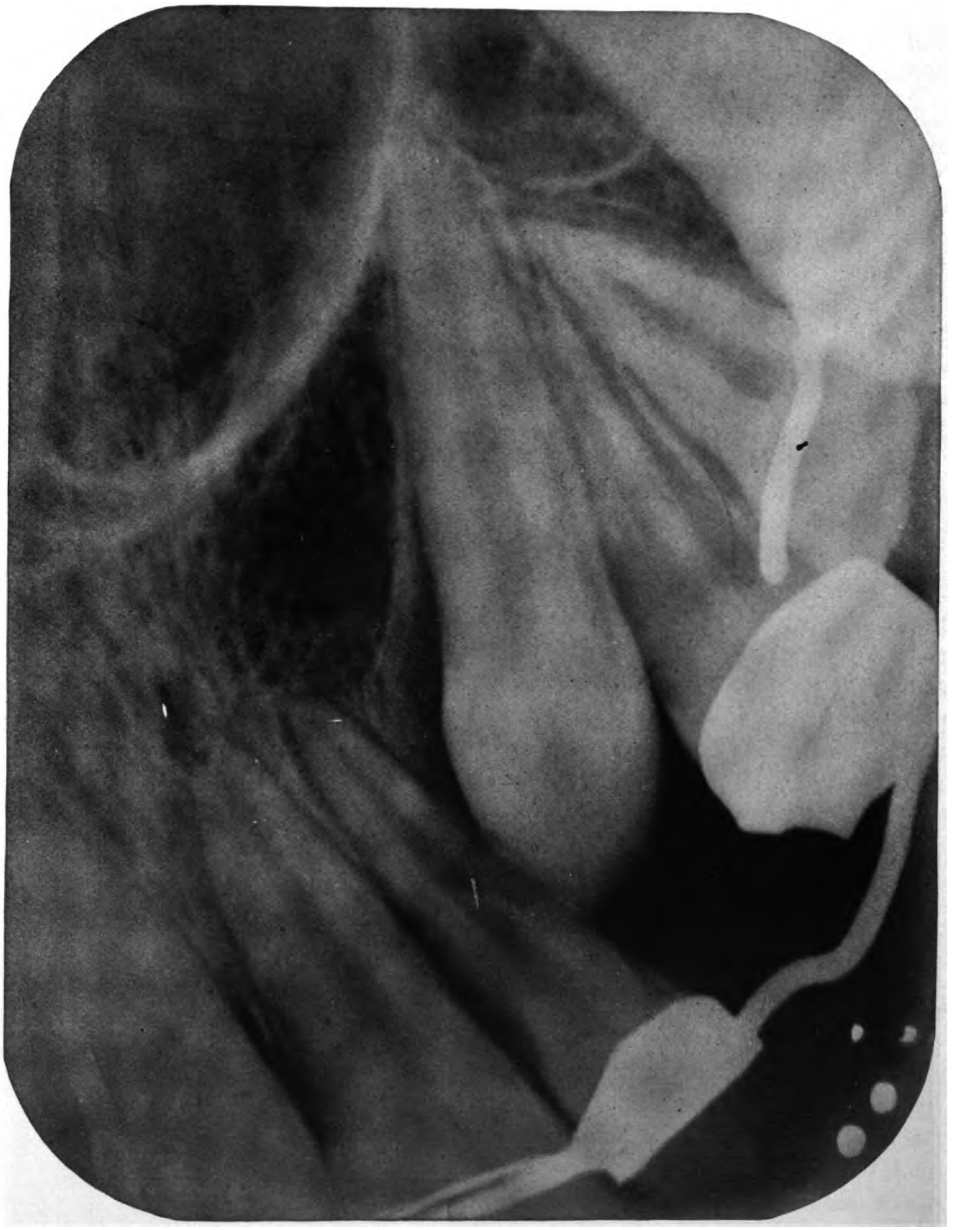

Fig. 470. Dental radiograph enlarged for observation in large stereoscope.

Enlargement. The next step is enlargement. This the operator may have done for him by any photographer or he may do it himself, using the usual photographic enlarging apparatus, which consists of a light back of the negative, from which the enlargement is to be made, shining through the negative and an enlarging lens onto a standard which holds the photographic plate or paper (in this case a plate) on which the enlargement is to be made. (See Figs. 471 and 472.) The negative to be enlarged is placed with the coated side away from the source of light. Enlarge to the size of Fig. 470 or larger.



Fig. 471. Enlarging apparatus.

Observation of Enlarged Stereoradiographs. Observe enlargements by means of a stereoscope like Fig. 323. By placing the enlargement from the right negative on the right side of the stereoscope, the left enlargement on the left side, with the coated sides of the plates toward the light of the illuminating boxes, the operator makes his observation from the position of the film at the time of exposure. By reversing the negatives as they are placed on the stereoscope—i. e., by placing the right enlargement on the left side of the stereoscope and the left enlargement on the right side of the stereoscope, with the coated sides of the negatives still toward the light of the illuminating boxes, or by reversing the negatives so their sensitive sides present away from the light of the illuminating boxes toward the operator's position of observation but allowing the right negative to remain on the right side and the left on the left side—the position from which the operator makes his ob-

servation is changed from that of the film during exposure to the position of the X-ray tube during exposure.

The foregoing statements regarding the mounting of negatives on the stereoscope for observation, and the possibilities of changing the operator's position of observation thereby are difficult to follow. I would, therefore, advise those who wish to take up this work to make test or experimental cases by stereoscopically radiographing the hand with a coin



Fig. 472. Enlarging apparatus.

on it, carrying the hand radiographs through the process of enlargement, and then observing them in different ways in the stereoscope.

Application of These Methods to Dentistry.

As I have stated elsewhere stereoscopic work, because of its difficulty will remain principally in the hands of specialists. The practice of making enlargements renders dental stereoscopic radiography a definite success in cases where heretofore it has been a failure. Stereoscopic work remains too expensive to come into general use, but for those who can afford it the service is worth the fee which must be charged for it.

I have heard the statement made repeatedly that the two negatives which are exposed simultaneously in the same film packet can be mounted and observed with a stereoscope, and that a stereoscopic effect is obtained. I may be compelled to change my mind sometime but right now I may

say I don't believe it. At least *I* cannot observe the parts perspectively with such negatives and I am inclined to think that the imagination of the

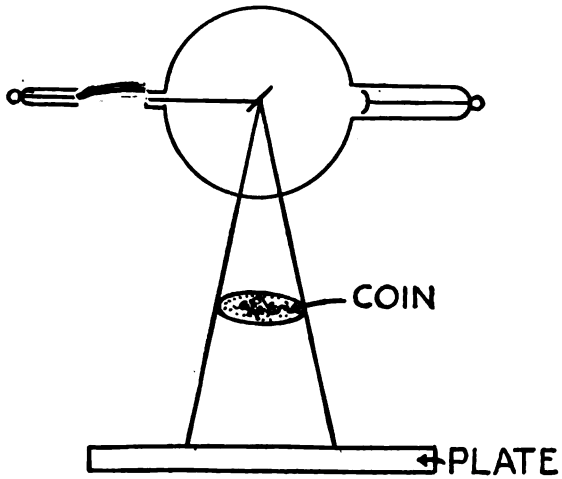

Fig. 473. Drawing which shows how the size of the object being radiographed may be increased by moving it away from the photographic plate toward the X-ray tube.

Fig. 474. The Ketcham stereoscopic film-holder.

operator is responsible for any stereoscopic effect obtained from such negatives.

It will be noticed in Fig. 351 that the coins shown are of slightly different sizes; they are, however, all of the same denomination and so the same size. The reason for the apparent difference in size is illustrated diagrammatically in Fig. 473; as the coin is moved away from the plate toward the target the shadow of it cast on the plate gets larger. Fig. 474 illustrates the Ketcham film-holder for stereoscopic work. The face is marked so the holder may be removed and re-inserted in the same position.

CHAPTER XI

The Problem of Pulp Canal Surgery and Oral Infection.

Bad Canal Work.

Before we can proceed with a consideration of the problem of pulp canal work, we must agree that there is such a thing as "bad canal work"—i. e., canal work which fails to eradicate, or prevent, the formation of local foci of infection at the apices of the roots of the teeth. In fact, most canal work is of this kind. I state this dispassionately as a fact, not with the spirit of reprimand and, I would have you know, I do not believe "the canal work of the dental profession is a disgrace." It may be a mistake but it is not a disgrace. Muriel Strode says, "It is no disgrace to wear rags; the disgrace lies in continuing to wear them." Likewise, it is no disgrace to make a mistake; the disgrace lies in continuing to make the same mistake.

Failure to Fill Canals of Single-Rooted Teeth.

If there is any one who still believes that it has been the practice of dentists, in the past, to fill canals, even large canals, to the end of the root, look at Fig. 475. The radiographs shown in this illustration were obtained by giving an office assistant in a radiodontist's office these instructions: "Go through the H's in the little file of old negatives and select all the cases showing canal fillings in any teeth except molars."

Figure 475 shows forty-eight teeth (none of them molars) in which there has been an effort made to fill the canals. Forty-seven are failures so far as success in reaching the end of the roots is concerned and most of them show evidence of osseous infection at the apices. One, an upper first bicuspid, filled recently under the writer's directions, shows the canal fillings encapsulating the ends of the roots, and so we shall call this a success from a mechanical standpoint at least.

Radiographs Necessary to Fill Canals of Teeth.

It is a fact then that it has not been the practice of dentists to fill the canals even of anterior teeth and biscupids. We need not consider the question of whether or not it is possible to "fill the canals of all molars to the ends of the roots" just now. Let us stick to the problem of filling the larger canals of teeth other than molars. No one will deny the

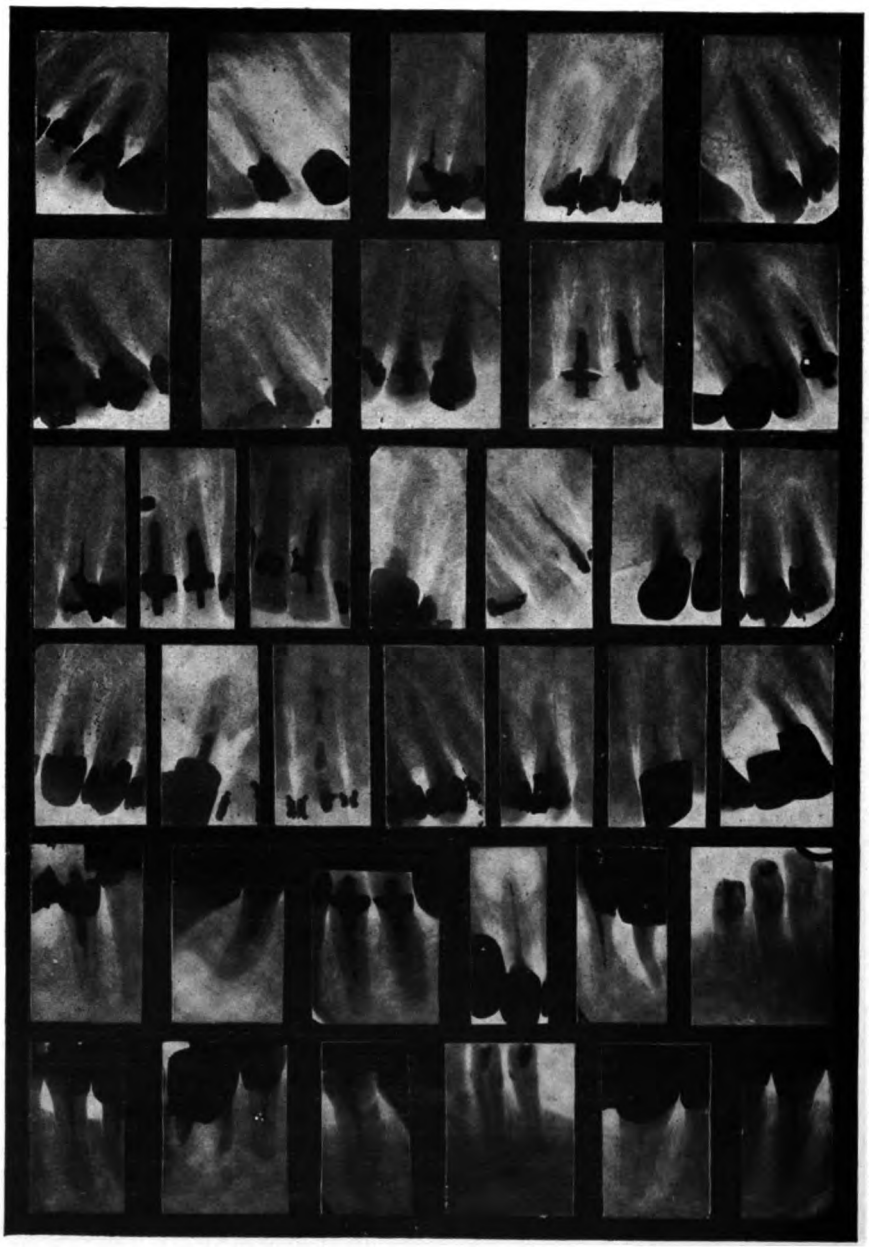

Fig. 475. Forty-eight teeth, other than molars, where efforts have been made to fill canals. The canal filling material fails to reach the end of the root in forty-seven out of the forty-eight. These teeth were selected at random.

physical possibility of filling the canals of the teeth referred to above—except in a very few anomalous cases—and no one who has observed a considerable number of radiographs, will deny the fact that it has not been done, and no one, who has commenced to " check up " his root canal fillings with radiographs, will deny the additional fact that the canals of

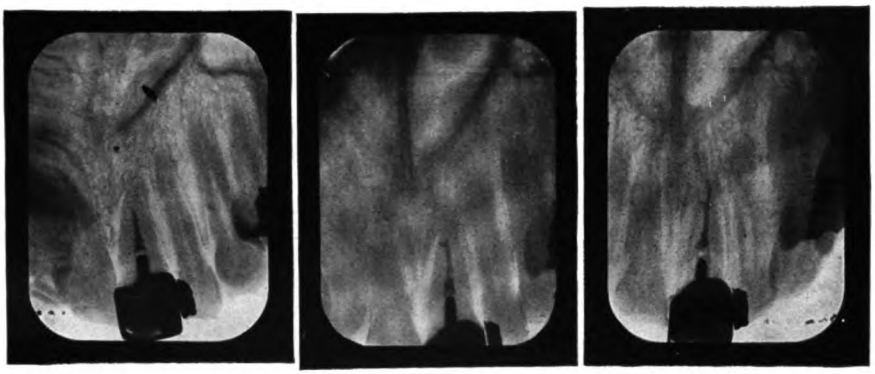

Figs. 476, 477 and 478. Repeated efforts to fill the canal of an upper central incisor. Note the little canal leaving the main canal, to the mesial, at right angles, in Figs. 477 and 478.

teeth never will be filled until radiographs are used to show the operator when he succeeds in placing his canal filling to the end of the root and when he fails.

Repeated Efforts to Fill Canals.

One of my friends says: " The great trouble in filling canals arises from the fact that the canal filling material doesn't go where you put it." And so it seems, indeed, when one commences to radiograph his canal fillings. You will place a canal filling in a single-rooted tooth and, *before* radiographic examination be willing to swear you have placed it to the end of the root, only to learn, after radiographic examination, that you have not.

Figures 476, 477 and 478 illustrate repeated efforts to fill the canal of a central incisor. This was done by an operator of unquestionable ability. Figure 476 illustrates the result of the first effort. The second effort is not illustrated—it had the same appearance as Figure 476. Figure 477 illustrates the result of the third effort. Note that, even though the operator is using force enough to send his canal filling material off into a canal which leaves the main canal almost at right angles to the mesial, still the main canal is not filled to its end. Figure 478 illustrates the fourth and successful effort to fill the canal to the end.

Old Standards and New.

Let us not waste time blaming anybody for what we now call bad canal work, for nobody is to blame. The only men who deserve condemnation for the work they have done in the past are those who have made *no effort* to fill canals. Until recently canal work was considered su.cessful, by dentists, physicians, scientists and the public, if it prevented subsequent toothache, and, measured by this standard, the canal work of the dental profession has been a success But the extensive use of the radiograph and the theory of mestatic infection set a new standard: Pulp canal work must not only prevent subsequent toothache, it must also prevent subsequent periapical infection. Methods which fulfill the requirements of the old standard fail to meet those of the new, so they must be discarded and replaced by methods which do eradicate and prevent the development of foci of infection.

The answer to the question: "What shall we do about our canal work?" is, we shall do *better* canal work and *we shall do less* canal work. We must practice the sort of canal work advocated by Callahan, Ottolengui, Rhein, Best, Biddle and other leaders in this work. But before we can adopt what we know to be the best methods in canal work we must educate the public to the point where they will *readily* permit us to practice such methods, and as we do this we will incidentally educate people to co-operate with us to prevent the necessity of canal work. Even the best methods in canal work can be and will be improved upon, but just at this time it is not common for dentists to make a practical application of the knowledge we already have on this subject.

I refrain, then, just now, from a consideration of the technic of better canal work, recognizing the fact that it has already been given to the profession time and time again, but it has not been accepted because economic conditions have made its acceptance impossible.

The Position of the Average Dentist.

The average dentist today occupies a rather difficult position. As Dr. Harry Carr facetiously expresses it, "If he does his canal work as he has been doing it, he gives his patients heart trouble. If he takes the time necessary, and does it as he now believes it should be done he gives them heart failure—when he presents his bill." This is funny because it is so pathetically true. Fees for canal work which has for its aim only the prevention of further toothache are only about one-fifth the amount which must be charged for canal work which is calculated to prevent subsequent periapical infection. Yet the fact remains, the more expensive methods must be adopted and practiced by all ethical dentists.

"But how?" cries the average dentist. "I cannot do this work unless I am paid for it, and my patients either will not or cannot pay me."

The patient who could but will not pay for good canal work gives me little concern. Such a patient is either impervious to reason or he or she has not had the matter presented in the proper light.

But patients who actually cannot afford the work (and there are thousands upon thousands of them) do give me much concern. Many people cannot afford good canal work because they need *so much* of it. If they had less of it to be done they could afford it. And, note this: it is important. Canal work becomes necessary when a tooth aches, and most toothache is *preventable.*

Where Thinking Leads Us.

And so we arrive where every thinking man arrives if he gives this problem of canal work sufficient consideration. We see that something must be done to prevent conditions which necessitate canal operations. We arrive at this conclusion if we consider the problem from a financial aspect, as I have just considered it; we arrive at this same conclusion if we consider the disasters of poor canal work or the difficulties or shortcomings of the best canal work; and we arrive at this same conclusion if we consider the unnecessary pain suffered and the waste of time and energy.

Something must be done to prevent conditions which necessitate canal work. That is, something must be done to stop the practice, common with most people, of deliberately allowing their teeth to ache before patronizing a dentist, instead of visiting him periodically and allowing him to fill and refill their teeth as soon as cavities appear and so prevent the occurrence of toothache and the necessity of canal operations. Figure 479 illustrates this idea of pulp conservation and prevention of toothache.

The thing which must be done is to educate the people to a better understanding of the folly of allowing their teeth to ache.

It would take years to accomplish this by lectures, tracts, magazine articles, newspaper articles, and personal advice. But it can be accomplished in twenty-four months by a publicity campaign conducted by the National Dental Association.

Campaign of Public Education Advocated.

Since we contemplate educating the public it might be well to stop and consider some of the characteristics of our prospective student that our efforts at teaching may be governed accordingly. The public is a big lazy, indifferent duffer, unwilling to learn anything. To teach him, you must

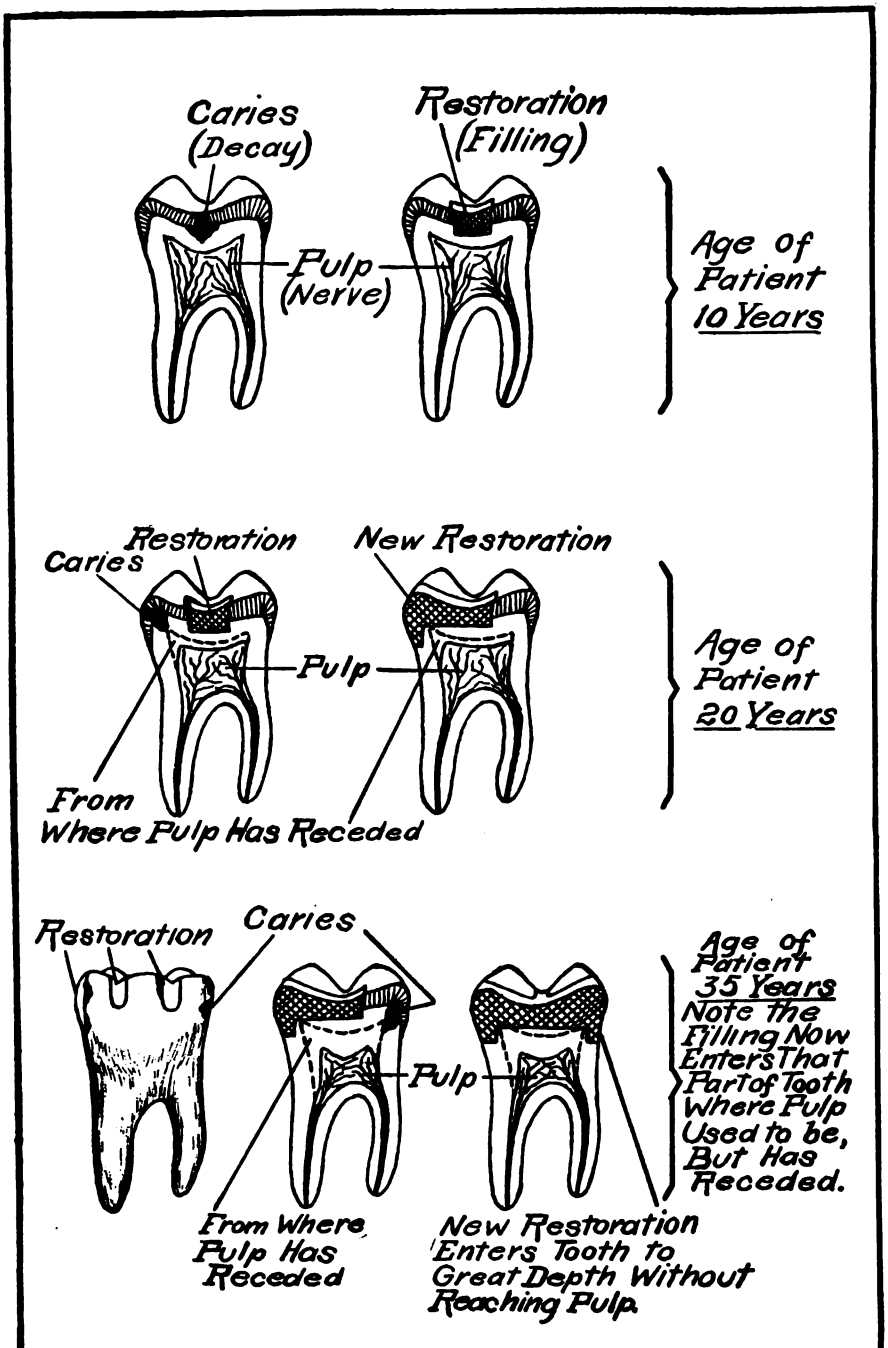

Fig. 479. A schematic drawing to show how teeth may be taken care of in such a way as to avoid the necessity of pulp canal work. (Drawing by W. O. Godwin, junior dental student, 1917.)

amuse him, arouse his curiosity, scare him, or make the lesson so easy that it can be learned without effort. It should be borne in mind, also, that the public has a thousand or so other teachers besides us annoying him. The socialist wishes to educate him to save him from capitalism; the capitalist wishes to educate him to save him from socialism; the minister wishes to educate him in right conduct to save his soul; the physical culturist wishes to educate him to save him from physical deterioration; the sex hygienist wishes to educate him to save him from syphilis and gonorrhea, and so on and on. No wonder he is lazy and indifferent He has to be in self-defense.

If you accept my picture of the public as a student, as I have drawn it, you will agree with me that it is useless to attempt to teach him a long lesson. It would be futile to attempt to teach him this, for example:

"Toothache can be avoided.

"It can be avoided if you will visit your dentist at regular intervals and have him fill and refill your teeth as soon as cavities occur.

"You should avoid toothache.

"Because, to commence with, who wants to suffer with the toothache, anyhow?

"Because a tooth which has ached must be treated.

"Because the treatment of teeth takes much of your time, and your time is valuable.

"Because the treatment of teeth by modern methods is very expensive. (In fact, toothache and the treatment it necessitates is a luxury to be indulged in to any great extent only by the well-to-do.)

"Because once a tooth is allowed to ache, there is the chance that you may lose it, and you need all the teeth you have.

"And because, unless a tooth which has once ached is properly treated, it may later ruin your health and life by causing rheumatism, heart trouble, gastric ulcer and other serious diseases.

"So

"You mustn't let your teeth ache."

I would like to teach all of the foregoing to the public, and, if I could, it would be the nearest thing to a solution of the problem of canal work we have ever had. But it is impossible to teach so much, and fortunately it is not necessary. A small part of the public will demand the lesson in full as I have just given it, even asking for further elaboration, and we can give it to them, but for the big, big public as a whole, the lesson must be shorter, very much shorter. Something like the lessons taught by the big commercial advertisers, such as "He Hears His Master's Voice," "Eventually, Why Not Now?" "There's a Reason," and others.

In the practice of radiodontia I have this problem of canal work brought constantly before me and I have given much thought to the selection of something sufficiently short to reach the public and yet capable of accomplishing the purpose I wish it to accomplish.

I suggest Fig. 480 as an official slogan for the National Dental Association, to be used on bill-boards, street-car cards, advertising spaces in the magazines, on the handles of tooth-brushes, on tubes containing tooth pastes, anywhere and everywhere where people will see it.

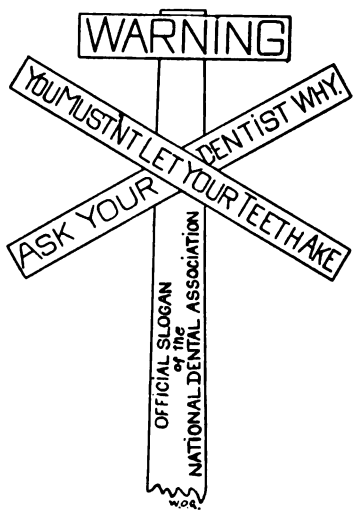

Fig. 480. Suggested as an official slogan for the National Dental Association.

Aside from the advantage of brevity, this has the further advantage of arousing the curiosity. When first read it sounds rather nonsensical, and so gets a second thought from the reader. It allows one who reads it to become facetious with himself and remark to himself: "Fine advice, that. I wonder who thinks I have toothache just for spite." And its greatest advantage is, *it can be remembered.* Even that part of the public which demands its dentists to give it the lesson in full will forget most of the lesson and remember only that there *are* good reasons why you should not let your teeth ache.

The situation now is that no person feels any especial pang of regret and remorse when they "suddenly"—after a few years of neglect—develop toothache. And why should they? The attitude, if not the teaching, of the dental profession has been: "Ah, Mr. Citizen, you have the toothache! Well, that doesn't make any particular difference. I can fix that in a jiffy for ninety-eight cents."

Is the Publicity Plan Advocated Practical?

Even though you see the necessity for publicity work as I see it, and are therefore in favor of it, you may, nevertheless, think that I am wanting the National Dental Association to do something it cannot do. Let us see if I am in the habit of asking for impossible things. What is my attitude toward dentists who, in my mind, stand convicted of doing bad canal work? I do not say to them: "You must adopt more modern and expensive methods of treatment forthwith, and that's all there is to it," for I know that the great amount of canal work to be done makes this an economic impossibility. Neither do I ask the National Dental Association to do something which is economically impossible. What I want it to do, it can do. It can do the publicity work I suggest, and it must. We owe it to humanity and ourselves.

The man who thinks this campaign is a financial impossibility has not given this matter sufficient consideration. We wish to do two things: We wish to cause the people to ask the meaning of the You-Mustn't-Let-Your-Teeth-Ache slogan and we wish to have dentists prepared to answer inquiries regarding it.

The profession of dentistry could not, it is my opinion, raise enough money to get the You-Mustn't-Let-Your-Teeth-Ache slogan to the people. But there is a way to get this slogan before the people without spending a fortune: The manufacturers of dentifrices and tooth-brushes spend millions of dollars annually for advertising. Most of them would be glad to use the slogan I have suggested in a corner of all of their advertisements if they were asked to do so by the National Dental Association, and if they understood the humane object of this campaign. It is a tremendous and pitiful mistake for any one class of men to think they are any better than another class, and dentists who think manufacturers are not interested in the welfare of humanity are "dead wrong." Forsythe and Eastman are manufacturers you know. So much for the problem of reaching the people.

Educating Dentists.

The problem of preparing dentists to promote the education of the public started by a Never-Let-Your Teeth-Ache campaign can be handled in a most inexpensive way. The pages of our dental magazines are always at our disposal and the owners of these magazines have always done their share, or more than their share, to support such enterprises as the one under consideration.

I would not have you think that I am obsessed with the delusion that it will take no money at all to conduct an educational campaign such as

I have outlined, for of course it will. But it will not take "bushels of it"; it will not take any more than can be raised with ease; for there are thousands of dentists who are more than willing to contribute; they want to contribute to such a cause.

In the Meantime. It is not impossible, but it is not probable either, that the publicity campaign outlined in the preceding pages will be developed. If it is never developed, or until it is developed, or while it is developing, I advise dentists who desire to practice good canal work to avail themselves of the help afforded in Figures 481A to 486. Explain one or two or all of these plates to patients and you will gain a more intelligent co-operation than you have hitherto found it possible to get.

Before dental radiographs were used the dentist who wished to explain canal work and abscess formation to his patients was compelled to use drawings and models for the purpose. A drawing or a model does not make the same impression produced by a radiograph, because a drawing of an abscess is anybody's and everybody's abscess. Somebody has said something like this: "Everybody's work is nobody's work." Likewise everybody's abscess is nobody's abscess; nobody will own it. But an abscess in a radiograph is some particular individual's abscess; it belongs solely and personally to Mrs. Jones, Mrs. Smith or Mr. Hancock, which makes a world of difference.

Figures 481A to 486 illustrate how the X-rays may be used to advantage in educational work. A careful study of these plates will prove illuminative to most dentists and, as an aid to dentists in explaining to patients the difference between good canal work and no canal work, or poor canal work, they should prove to be of the utmost value. Indeed they seem to me to be, at present, the answer for the men who wish to practice good canal work, but have been unable to gain the co-operation of their patients.

Should Canal Filling Material Encapsulate End. There has been much discussion recently as to whether canal filling material should just reach the end of the root or pass through it and encapsulate the end. I leave it a more or less open question as to which is preferable, believing myself, however, the ideal filling is one which just reaches the end of the canal, filling all apical foramina, but not passing through into the periapical space. While it is my opinion that such a canal filling is the ideal one, it is my further opinion that this ideal cannot, as a rule, be realized, for, no matter how many radiographs are made at different

stages of the work, the fact remains that just at the time the operator is engaged in the work of filling the canal, he is working in the dark and in order to get the canal filling *to* the end of the root, he will usually force a little *through*. As has been pointed out in the Appendix to Chapter VI it is sometimes impossible, in upper biscupids and lower molars particularly, to determine from radiographs whether a canal filling reaches the apex or not, unless a little passes through appearing as a little button or cap at the root end.

Canal filling material which passes through the root in a soft condition and " mushes " out over the root end seems to cause no irritation. A gutta percha point protruding through the apex, however, is more likely to produce irritation, pain and suppuration.

It is very unfortunate, but it is very true, that we are much more likely to have post-operative pain if we fill canals just to or just through the end of the root than we are when the canal filling fails to reach the end. It is very discouraging for the conscientious dentist to lose his patients because he has filled canals well and there has been pain following the operation. He knows he might have avoided the production of the pain by being less thorough. If he has forced a little filling material through the end of the root, it is not unlikely that he will be condemned by both the patient and the patient's physician. He very probably has received a fee which looked large to the patient but which, considering the time he spent on the case, is less than other dentists are charging who do not fill canals but whose patients do not suffer after the operation.

Pain after canal filling should be controlled in many cases by the use of some anodyne, such as an aspirin-codein mixture.

For example

℞ Acetylsalicylic acid grs. xxx
Codein sulphate grs. ii.
M. Ft. Caps. No. xii.
Sig. If in pain take one capsule. Repeat in thirty minutes if necessary. Thereafter every two hours if in pain.

Filling material through the root end of a lower molar may pass in the inferior dental canal and encroach on the inferior dental nerve when the pain is very great and extraction of the tooth may be necessary.

What is a Bad Canal Filling.

At a dental meeting recently a man asked me, " Is a mechanically imperfect canal filling necessarily a ' bad ' canal filling? "

Look at Figure 487. To the best of our ability to judge, dental abscesses produce diseases like this, and imperfect canal fillings produce

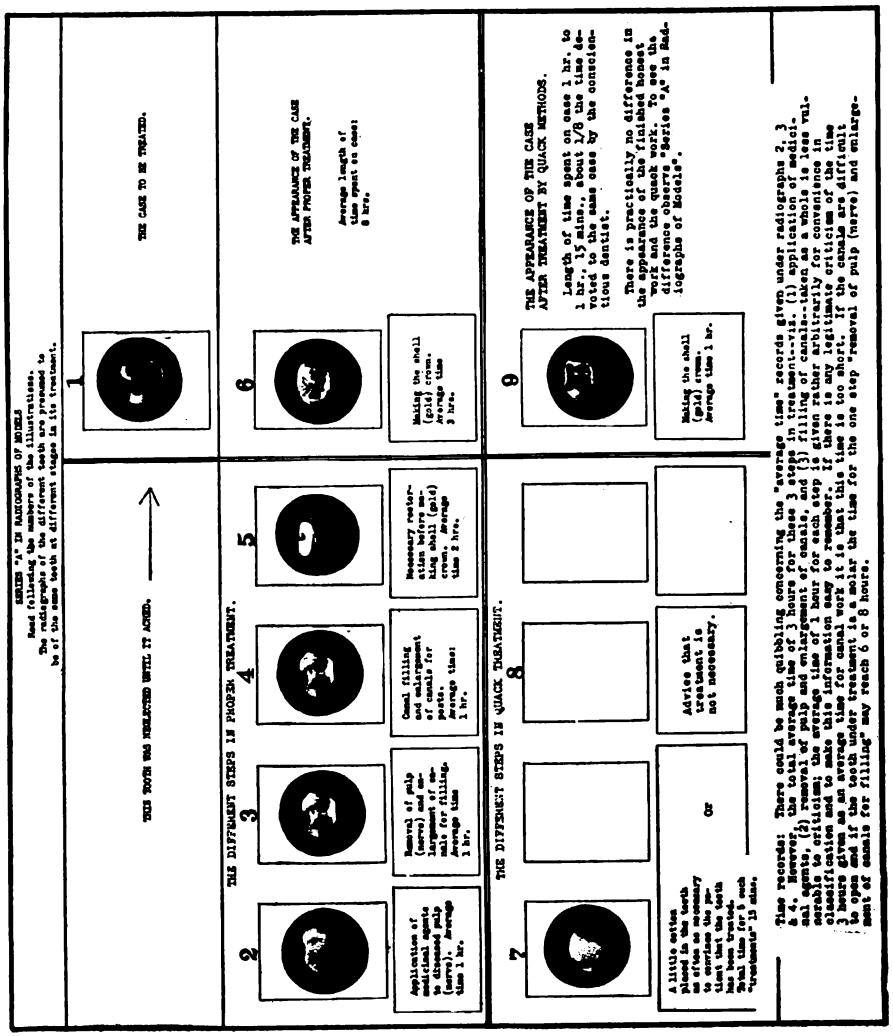
SERIES "A" IN RADIOGRAPHS OF MODELS
Read following the numbers of the illustrations.
The radiographs of the different teeth are presumed to be of the same teeth at different stages in its treatment.
THIS TOOTH WAS NEGLECTED UNTIL IT ACHED.
1
THE CASE TO BE TREATED.
THE DIFFERENT STEPS IN PROPER TREATMENT.
2
Application of medicinal agents to diseased pulp (nerve). Average time 1 hr.
3
Removal of pulp (nerve) and enlargement of canals for filling. Average time 1 hr.
4
Canal filling and enlargement of canals for posts. Average time: 1 hr.
5
Necessary restoration before making shell (gold) crown. Average time 2 hrs.
6
THE APPEARANCE OF THE CASE AFTER PROPER TREATMENT.
Average length of time spent on case: 8 hrs.
Making the shell (gold) crown. Average time 3 hrs.
THE DIFFERENT STEPS IN QUACK TREATMENT.
7
A little cotton placed in the tooth as often as necessary to convince the patient that the tooth has been treated. Total time for 5 such "treatments" 15 mins.
Or
8
Advice that treatment is not necessary.
9
THE APPEARANCE OF THE CASE AFTER TREATMENT BY QUACK METHODS.
Length of time spent on case 1 hr. to 1 hr., 15 mins., about 1/8 the time devoted to the same case by the conscientious dentist.
There is practically no difference in the appearance of the finished honest work and the quack work. To see the difference observe "Series "A" in Radiographs of Models".
Making the shell (gold) crown. Average time 1 hr.
Time records: There could be much quibbling concerning the "average time" records given under radiographs 2, 3 & 4. However, the total average time of 3 hours for these 3 steps in treatment--viz. (1) application of medicinal agents, (2) removal of pulp and enlargement of canals, and (3) filling of canals--taken as a whole is less vulnerable to criticism; the average time of 1 hour for each step is given rather arbitrarily for convenience in classification and to make this information easy to remember. If there is any legitimate criticism of the time 3 hours given as an average time for canal work it is that this time is too short. If the canals are difficult to open and if the tooth under treatment is a molar the time for the one step "removal of pulp (nerve) and enlargement of canals for filling" may reach 6 or 8 hours.

Fig. 481A.

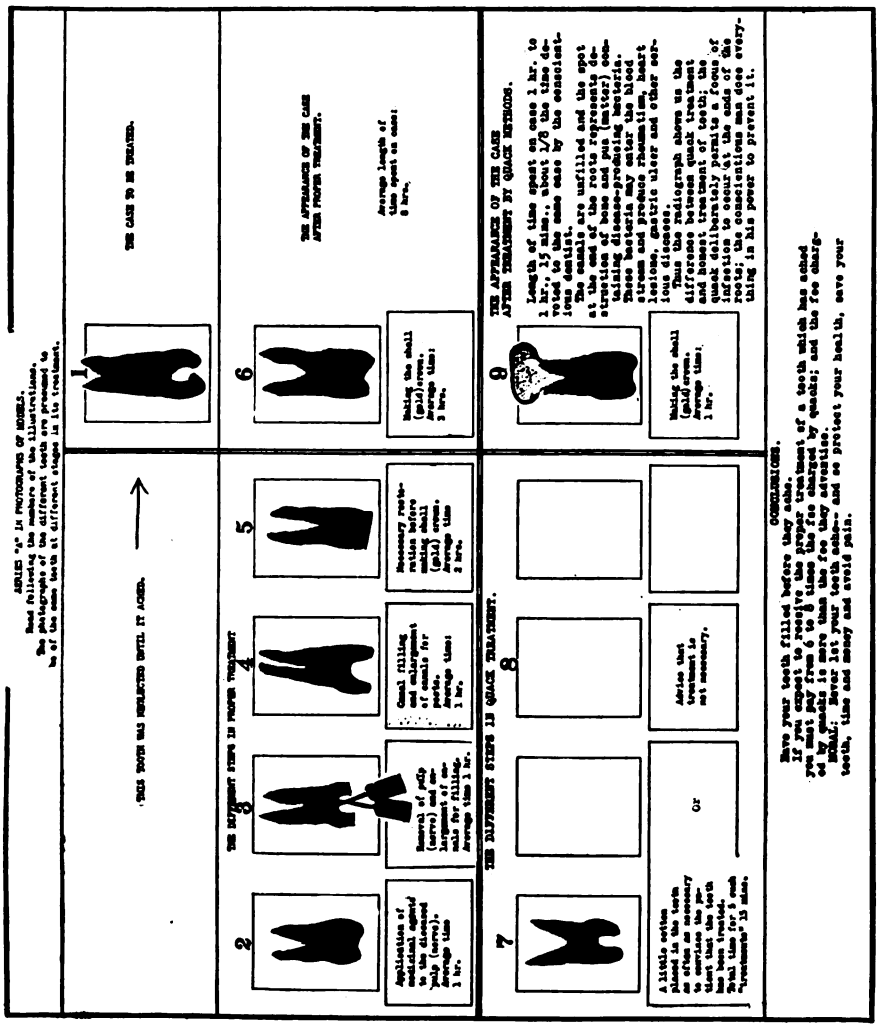
ARRIES "A" IN PHOTOGRAPHS OF MODELS.
Read following the numbers of the illustrations.
The photographs of the different teeth are presumed to be of the same teeth at different stages in its treatment.
THIS TOOTH WAS REFLECTED UNTIL IT ACHED.
THE CASE TO BE TREATED.
THE DIFFERENT STEPS IN PROPER TREATMENT
THE APPEARANCE OF THE CASE AFTER PROPER TREATMENT.
Average length of time spent on case: 8 hrs.
THE DIFFERENT STEPS IN QUACK TREATMENT.
THE APPEARANCE OF THE CASE AFTER TREATMENT BY QUACK METHODS.
Or
CONCLUSIONS.
Have your teeth filled before they ache.
If you expect to receive the proper treatment of a tooth which has ached you must pay from 6 to 8 times the fee charged by quacks; and the fee charged by quacks is more than the fee they advertise.
NORAL: Never let your teeth ache— and so protect your health, save your teeth, time and money and avoid pain.

Fig. 481B.

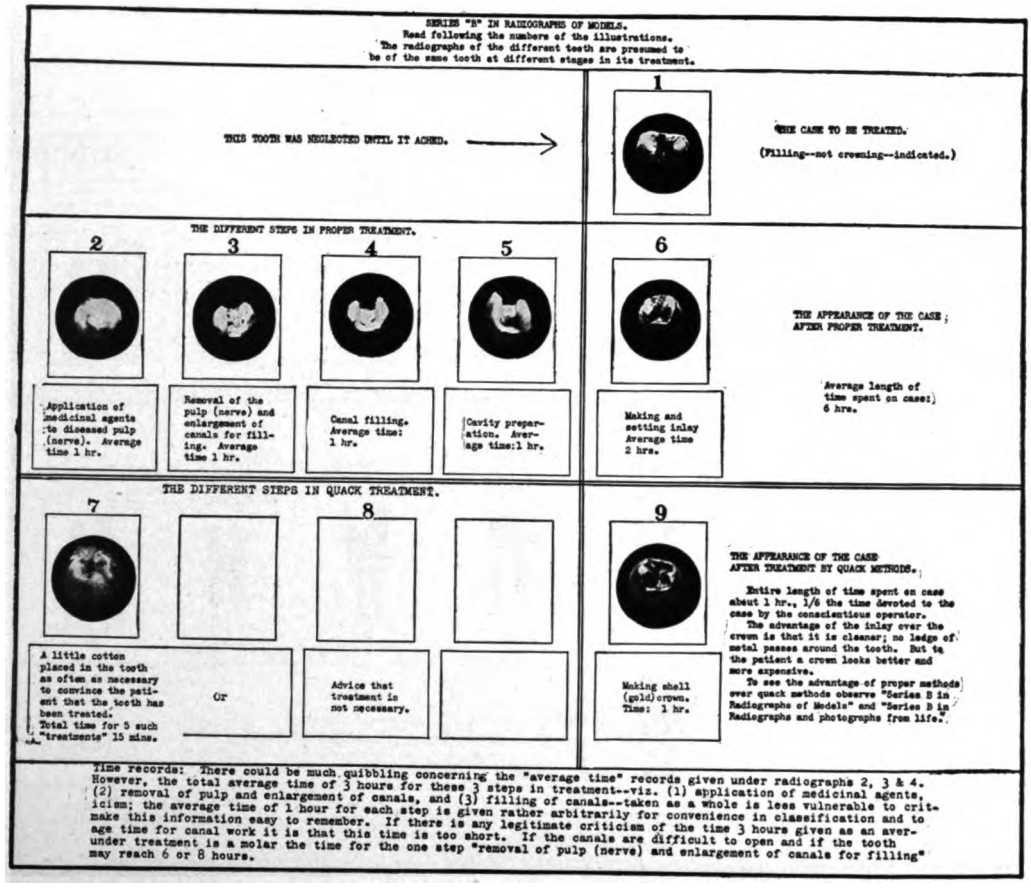
SERIES "B" IN RADIOGRAPHS OF MODELS.
Read following the numbers of the illustrations.
The radiographs of the different teeth are presumed to be of the same tooth at different stages in its treatment.
THIS TOOTH WAS NEGLECTED UNTIL IT ACHED.
1
THE CASE TO BE TREATED.
(Filling--not crowning--indicated.)
THE DIFFERENT STEPS IN PROPER TREATMENT.
2
3
4
5
6
Application of medicinal agents to diseased pulp (nerve). Average time 1 hr.
Removal of the pulp (nerve) and enlargement of canals for filling. Average time 1 hr.
Canal filling. Average time: 1 hr.
Cavity preparation. Average time: 1 hr.
Making and setting inlay Average time 2 hrs.
THE APPEARANCE OF THE CASE AFTER PROPER TREATMENT.
Average length of time spent on case: 6 hrs.
THE DIFFERENT STEPS IN QUACK TREATMENT.
7
8
9
A little cotton placed in the tooth as often as necessary to convince the patient that the tooth has been treated. Total time for 5 such "treatments" 15 mins.
Or
Advice that treatment is not necessary.
Making shell (gold) crown. Time: 1 hr.
THE APPEARANCE OF THE CASE AFTER TREATMENT BY QUACK METHODS.
Entire length of time spent on case about 1 hr., 1/6 the time devoted to the case by the conscientious operator.
The advantage of the inlay over the crown is that it is cleaner; no ledge of metal passes around the tooth. But to the patient a crown looks better and more expensive.
To see the advantage of proper methods over quack methods observe "Series B in Radiographs of Models" and "Series B in Radiographs and photographs from life".
Time records: There could be much quibbling concerning the "average time" records given under radiographs 2, 3 & 4. However, the total average time of 3 hours for these 3 steps in treatment--viz. (1) application of medicinal agents, (2) removal of pulp and enlargement of canals, and (3) filling of canals--taken as a whole is less vulnerable to criticism; the average time of 1 hour for each step is given rather arbitrarily for convenience in classification and to make this information easy to remember. If there is any legitimate criticism of the time 3 hours given as an average time for canal work it is that this time is too short. If the canals are difficult to open and if the tooth under treatment is a molar the time for the one step "removal of pulp (nerve) and enlargement of canals for filling" may reach 6 or 8 hours.

Fig. 482A.

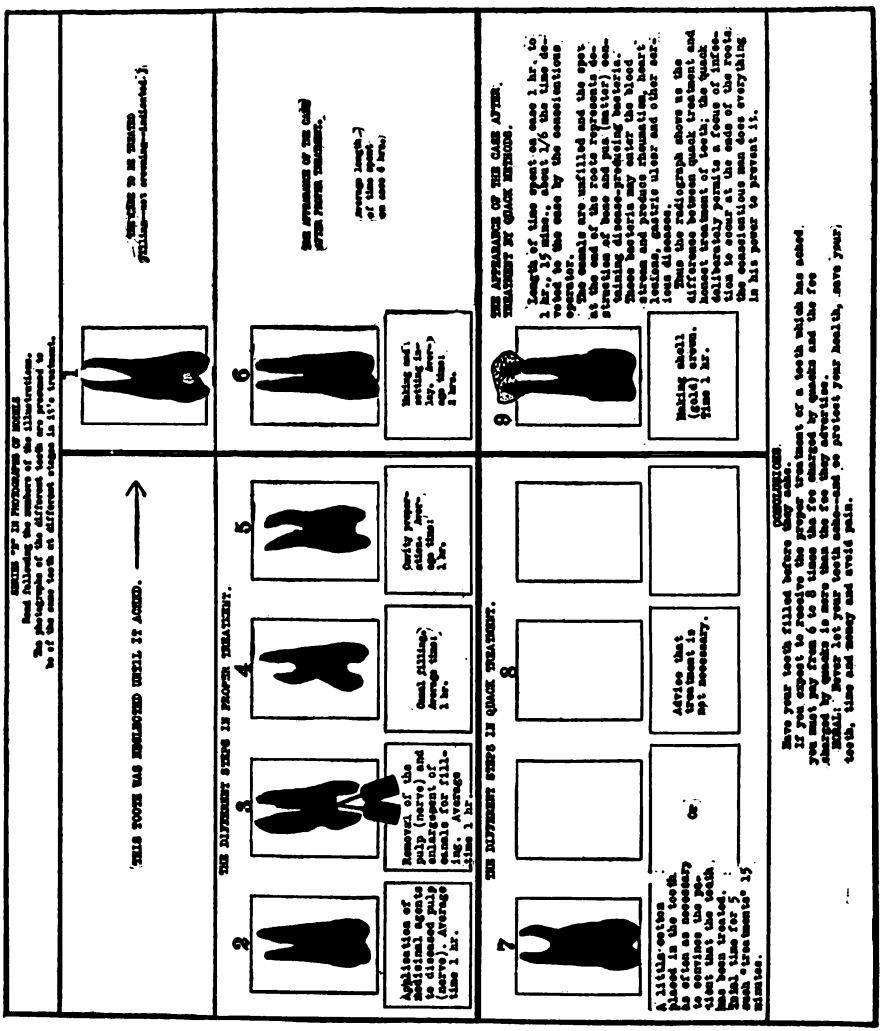
THIS TOOTH WAS NEGLECTED UNTIL IT ACHED.
THE DIFFERENT STEPS IN PROPER TREATMENT.
THE DIFFERENT STEPS IN QUACK TREATMENT.
THE APPEARANCE OF THE CASE AFTER TREATMENT BY QUACK METHODS.
CONCLUSIONS.

Fig. 482B.

SERIES "F" IN RADIOGRAPHS AND PHOTOGRAPHS FROM LIFE (OPERATOR DR. FUTTER)
Read following the numbers of the illustrations.
All radiographs of the same teeth except #9 which we presume to be the same tooth. The time records are actual—not approximate.

1

RADIOGRAPHIC AND PHOTOGRAPHIC APPEARANCE OF THE CASE TO BE TREATED.

THIS TOOTH WAS NEGLECTED UNTIL IT ACHED. ⟵

THE DIFFERENT STEPS IN PROPER TREATMENT.

2

Application of medicinal agents to diseased pulp (nerve). Time: 45 minutes.

3

Removal of the pulp (nerve) and enlargement of canals for filling. Time: 1 hr. 45 mins.

4

Canal filling (Callahan method) Time: 30 mins.

5

Cavity preparation for inlay. Time: 1 hr. and 20 mins.

6

RADIOGRAPHIC AND PHOTOGRAPHIC APPEARANCE OF THE CASE AFTER TREATMENT BY CORRECT METHODS.

Entire length of time spent on case: 6 hrs., 5 mins.

Making metal and inlay and setting inlay. Time: 1 hr. and 45 mins.

THE DIFFERENT STEPS IN QUACK TREATMENT.

7

A little cotton placed in the teeth as often as necessary to convince the patient that the teeth has been treated. Total time for 5 such "treatments" 15 mins.

8

Or

Advise that treatment is not necessary.

9

RADIOGRAPHIC AND PHOTOGRAPHIC APPEARANCE OF THE CASE AFTER TREATMENT BY QUACK METHODS.

Length of time spent on case by quacks: about 1 hr. approximately 1/6 the time devoted to such a case by the conscientious operator.

The Canal is unfilled and the spot at the end of the root represents a hole in the bone filled with pus—i. e. "matter"—and germs which make cripples, invalids and cause death.

Though the photograph does not, the radiograph shows us the difference between good and poor dental work.

Making shell (gold) crown. Time: 1 hr.

CONCLUSIONS.

Have your teeth filled before they ache.
If you expect to receive the proper treatment of a tooth which has ached you must pay from 6 to 8 times the fee charged by quacks and the fee charged by quacks is more than the fee they advertise.
REMEMBER. Never let your teeth ache—and so protect your health, save your teeth, time and money and avoid pain.

Fig. 483.

SERIES "B" IN RADIOGRAPHS AND PHOTOGRAPHS FROM LIFE
Read following the numbers of the illustrations.
All radiographs of the same teeth except #9 which is presumed to be the same tooth. Time records are actual--not approximate.
THIS TOOTH WAS NEGLECTED UNTIL IT ACHED.
RADIOGRAPHIC AND PHOTOGRAPHIC APPEARANCE OF THE CASE TO BE TREATED.
(Filling—not crowning—indicated).
THE DIFFERENT STEPS IN PROPER TREATMENT.
2
Application of medicinal agents to diseased pulp (nerve). Time 30 mins.
3
Enlargement of canals for filling. Time 1 hr. & 30 mins.
4
Filling canals. (Pieces of gutta-percha method). Time 30 mins.
5
Cavity preparation for inlay. Time: 1 hr.
6
RADIOGRAPHIC AND PHOTOGRAPHIC APPEARANCE OF THE CASE AFTER TREATMENT BY CORRECT METHODS.
Entire length of time devoted to case: 6 hrs., 25 mins.
(N. B. One of the canal fillings—the buccal—seems not to reach the end of the root. This is due to the angle at which the radiograph was made.)
Making, setting and finishing inlay. Time: 2 hrs. & 15 mins.
THE DIFFERENT STEPS IN QUACK TREATMENT.
7
A little cotton placed in the tooth as often as necessary to convince the patient that the tooth has been treated. Total time for 5 such "treatments": 15 mins.
Or
8
Advice that treatment is not necessary.
9
RADIOGRAPHIC AND PHOTOGRAPHIC APPEARANCE OF THE CASE AFTER TREATMENT BY QUACK METHODS.
Time spent on case: about 1 hr., approximately 1/4 the time devoted to the case by the conscientious operator.
The photographs--#6 & 9 show only the difference in appearance between an inlay filling and a crown and give no hint of the difference between good and poor dental operations. Compare radiographs #6 & 9, however, and see in #9 the loss of bone at the side of the root due to the irritation caused by the ill-fitting crown.
Making steel (gold) crown. Time 1 hr.
CONCLUSIONS
Have your teeth filled before they ache.
If you expect to receive the proper treatment of a tooth which has ached you must pay from 6 to 8 times the fee charged by quacks; and the fee charged by quacks is more than the fee they advertise.
MORAL: Never let your teeth ache--and so protect your health, save your teeth, time and money and avoid pain.

Fig. 484.


RADIOGRAPHS FROM LIFE (OPERATOR DR. PUTTER.)
Read following the numbers of the illustrations.
All radiographs are of the same tooth except #8 which is presumed to be the same tooth. The time records are actual—not approximate.
THIS TOOTH WAS NEGLECTED UNTIL IT ACHED.
1
THE CASE TO BE TREATED.
(Filling—not crowning—indicated.)
2
Application of medicinal agents to diseased pulp (nerve). Time 40 Mins.
3
Removal of pulp (nerve) and enlargement of canal for filling Time 35 mins.
4
Canal filling. Time 20 mins.
5
Cavity preparation, making and setting inlay. Time 4 hrs., 15 mins.
THE DIFFERENT STEPS IN PROPER TREATMENT.
THE APPEARANCE OF THE CASE AFTER TREATMENT BY PROPER METHODS.
Entire length of time spent on case 6 hrs.
The time devoted to cavity preparation, model making, inlay making, setting and finishing, is a little longer than usual for such a case. "Things went wrong". Somewhere in the course of conscientious treatment some things usually do "go wrong" and additional time is necessary for corrections. Since the quack does not work to a high ideal he practically never finds that it takes him longer to finish an operation than he anticipated.
6
A little cotton placed in the tooth as often as necessary to convince the patient that the tooth has been treated. Total time for 5 such "treatments" 15 mins.
Or
7
Advice that treatment is not necessary.
8
Making shell (gold) crown. Time 1 hr.
THE DIFFERENT STEPS IN QUACK TREATMENT.
THE APPEARANCE OF THE CASE AFTER TREATMENT BY QUACK METHODS.
Length of time spent on case 1 hr. to 1 hr., 15 mins., about 1/6 the time devoted to the case by the conscientious operator.
The canal is unfilled and the spot at the end of the root represents destruction of bone and pus (matter) containing disease—producing bacteria. These bacteria may enter the blood stream and produce rheumatism, heart lesions, gastric ulcer and other serious diseases.
Thus the radiograph shows us the difference between quack treatment and honest treatment of teeth; the quack deliberately permits a focus of infection to occur at the end of the root; the conscientious man does everything in his power to prevent it.
Conclusions.
Have your teeth filled before they ache.
If you expect to receive the proper treatment of a tooth which has ached you must pay from 6 to 8 times the fee charged by quacks; and the fee charged by quacks is more than the fee they advertise.
MORAL: Never let your teeth ache—and so protect your health, save your teeth, time and money and avoid pain.

Fig. 485.

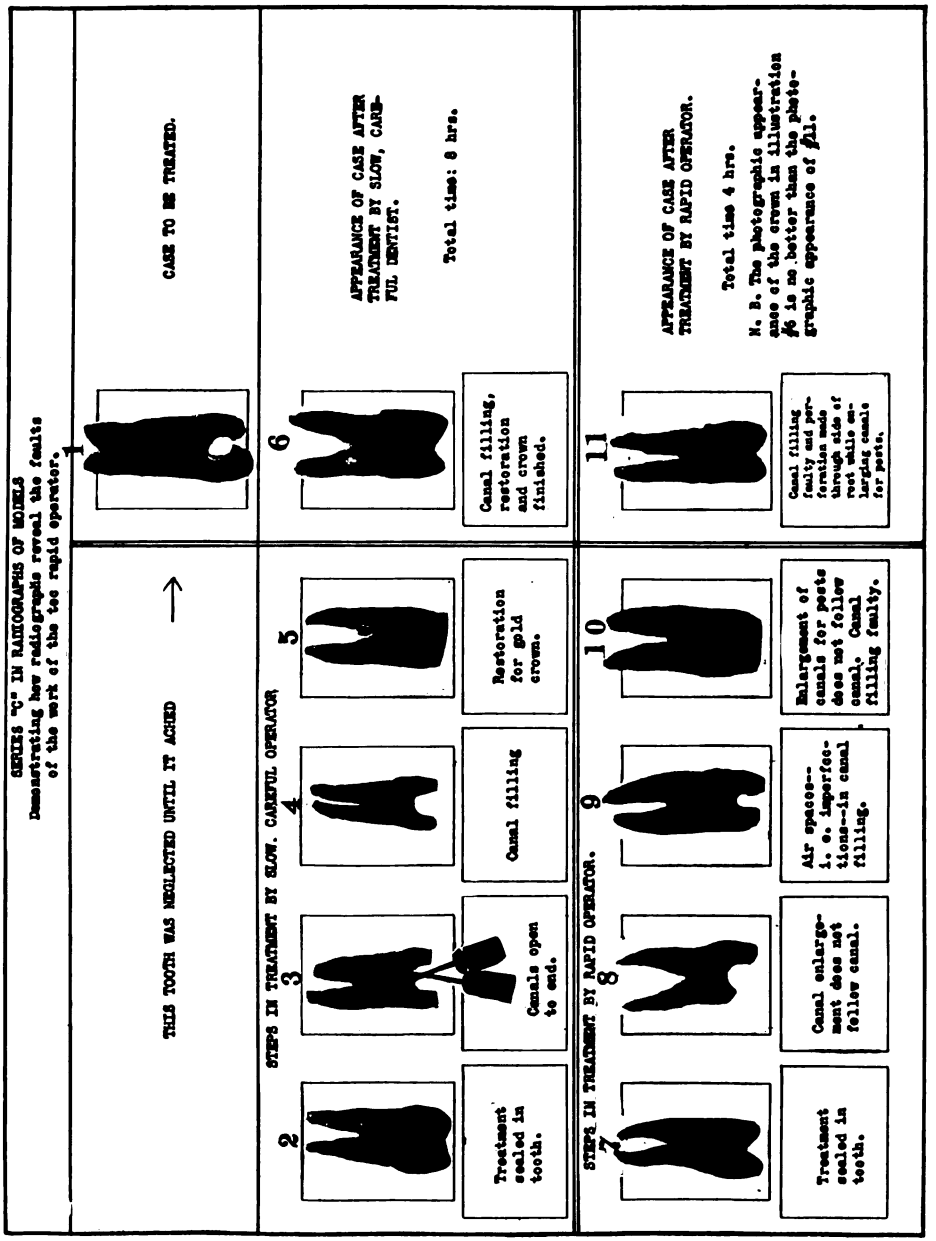
SERIES "C" IN RADIOGRAPHS OF MODELS
Demonstrating how radiographs reveal the faults of the work of the too rapid operator.
1
CASE TO BE TREATED.
THIS TOOTH WAS NEGLECTED UNTIL IT ACHED
STEPS IN TREATMENT BY SLOW, CAREFUL OPERATOR
2
Treatment sealed in tooth.
3
Canals open to end.
4
Canal filling
5
Restoration for gold crown.
6
APPEARANCE OF CASE AFTER TREATMENT BY SLOW, CAREFUL DENTIST.
Total time: 8 hrs.
Canal filling, restoration and crown finished.
STEPS IN TREATMENT BY RAPID OPERATOR.
7
Treatment sealed in tooth.
8
Canal enlargement does not follow canal.
9
Air spaces--i. e. imperfections--in canal filling.
10
Enlargement of canals for pasts does not follow canal. Canal filling faulty.
11
APPEARANCE OF CASE AFTER TREATMENT BY RAPID OPERATOR.
Total time 4 hrs.
N. B. The photographic appearance of the crown in illustration #6 is no better than the photographic appearance of #11.
Canal filling faulty and perforation made through side of root while enlarging canals for pasts.

Fig. 486.

dental abscesses. So mechanically imperfect canal fillings are "bad" canal fillings, aren't they? Even mechanically perfect canal fillings may, under certain conditions, be very undesirable things to have in the mouth,

Fig. 487. Case of arthritis deformans. To the best of our ability to judge, oral infection causes diseases like this. (By courtesy of the *Dental Digest*.)

Fig. 488. Case of arthritis deformans caused by oral infection. (Courtesy of Dr. Thomas B. Hartzell.)

for a canal filling may be mechanically perfect without being perfect from a surgical—i. e., a bacteriological—standpoint and such a canal filling is certainly "bad."

Any sort of canal filling then, and certainly mechanically imperfect canal fillings, worry the conscientious dentist and physician when they are in the mouths of patients who are seriously ill with any disease which might possibly be produced by some focus of infection.

Through the courtesy of Dr. Thomas B. Hartzell I am able to print Figure 488. Here is a man with arthritis deformans caused, to the best of the ability of those in charge of the case to judge, by dental infection. Think of this for a moment, then answer the question: Shall we continue to allow people to lay themselves liable to diseases like this, or shall we do "*less* and *better* canal work?"

An Experience And a Lesson.

Case: One of arthritis, neuritis, malnutrition. Man had not been able to work for weeks. Referred to radiodontist by physician. Radiographic examination revealed dento-alveolar abscesses and much loss of osseous tissue,

due to pyorrhea. The affected teeth were extracted. The patient's condition improved promptly and continued to improve for several weeks. An upper anterior bridge was made, using the two cuspids for abutments. The Thursday before the Monday when the patient had arranged to go to work again, he suffered a relapse and developed pain in the region of one of the abutment cuspids. His physician again sent him to the radiodontist. A radiograph was made of the tooth causing pain. It showed the canal filling reaching only about two-thirds the distance to the apex

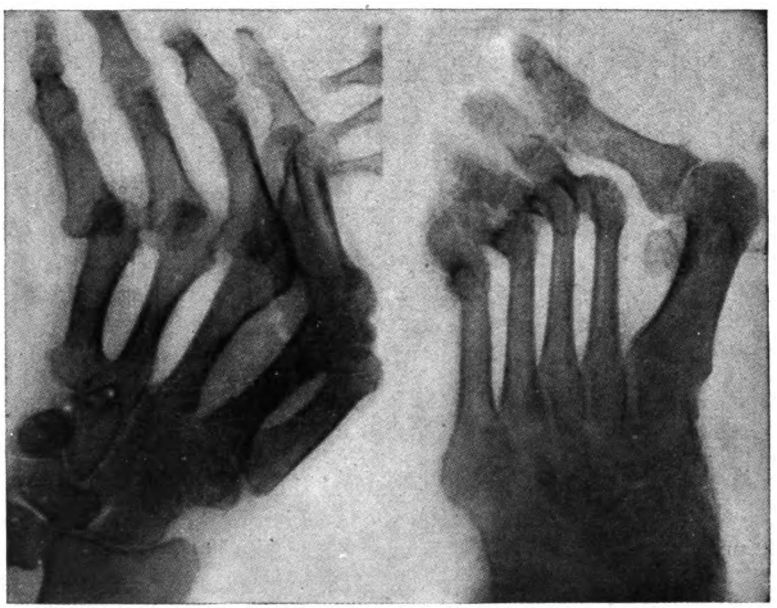

Fig. 489. Radiographs of hands of Fig. 488.

of the root, and tissue changes indicative of abscess formation in the periapical region. The bridge was removed, also the imperfect canal filling. The periapical tissues were disinfected by pumping a four per cent solution tincture of iodin in water through the root. Again the man's general physical condition began to improve, and continued to improve while the canal work in his mouth was done over again, this time checking the work with radiographs.

From the foregoing it will be seen that the time is already here when city dentists, at least (when this condition of affairs will prevail in the smaller town I do not attempt to say) must see to it that they fill canals. A man may practice septic canal work and not be caught at it, but if he places a mechanically imperfect canal filling in a tooth any one who looks at a radiograph of it can see his failure.

In the case just referred to the patient had paid seventy-five dollars for the bridge. Seventy-five dollars fastened to failures in canal work—failures *which might have been avoided* had radiographs been used to "verify" the canal fillings.

I question the necessity of always making a number of radiographs of single-rooted teeth to insure insertion of the canal filling to the end of the root. A radiograph before the tooth is opened, another with a wire reaching the end of the root and a third when the canal is filled, certainly cannot be considered bad practice, but I repeat, I question the *necessity* of any save the radiograph after the canal has been filled in the average, non-septic, single-rooted-tooth case.

Filling Canals of Molar Teeth.

And now we come to a consideration of the filling of the canals of molar teeth. Some dentists seem to think that it is impossible to fill the canals of any molar tooth to the apices of the roots. They are wrong. Other dentists seem to think that it is possible to fill the canals of all molar teeth to the apices of the roots. They, too, are wrong.

Figure 490 is a radiograph of the results of an assignment in technic for the Junior class (1916) at the Indiana Dental College. The assignment was that each student should open the canals of a dissociated molar through the ends of the roots, then fill the canals by the Callahan method. The following table (page 459) is a record of the results of this assignment.

A study of the table given will reveal the following pertinent facts:

Number of molar teeth, the canals of which were filled: 61.

Number of teeth used for this work: 225.

Thus the average is that over three teeth were used before the student succeeded in opening the canals of one.

Total time devoted to the teeth where efforts to open the canals met with failure: 185 hours 55 minutes.

Entire length of time consumed in the work of opening canals of 61 molar teeth, including the time spent on the failures: 286 hours 30 minutes.

It should be kept in mind that the foregoing time records do not include the time necessary to fill the canals, and further that, for this work, no time was consumed to adjust rubber dams and, in other ways, observe the rules of aseptic surgery.

Causes of Failure to Open Canals to End.

Three things in particular are responsible for the many failures: (1) Attempts to speed the work. (2) Lack of access. (3) Devoting time and thought to excessive enlargement of the canals near the pulp chamber instead

Student's number	The tooth filled	Time devoted to opening the canals of the teeth filled	The number of teeth discarded after efforts to open the canals	Time devoted to teeth which were discarded after efforts to open the canals	Total teeth used	Total time devoted to efforts to open the canals in a molar before success was attained
1	U. 2nd Mol.	:30	2	4:00	3	4:30
2	U. 1st Mol.	1:20	0	0	1	1:20
3	U. 2nd Mol.	2:15	6	5:00	7	7:15
4	U. 2nd Mol.	:45	22	13:00	23	13:45
5	U. 3rd Mol.	:30	1	1:00	2	1:30
6	L. 2nd Mol.	1:15	3	2:30	4	3:45
7	U. 2nd Mol.	1:00	4	2:00	5	3:00
8	L. 1st Mol.	2:30	2	1:30	3	4:00
9	U. 2nd Mol.	:45	2	2:45	3	3:30
10	L. 1st Mol.	1:40	2	3:15	3	4:55
11	L. 1st Mol.	:30	0	0	1	:30
12	U. 1st Mol.	2:30	1	2:00	2	4:30
13	Student	failed to hand	in work			
14	U. 1st Mol.	1:00	2	1:30	3	2:30
15	L. 1st Mol.	1:30	3	3:00	4	4:30
16	Student	failed to hand	in work			
17	L. 2nd Mol.	1:35	5	5:00	6	6:35
18	L. 2nd Mol.	:45	3	3:00	4	3:45
19	U. 2nd Mol.	2:15	1	5:15	2	7:30
20	U. 2nd Mol.	2:30	2	2:30	3	5:00
21	U. 1st Mol.	1:50	1	1:30	2	3:20
22	U. 2nd Mol.	1:30	1	3:00	2	4:30
23	U. 2nd Mol.	3:05	5	6:00	6	9:05
24	L. 1st Mol.	2:30	4	7:30	5	10:00
25	U. 2nd Mol.	3:05	5	5:00	6	8:05
26	L. 2nd Mol.	:35	1	:45	2	1:20
27	U. 1st Mol.	:40	4	1:10	5	1:50
28	U. 1st Mol.	3:15	0	0	1	3:15
29	L. 2nd Mol.	:35	0	0	1	:35
30	U. 2nd Mol.	2:30	2	6:00	3	8:30
31	L. 1st Mol.	:15	3	6:00	4	6:15
32	U. 1st Mol.	2:00	0	0	1	2:00
33	U. 1st Mol.	:55	1	1:15	2	2:10
34	U. 1st Mol.	4:45	4	5:00	5	9:45
35	U. 2nd Mol.	1:30	3	4:00	4	5:30
36	L. 2nd Mol.	1:00	2	1:45	3	2:45
37	U. 1st Mol.	3:00	2	1:30	3	4:30
38	U. 2nd Mol.	1:00	0	0	1	1:00
39	L. 1st Mol.	:55	1	1:00	2	1:55
40	L. 1st Mol.	:45	1	:50	2	1:35
41	U. 1st Mol.	1:15	5	2:30	6	3:45
42	U. 2nd Mol.	1:00	3	2:45	4	3:45
43	L. 2nd Mol.	:50	0	0	1	:50
44	U. 1st Mol.	4:30	1	1:30	2	6:00
45	L. 2nd Mol.	2:00	11	13:00	12	15:00
46	L. 2nd Mol.	2:00	2	1:15	3	3:15
47	L. 2nd Mol.	2:00	0	0	1	2:00
48	U. 2nd Mol.	:30	4	4:00	5	4:30
49	U. 1st Mol.	:30	5	6:10	6	6:40
50	U. 1st Mol.	1:30	0	0	1	1:30
51	L. 2nd Mol.	1:00	1	3:30	2	4:30
52	L. 1st Mol.	1:15	0	0	1	1:15
53	U. 3rd Mol.	:30	8	10:00	9	10:30
54	U. 1st Mol.	5:00	4	6:00	5	11:00
55	U. 1st Mol.	2:40	0	0	1	2:40
56	U. 1st Mol.	:25	3	3:15	4	3:40
57	U. 1st Mol.	1:15	3	6:00	4	7:15
58	U. 1st Mol.	2:00	0	0	1	2:00
59	U. 1st Mol.	1:30	1	2:00	2	3:30
60	L. 1st Mol.	1:30	3	5:30	4	7:00
61	U. 1st Mol.	4:00	9	9:00	10	13:00
62	U. 1st Mol.	2:00	0	0	1	2:00
63	L. 2nd Mol.	:40	0	0	1	:40
Totals	61	100:35	164	185:55	225	286:30

of using very small broaches to trace the canals to the ends of the roots.

A friend of mine, a keen observer, declares that " there are not ten dentists in the world who consistently open molar teeth sufficiently to make it a physical possibility to open the canals to the end." It is unfor-

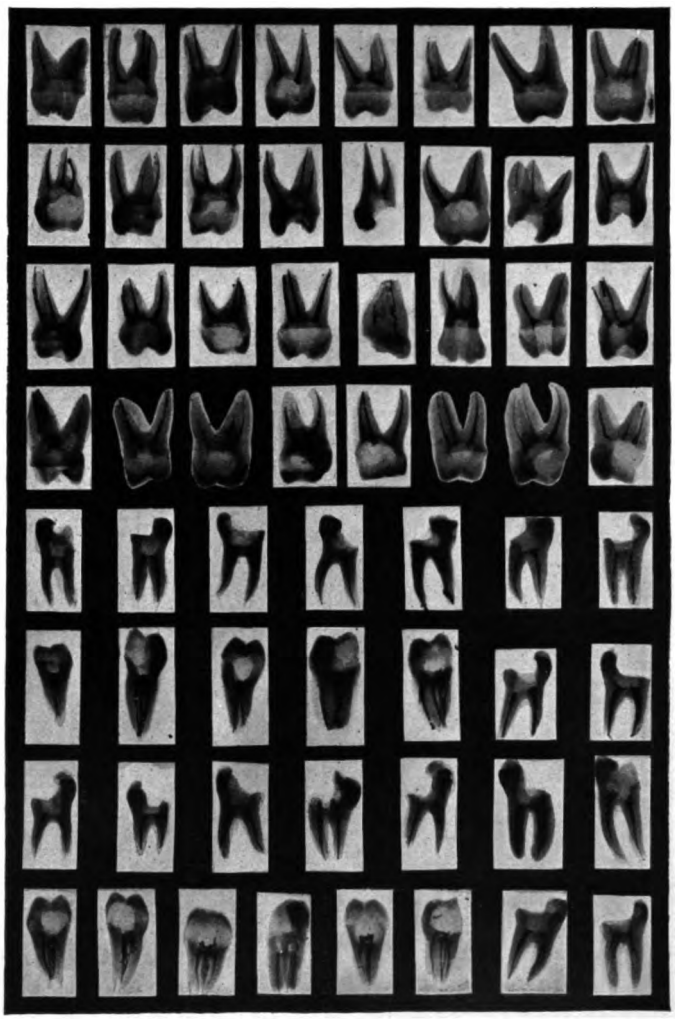

Fig. 490. Canal fillings in sixty-one molar teeth. The work was done by Junior dental students of the Indiana Dental College, academic year 1915-1916. Though the canals of all of the teeth were opened through the end, Fig. 490 represents only the first effort to fill them and many of them are very imperfectly filled.

tunate that the phrase " enlarge canals " is in such common use; it makes us think of the operation in the wrong way. The psychic influence would be better if we should discard the phrase " enlarging canals " for

opening canals. The operator, intent on opening canals, has his mind focused on the place he wishes to reach—the end of the root—while the man *enlarging canals* has his mind fixed essentially on just that part of the canal he is enlarging.

From a study of Figure 490 and chart relating to it, it would seem that, if given the economic opportunity, dentists *should* be able to fill the canals of, say, about one out of three molars, at least. (In the past, I should say, hardly one out of a thousand has been filled.) For, admitting

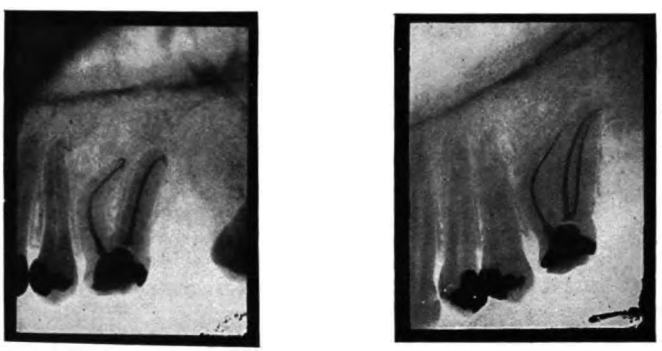

Fig. 491. Crooked canal of upper molar filled to the end. (By Dr. Ottolengui, N. Y. C.)

the students' advantage in working on extracted teeth instead of teeth in the mouth, it is not unfair to presume that dentists are more skillful than junior dental students. What the very skillful dentist may hope to do is illustrated in Figure 491, an upper molar filled by Dr. Ottolengui.

Oral Infection.

Reference to the interpretation of radiographs to determine oral infection has already been made in Appendix to Chapter VI, under Mistakes Numbers 28 and 29, and just following Mistake Number 41.

Evidence of Infection Seen in Radiographs.

The first thing to be said about evidence of infection which can be seen in radiographs is to emphasize the fact that *one cannot see infection in radiographs;* one sees *only evidence of infection.* Like all other evidence, it may be true and conclusive, it may be meager, or it may be false—the diagnostician must judge which.

The pulpless teeth seen in radiographs may be classified as follows: (1) Those which show well-filled canals and no bone change in the periapical region; (2) those which show imperfectly filled canals and no bone change in the periapical region; (3) those which show well-filled canals and bone, or root, destruction in the periapical region, and (4) those which show imperfectly filled canals and bone or root destruction in the periapical region. (See Chart B B at close of Appendix to Chap. VI.)

(1) Any pulpless tooth *may* be a source of infection—even one with a well-filled canal and no radiographic evidence of bone involvement. I believe this statement is true, but in practice I assume that a pulpless tooth with a well-filled canal and no evidence of bone change about it *is not* a source of infection, unless the history of the case and the symptoms are such as to definitely contradict this assumption.

(2) Any pulpless tooth with a faulty canal filling but showing no evidence of bone change in the apical region is likely a source of some infection. It is, at least, a potential source of infection.

(3) Any pulpless tooth with a well-filled canal showing bone destruction at its apex may be considered a source of infection unless it has but recently been treated and there has not been time for bone reconstruction to occur. A canal filling which reaches the end of the canal but does not fill the canal full is, of course, not a good canal filling.

(4) Any tooth showing an imperfect canal filling and bone destruction at its apex should be considered a focus of infection.

From the foregoing it will be seen that whether the radiograph shows us something which indicates infection or not is a matter of deduction. Thus, *local symptoms,* if there are any, and *the patient's physical conditon should govern our interpretation of radiographs.* If the patient is ill, having a disease which might be caused by a focus of infection, and

the conditions revealed by the radiograph are such as to indicate probable infection, and no other infection can be found in other parts of the body, it is good sense to assume that the radiographic evidence of *probable* infection is *actually* evidence of infection and act accordingly.

Extraction of Teeth to Overcome Infection

Physicians and dentists are prone to disagree regarding the advisability of extracting teeth to overcome oral infection. There is much to be said in defense of both. Certainly it is not well to indulge in wholesale, needless senseless extraction of teeth. But one need have little fear of this, because of objections which will be raised by the patient.

The Physician's Position.

The reasons for the attitude of the physician are apparent—he wants the patient to recover health and he therefore wishes to remove every *possible* obstacle to such a recovery. He may have found by experience that very few dentists offer any evidence to prove that they overcome infection when they treat a tooth—and therefore the only way he can feel *certain* that infection will be overcome is to have the teeth extracted.

Elimination of Infection Without Extraction.

I have had the privilege of observing the manner in which Dr. Ottolengui treats cases of infected teeth and dental abscesses and it seems to me a physician has a perfect right to expect some such treatment, and evidence that infection has been overcome, or insist upon extraction.

Dr. Ottolengui's practice is the logical one. He grows bacteria from the abscesses he treats, taking the cultures from the canal and from beyond the end of the root through the canal. He treats the case until he can no longer recover a culture; fills the canals and verifies his canal filling with radiographs. Then—and this is important—makes subsequent radiographs to see what periapical bone changes occur.

While I hope I do not underestimate the value of a tooth, I do believe that in some instances, at least, the physiological value of mastication is overestimated. For example, in the past, the restoration to health of people who had all their teeth removed and false teeth made was attributed to the fact that the false teeth enabled them to masticate their food. If you will recall some of these cases, you will recollect that the restoration to health began to occur usually *before* the false teeth were made and so was very probably due to the elimination of oral infection.

Continuance of Infection After Extraction. While my experience leads me to believe that it seldom occurs, I must grant the possibility of a continuance of infection after removal of an abscessed tooth. There is, therefore, some advantage, and I can see no disadvantage, in practicing currettement after extraction of abscessed teeth. When an abscess cavity persists after extraction of a tooth, it is sometimes due to the fact that the approximating tooth is abscessed—Figure 189.

Pyorrhea. The subject of oral infection due to pyorrhea admits of little discussion. I must say, however, that many cases of pyorrhea are treated where, owing to the amount of bone lost, a cure is impossible. (Figure 204.) It is remarkable, however, what beneficial general effects are produced sometimes by treatment of incurable pyorrhea cases. Perhaps the desirable, beneficial, general effects on cases of arthritis and other systemic diseases is due to the fact that the surgical treatment for the pyorrhea is equivalent to an administration of a bacterine (usually called a vaccine).

When Many Teeth Are to be Extracted Pursuant to this idea of a surgical procedure being equivalent to an injection of a bacterine, Dr. Hartzell has suggested that, in cases for extraction of many infected teeth—i.e. abscessed teeth and teeth affected with pyorrhea—only one or two or a few teeth at a time be removed, at intervals. There will sometimes be an exacerbation of symptoms—i.e., a "reaction"—following surgical treatment, quite similar to the "reaction" following injection of a bacterine.

Treatment of Periapical Infection. There is a fundamental difference in the treatment of dental abscesses today as compared to the way in which they have been treated in the past. Dental abscesses should no longer be treated as a local disease. To state it differently, dentists must cease to treat abscesses and commence to treat *the patient*. In this work of treating the patient the dentist should be willing and anxious to co-operate with the patient's physician. Ever since I can remember, dentists have been crying for physicians to recognize the importance of the mouth. Physicians do recognize the hygienic importance of the mouth now and—is it not true?—dentists are crying because they do.

Naming the methods in order of their effectiveness and reliability, periapical infection may be treated in seven ways: (1) By extraction and currettement. (2) By extraction. (3) By root resection and currettement. (4) By currettement. (5) By Ionization. (6) By forcing

some drug, such as phenolsulphonic acid, 50 per cent., or tincture of iodine, 3 or 4 per cent. in water, through the canal. (7) By sealing volatile drugs in the pulp canal.

The amount of bone destruction governs to a great degree the method to be employed—the more bone destruction there is the more effective the method of disinfection must be. (See Charts C C and D D at the close of Appendix To Chap. VI.) But the amount of bone destruction is only one of the things which governs the treatment indicated. The ability of the operator, the health of the patient, the condition of the other teeth in the mouth, the patient's financial and social standing, the time which can be devoted to the work and other things must also be considered.

Perhaps I will help my reader most by showing radiographs of cases which have been treated, and then let him judge for himself what particular method he will follow in any given case. Before doing so, let me say that, unless a tooth is extracted, the use of post-operative radiographs is an absolute necessity.

Does Bone Regeneration Prove Eradication of Infection.

Later developments in our rapidly growing knowledge regarding oral abscesses may prove me wrong in this, but just now (January, 1917), I *assume* that infection has been overcome if I get a complete bone regeneration in the abscess cavity in about a year. (While, as I say, I *assume* that infection has been overcome in the event mentioned above, I, nevertheless, recognize the lack of definite knowledge on this subject and I would not object strenuously to the removal of such a tooth if it gives any hope whatever of benefiting or curing a very sick patient, and it was the patient's and the patient's physician's desire that the tooth be removed. I might consider the removal of the tooth the "drowning man's grab at a straw" but I would not refuse the one about to drown that last privilege.)

CASES

Fig. 492 A and B.

Abscess upper lateral and central. Particularly bad case on account of bone destruction along sides of roots, which usually indicates an abscess cavity very deep facio-lingually.

Prognosis at time treatment was started: very doubtful.

Treatment: Phenolsulphonic acid, 50 per cent., through apex, out fistula, three times, at intervals of about five days. Dressing in canals during intervals: formo-cresol at times, cresol or creosote at other times. Canal filling: Callahan method.

Result: Secession local symptoms. Fistula closed. No general symptoms. Radiograph, Fig. 492A, made in April. Radiograph, Fig. 492B, made in September, five months later. Fig. 492B shows considerable bone reconstruction. (Operator, Dr. Karl Kayser of Indianapolis.)

Fig. 492A. Abscess upper lateral and central; before treatment.

Fig. 492B. Same case as Fig. 492A, five months after treatment. Note considerable bone reconstruction. Disinfected with phenol-sulphonic acid.

Fig. 493A. Abscess upper lateral incisor; before treatment.

Fig. 493B. Same case as Fig. 493A, five months after treatment. Disinfected with a 4 per cent. solution of tincture of iodin in water. More canal-filling material through end than desirable, but apparently causing no irritation.

Fig. 493 A and B.

Abscess upper lateral incisor.

Prognosis at time treatment was started; good.

Treatment: Four per cent. tincture of iodine in water through apex, three times, at intervals of five days. Dressing in canals during intervals: formo-cresol, cresol or creosote. Canal-filling: Callahan method.

Result: Radiograph, Fig. 493A, made in April. Radiograph, Fig. 493B, made in October, six months later. Fig. 493B shows bone reconstruction in spite of the amount of gutta percha through end. Ex-

Fig. 494A. Abscess lower bicuspid; before treatment.

Fig. 494B. Same case as Fig. 494A, seventeen months after treatment.

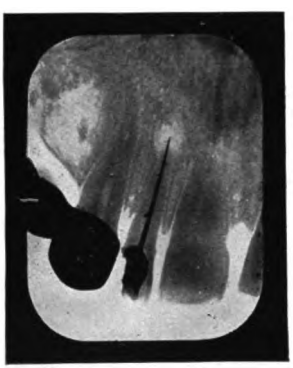

Fig. 495A. Abscess upper lateral incisor; before treatment.

Fig. 495B. Same case as Fig. 495A, ten months after treatment. Disinfected by ionization.

cept following the first injection of iodine there were never any local symptoms. General symptoms: autointoxication, which disappeared after treatment of tooth. Patient gained twenty pounds in three months. (Operator, Dr. Carl Emmert, of Indianapolis.)

Fig. 494 A and B.

Abscess lower second bicuspid.

Prognosis at time treatment was started (judging from appearance of radiograph): fair.

Treatment: Treated from April first to April eighteenth, then filled by Callahan method. Sodium and potassium compound used to sterilize canals. Dressings sealed in canals not known.

Result: Local symptoms subsided, fistula closed. Figure 494A was made April 1, 1915. Radiograph, Fig. 494B, was made in August, 1916,

seventeen months later. Figure 494B shows complete bone reconstruction built in about the root and filling material through the end of the root. (Operator, Dr. A. W. Bark, of New York City. I am indebted to Dr. A. Berger, of New York City, for bringing this case to my attention.)

Fig. 495 A and B.

Abscess upper lateral incisor.

Prognosis at time treatment was started (judging from appearance of radiograph): fair or good.

Treatment: Ionization, 3 per cent. zinc chlorid solution on cotton in pulp chamber, zinc electrode fastened to positive pole against saturated cotton, negative pole, sponge on cheek, one-half milliampere for five minutes. (Patient did not feel current.) Three treatments: first treatment, February eighteenth; second treatment, March eighth, eighteen days later; third treatment, March sixteenth, eight days later. Canals filled March sixteenth.

Fig. 496A. Abscess upper lateral incisor; before treatment.

Fig. 496B. Same case as Fig. 496A, six months after treatment.

Result: Figure 495A was made in February. Figure 495B was made in December, ten months later. Figure 495B shows the abscess cavity entirely filled with new bone. There is considerable canal filling through the end—it is gutta percha. The fistula closed after treatment. (Operator, Dr. Marcus Straussberg, Newark, N. J. Items of Interest, April, 1916.)

Fig. 496 A and B.

Abscess upper lateral incisor, canal not filled.

Prognosis at time it was decided to resect root: considering the nature of the treatment decided upon, excellent.

Treatment: Root resection and curettement, end of canal filled with amalgam. (Filling the end of an unfilled canal with amalgam is especially

advantageous when the tooth has a post crown on it. To the writer, this procedure seems, in most cases, very good practice. If the canal is filled just previous to the root excision it is hardly necessary, for the operator is then sure the canal is filled full. But even when the radiograph shows us a canal filling reaching to the end of the root or to the point where the root is to be cut off, we cannot be sure the canal is filled solid full—hence, the advisability of sealing the end with amalgam. As far as I know, this procedure is original with Dr. C. D. Lucas, of Indianapolis.)

Result: Figure 496A was made in April. Figure 496B was made in October, six months later. Figure 496B shows regeneration of bone. Patient recovered from keratitis within three weeks after operation.

There is a belief among many dentists that the root end is excised because it is rough and therefore a mechanical irritant. A roughened root end is a necrotic, infected root end and, for this reason, it is excised.

I must make the statement, as we consider the matter of bone reconstruction, that I have seen it occur following disinfection of the canals of the tooth and the pus sinus when the canals *were not* filled to the end.

Some Essentials Regarding the Technic of Ionization.

Ionization is a process of introducing drugs into tissue by means of a unidirectional electric current. I take pleasure in recommending the book, "Dental Electro-Therapeutics," by Dr. Ernest Sturidge; publishers, Lea & Febiger, as an authoritative work on this subject. Prinz's "Dental Materia Medica and Therapeutics (Mosby, St. Louis), also carries a fine chapter on this subject.

The process of ionization seems to the writer to hold great possibilities. The principle of its application is illustrated in Figure 497. When some drugs are used; iodine, for example, the polarity must be changed from that indicated in Figure 497.

Figure 498 is an ionization machine. We see the following parts: (1) The main switch, (2) the pole changing control, (3) the rheostat. (4) the milliammeter, (5) the pilot light.

The following are elementary points regarding ionization calculated to help the beginner:

Turning on the current: When connections are all made, advance rheostat slowly. Stop when there is sensation; wait, then advance slowly again. Do not cause pain.

Strength of current: Use anywhere from one-half to five milliamperes.

Time of ionization treatment: About five to ten minutes.

Number of treatments and time of intervals: About three treatments at intervals of about five days.

Turning off the current: Turn the rheostat slowly (not as slowly as it was advanced, however) to avoid pain. Turn current off before removing electrode.

AN IONIZATION REFERENCE CHART.

Drug.	Put the Drug on	Wrist or Indifferent Electrode (*Moisten with water*).
Iodine. (Aqueous solution or equal parts tincture and water or Lugol's Solution.)	Negative Pole.	Positive.
Zinc Chloride. 3% solution in water or a pure zinc electrode with a solution of Sodium Chloride in the canal.	Positive Pole.	Negative Pole.
*Copper Sulphate. 2% solution in water.	Positive.	Negative.
Cocaine Hydrochloride. Any desired strength solution in water.	Positive.	Negative.
$H_2 O_2$ full strength as supplied by pharmacist.	Negative.	Positive.
*Emetine Hydrochloride. 4% in water.	Positive.	Negative.
*Silver Nitrate. 3% in water. Argyrol 20%.	Positive.	Negative.

* Prinz.

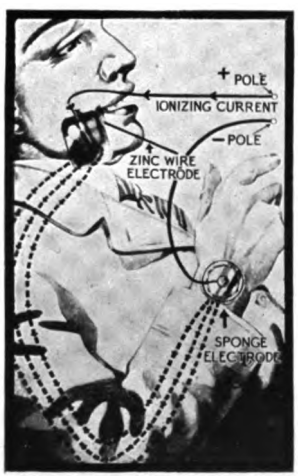

Fig. 497. Illustrating the principle of ionization.



Fig. 498. An ionization machine—wall type.

Some Points Regarding Sterilization and the Practice of Aseptic Pulp Canal Work.

The hands: Scrub with soap and water, then handle nothing but sterilized instruments and accessories. After scrubbing, if it is desired to have the hands more surgically clean, dip in bichloride of mercury solution, 1:1000, then distilled water, then 70 percent. ethyl alcohol.

Instruments: Boiling water for twenty minutes. Two percent. bicarbonate of soda, also two per cent. phenol may be added to water if desired.

Accessories other than instruments should be sterilized in a steam sterilizer, which admits of turning the steam into or out of the sterilizing chamber. The technic for the use of such a sterilizer consists first, of course, in placing the articles to be sterilized in the sterilizing chamber: Heat for about twenty minutes before the steam is turned into the sterilizing chamber. Turn steam into chamber for thirty minutes. Turn steam out of sterilizing chamber, leaving heat on for about twenty minutes. This dries the sterilized articles. (The Wilmot Castle Company, Rochester, N. Y., makes steam sterilizer of the type the writer has in mind.)

Napkins and linens of all sorts, paper canal points, cotton, cotton sponges of all sizes: Wrap in gauze or unbleached muslin, pin shut, sterilize in steam. Do not open packages until ready to use.

Rubber Dam: Cut, lay between layers of muslin, sterilize in steam. Paint after its adjustment with 70 per cent. alcohol, painting the teeth included in the dam adjustment. Tincture of iodin may be used also if desired.

Cotton Swabs on Broaches: By using a broach holder for the dental engine, a great number of smooth broaches may be nicely wrapped with the desired amount of cotton, then sterilized with steam. Wrap in muslin, sterilize, then open wrapping only when ready to use.

Gutta-Percha Points: May be sterilized in steam. Do not allow the points to touch one another when subjected to the heat or they will stick together. Keep in 70 per cent. alcohol.

After sterilization, it is expedient to keep all pulp canal paraphernalia in a formaldehyde " sterilizer " (?) or case where nothing else is kept.

Dr. Best's Charts.

In further consideration of the matter of asepsis and infection, a perusal of Dr. Best's Charts VI and VII will prove to be instructive.

CHART VI

PROBABLE CAUSES OF PERIAPICAL ABSCESSES

1. USE OF ARSENIC
2. NOT USING RUBBER DAM
3. SEALING DRESSINGS WITH COTTON OR POROUS CEMENTS
4. NOT REMOVING ALL DECAY FROM THE CAVITY
5. NOT CLEANSING THE FIELD OF OPERATION
6. USE OF UNCLEAN CHIP BLOWERS IN PULP CANALS
7. USE OF NON-STERILE COTTON FROM EXPOSED COTTON HOLDERS
8. WRAPPING COTTON ON SMOOTH BROACHES WITH UNCLEAN HANDS IMMEDIATELY BEFORE PLACING IN THE CANAL
9. NOT USING CLEAN INSTRUMENTS STERILIZED IMMEDIATELY BEFORE USING
10. SEALING IN AS DRESSINGS, IRRITATING AND TISSUE-DESTROYING DRUGS
11. LEAVING IN THE CANALS NON-VITAL PULP TISSUE
12. FORCING INSTRUMENTS AND DRUGS THRU THE APEX
13. NOT REMOVING ALL THE MOISTURE FROM THE CANALS
14. NOT FILLING CANALS TO APEX
15. USE OF MEDICATED CANAL PASTES WHICH DESTROY PERIAPICAL TISSUE
16. NOT SEALING CANALS UPON COMPLETION OF FILLING
17. PAYING LITTLE OR NO ATTENTION TO ASEPSIS

CHART 6

CHART VII

HOW TO AVOID PERIAPICAL ABSCESSES

1. USE OF ANESTHETICS (LOCAL)
2. USE OF RUBBER DAM
3. SEALING DRESSINGS WITH COMBINATION OF CEMENT AND GUTTA PERCHA
4. THOROUGH REMOVAL OF ALL DECAY FROM THE CAVITY
5. LIBERAL APPLICATION OF IODINE AND ALCOHOL TO FIELD OF OPERATION
6. USE OF FILTERED COMPRESSED AIR
7. USE OF STERILE COTTON
8. USE OF STERILE DRESSING BRISTLES AND CANAL POINTS
9. STERILIZATION OF ALL INSTRUMENTS IMMEDIATELY BEFORE USING
10. USE OF NON-IRRITATING DRUGS AS DRESSINGS
11. THOROUGH REMOVAL OF ALL ORGANIC TISSUE
12. CAREFUL ROENTGEN EXAMINATION OF THE TOOTH INCLUDING MEASUREMENT WIRES
13. PROPER GUIDANCE AND CARE IN HANDLING INSTRUMENTS AND DRUGS IN CANALS
14. HAVING CANALS DRY TO APEX BEFORE FILLING
15. SEALING GRANULA AND FILLING CANALS WITH INERT INSOLUBLE NON-IRRITATING SUBSTANCE
16. SEALING CANALS FLUSH WITH FLOOR OF PULP CHAMBER WITH OXY-CHLORIDE OF ZINC CEMENT
17. MAINTENANCE OF ASEPSIS DURING THE OPERATION

CHART 7

Chart VI. "In case we have been guilty of any of these conditions, we have contributed our share to the great number of infected pulpless teeth. Arsenic is dangerous and unnecessary. Periapical tissues are frequently destroyed by powerful drugs sealed in canals, and these areas may become the seat of infection of secondary origin, hemotogenous origin." Dr. Elmer S. Best.

Chart VII. "Contains some practical hints which will assist us in having more satisfactory results with our operation. In dental surgery, where we come in contact with the patient's system, the same principles apply as in surgery." Dr. Elmer S. Best.

Some Essentials Regarding Technic of Inoculating Culture Media from the Canals of Teeth

Recommend little book, "Laboratory Methods," by Williams & Williams (Mosby, St. Louis).

Culture media can be purchased from Parke, Davis & Company, and other reliable manufacturers of biologic preparations. Suggested media: Ascites dextrose agar and dextrose bullion.

Technic: (1) Flame platinum inoculating needle. (2) Insert platinum needle in canal of tooth. (3) Remove needle from tooth. (4) Flame cotton in mouth of culture tube. (5) Remove cotton. (6) Flame mouth of culture tube. (7) Make plant in culture with needle. Avoid touching sides of culture tube with needle. (8) Flame mouth of culture

tube. (9) Flame cotton. (10) Reinsert cotton in tube. (11) Flame cotton. (12) Within an hour, place tube in incubator.

An electric incubator 9 x 9 x 12 inches (inside dimensions), suitable for dental use, can be obtained from The Chicago Surgical and Electrical Company, Chicago, Illinois.

The incubator temperature should be about 37½° C. A growth will usually occur, if at all, in from forty-eight to seventy-two hours.

The matter of examining cultures and determining the nature of the organism, obviously, cannot be considered here. If possible, this work should be turned over to an expert laboratory man.

Fig. 499A. Three apical foramina in lower bicuspid filled by the Callahan method.

The Technic of Opening and Filling Pulp Canals

Certainly it is not out of place to include in this chapter something regarding pulp canal technic.

No man in the world is better fitted to describe this technic than Dr. John Callahan, of Cincinnati, who has generously granted me permission to print the following two papers by him: one, "Root Canal Preparation"; the other, "Root Canal Filling."

Figure 499A is a radiograph of a lower bicuspid. It shows the main canal branching, at the apex, into three. All three of these small canals and apical foramina are filled. As far as I know, this can be done only by the Callahan method.

Root Canal Preparation.

By J. R. CALLAHAN, D.D.S., Cincinnati, Ohio

It is certain that much may be judiciously argued in favor of the drill, or of chemical and mechanical treatment for root preparation, and there is something to be said against each agent or combination of agents, and that is what, on the present occasion, I have to say.

To state one argument is not necessarily to be deaf to all others, and that a man has written a book of travels in Russia is no reason why he should never have been in Africa.

Whether it be a tooth from which a devitalized pulp is to be removed after arsenical application or pressure anaesthesia, or the opening and cleansing of a pulp canal that shows a moist or dry gangrenous tissue, or any or more of the numerous pathological pulp condition or conditions beyond the root end, the goal, the strategic point, is the apical foramen or foramina: foramina in ninety per cent. of adult teeth.

It is then the duty of the operator to obtain a sterile and as direct and as free a passage to the strategic point as the nature of the root canal will permit. It does not meet the present day requirements to say, as do some of our text books and essayists, " open the root canals to the end." Our inquiry is, how is this seemingly simple little thing to be done?

To undertake the opening and preparation of a root canal should indicate that the dentist recognizes the necessity for removing every atom of devitalized tissue, having the canal throughout its entire length and in all of its ramifications, including the dentinal tubuli sterile and in such shape and condition that the canals, the tubuli, the foramina may be permanently sealed or filled.

Diagnosis, filling of canals or treatment of conditions around and about the root, are not to be discussed further than may be necessary to make clear the reasons for certain steps to be mentioned.

The dentist should on every possible occasion avail himself of the advantage to be obtained through having one or several radiographs before him for comparison or study. We cannot be reasonably sure of the effectiveness of our efforts without such assistance, nor can we be absolutely certain with them. Many of the pictures thrown on the screens and printed in our journals as evidence of perfect technic and results are about as clear as rabbit tracks in the snow on a windy day, when it is a difficult matter to determine whether brother rabbit is going or coming, the strategic point being conspicuously absent. Improved apparatus and technic will some day overcome these shortcomings. Inasmuch as the largest number of dentists are for one reason or another deprived of the

valuable assistance of the X-ray, and our literature is being surcharged with most accurate information in this line, let us then on the present occasion keep in mind the great majority who get along the best way possible without this expensive adjunct.

Aseptic Operation Recommended.

All operations upon the root canal from beginning to completion are purely surgical and should be conducted upon surgical principals; this being true, the maintenance of aseptic conditions is of first importance.

Radiated heat and superheated steam in combination is the only acceptable method for the sterilization of instruments, cotton, paper points, gutta-percha points, etc.

Steam chests that are best adapted to this use are known as the Pentz System, made by the Santiseptic Manufacturing Co., Tompkinsville, N. Y., and a double chambered steam chest made by the Wilmot Castle Co., of Rochester, N. Y.

Opening into Pulp Chamber.

The opening of the pulp chamber should be accomplished with as little disturbance of the devitalized pulp tissue as may be possible: to this end it will be well to cut through the dentin with a drill, then use carborundum disks and stones, keeping the carborundum stones moistened with water that contains a liberal supply of carborundum powder. This enables the stone to cut rapidly without heating the tooth.

Better results will be obtained if, while using the stones and carborundum powder, all of the tooth crown be removed that interferes with pulp chamber enlargements that may be necessary in getting direct access to the end of the root.

Sufficient enamel and dentin having been removed to give a clear view of the pulp chamber, it will be well to prepare for the placing of the rubber dam, by means of threads, fine polishing strips, separators or by whatever means necessary to insure the dam going to place with little or no forcing. There should be no leakage whatever about any of the teeth included in the field of operation.

Copper Band to Facilitate Use of Rubber Dam.

If the cavity margin reaches to or below the gum line then a copper band should be fitted and cemented to place about that tooth, so that the dam and clamp can be placed upon or over the band and tooth without danger of displacing the band.*

*It will sometimes be practical to put the rubber dam clamp on the tooth posterior to the one with the band on it and bring the dam forward to include the banded tooth.—H. R. R.

Removal of Pulp

The dam being in place, bathe the exposed teeth, rubber dam and clamp, etc., with a seventy per cent. alcohol solution or tinct. iodine. This strength of alcohol is a more effective germicide than the ninety-five per cent. generally used. With warm air dry the cavity: with small fissure drill make a circular cut, leaving a cap of dentin over the pulp chamber which may be removed by a blast of air or a fine excavator. Having exposed the pulp it will in many cases be well to toughen or harden the pulp tissue by placing a drop of alcohol and formalin (about five per cent. formalin) on the devitalized pulp for a few minutes. Then with hot air dry the pulp, when a fine broach is passed alongside the pulp or largest branch of the pulp. Slightly turning or rotating the broach and withdrawing the broach, will in many cases bring the entire pulp, including the smaller branches of molar pulps.

Every possible effort should be made to get the entire pulp at the first trial. The extracted pulp should be spread on white paper and examined with a magnifying glass that the operator may know the location of pulp fragments if there be any.

Cleansing Canals.

The three methods of procedure, from this point, that we wish to discuss briefly are: the drill, the sodium-potassium, and the sulfuric acid and soda bicarbonate.

The open chamber and canals should first be washed out with normal saline solution; dry, then place shred of cotton saturated with clove-oil well within the large or open canal to remain while we go in search of the very minute canals that may be so small that it is a difficult matter to find them.

Use of Canal Drills.

Paint the floor of the pulp chamber with tincture of iodine. When the surplus iodine is absorbed by a cotton pellet, little dark spots will, in most cases, reveal the location of the canals. The finest Kerr drill, manipulated by hand, without pressure, will enter a very fine canal by gently rotating the drill, and being very delicate and flexible and threaded like a screw, will in most cases bring away the remaining pulp tissue, when the canal may be enlarged by gradually increasing the size of drills, or the drills may be worked in and out of the canals as files.

These flexible drills will go around a slight curve if the canal is large enough to give the instrument free play. If the instrument binds, at or near the curvature, a false pocket will be made on the outer wall of the canal at the curve. The little pocket or pit in the dentin, at the point indicated, prevents further instrumentation within that canal.

Each and every root canal is more or less of a law unto itself. A correct radiograph is of inestimable value. In the absence of the X-ray picture, the operator will be greatly assisted by making a pencil sketch of the probable shape of the tooth. In this way his memory will be refreshed and he will be made more keen and alert as to the probable difficulties ahead.

In some cases it may be of advantage to sink a shaft in the root using a bud drill, following the fine canal from a third to a half the length of the root, following the canal from this point with the fine flexible drill.

By being patient and careful many of the finer canals may be opened to the foramen.

It is possible, however, that septic matter or pulp fragments that may become septic, have been forced through the foramen into the apical space.

It is not possible that the multiple foramina, or the collateral canals, or the connecting canals or the flat thin cancellous spaces between the main canals in double roots have in any sense been opened or cleansed.

The drills in many such roots have simply drilled holes through organic substance in various stages of disintegration. Such substances cannot be washed or swabbed out but are left within the canal, sometimes saturated with such antispetic medicaments as may be applied, and finally incorporated with the root canal filling.

Sodium-Potassium Method of Cleansing Canals.

Schrier's kalium-natrium, or sodium-potassium, as we more frequently name it, is a concentrated alkali caustic; explosive when in contact with water, yet a most useful agent when carefully and skillfully handled, for the purpose of removing organic substance from root canals. It is also a useful adjunct for opening and enlarging root canals after the manner advocated by Drs. Rhein and Ottolengui.

If the dentist will moisten a spot of skin on the back of his own hand and place thereon a small particle of sodium-potassium he will realize at once the necessity of giving close attention to the protection of the patient, including the nostrils, which should be protected in some way.

All the pulp tissue that is within reach of the broaches having been removed, small particles of the sodium-potassium, size of a pin head if placed where the very fine canals should be, the dentin being moist will, by dissolving the organic substance, reveal the elusive anterior canals of lower molars or buccal canals of upper molars. These canals after being

located and having been exposed to the action of the sodium-potassium for a few minutes, should be attacked with what has been named " picks," Dr. Rhein having devised a very sufficient instrument under this name. An instrument will be illustrated later that has the advantage of being more rigid and also having interchangeable points.

These picks, with assistance of the sodium-potassium, which breaks down the organic matrix of the dentin, converting it into a soapy-like mass, which acts as a lubricant, will work their way into the canal, enlarging and sterilizing in a most satisfactory manner.

After advancing a distance into the canal, if the pick begins to bind or lock, thereby becoming a piston within the canal, a large Gates-Glidden drill, from which the point has been ground, may be used to enlarge the lumen of the canal so that the pick may work more freely.

When having reached the region of a curve in the canal or a near approach to the foramen, it will be safer to use a finer instrument, a Donaldson broach, from which the barbs have been partially removed, for the purpose of negotiating the curve if possible; also to eliminate as much as possible the piston effect of the larger instrument that might force the caustic contents of the canal into the region beyond the foramen, and do damage that will be difficult to control.

I have had two severe burns in my practice from this cause. In one case the tooth had to be extracted, and the second one I fear will be lost.

Caustics. Chemical substances which cause death and degeneration of tissues are called caustics.

Alkalies, such as sodium-potassium and calcium.

Acids, such as hydrochloric, sulfuric, nitric, arsenius and carbolic, and the salts of some metals, such as silver nitrate, zinc chloride, copper sulphate, are the most common types of caustics.

The alkalies and metallic salts act by uniting with the albumins, acting as albumin solvents.

" The caustic alkalies are not self-limiting: they penetrate deeply into the tissues and destroy the albumin of the mucous surfaces, the horny tissues and the external skin."

Necrosis, followed by eschar formation, is caused by strong caustics, the necrosis involving tissues at various depths, depending upon the strength of the caustic, the nature or mode of its action, and the time it is allowed to act.

" Those agents are best suited by cauterization which, like concentrated sulfuric and fuming nitric acid and silver nitrate, penetrate to

the deeper layers of the skin and mucous membrane only after acting for *some time.*"

The treatment of chemical injuries, of *recent cases,* should be directed toward neutralization of the agent before it penetrates deeply.

Chemists and apothecaries usually have two solutions ready. Acetic acid or vinegar is used to neutralize the alkalies, while a solution of sodium bicarbonate is used to neutralize the acids.

If, for any reason, it is suspected that sodium-potassium has passed beyond the foramen, a sulfuric acid solution should be applied quickly followed by soda bicarbonate solution.

I have no doubt that through some of the large foramina, at least, the caustic has wrought harm.

In the constricted canals and in the constricted apical region the use of sodium-potassium is frequently indicated. The dangerous qualities of a valuable agent should not cause us to overlook its useful qualities.

Sulfuric Acid Method of Cleansing Canals.

Twenty years ago sulfuric acid solution and soda bicarbonate solution came into use.*

The sulfuric acid is used for the purpose of softening the surface of the pulp canal walls to permit the passage of the barbed or roughened broaches to and fro through the canal, enlarging the canal by breaking loose the softened dentin. Soda bicarbonate solution is thereupon injected into the canal that the broken down dentin and other disorganized substances may be removed from the canal by effervescence caused by the escape of carbonic acid gas that is the product of the neutralizing action of the soda bicarb. upon the sulfuric acid.

This reaction leaves the canal in a state of surgical cleanliness. This cannot, to my knowledge, be said of any other method or agent.

Twenty years is a long time for a method or theory to stand practically unaltered. Notwithstanding the age of the so-called sulfuric acid treatment (which might much better have been entitled, "Sulfuric acid and soda bicarb. treatment"), a brief résumé of the theory and practice of the doctrine may not be amiss.

Concentrated sulfuric acid is also an active escharotic. The acid caustics act by burning the structure with which they come in contact.

They not only disintegrate albumen but attack many other organic substances. The breaking up of inorganic and the carbonization of organic substances is to be borne in mind.

Limited and mild caustics when applied cause an inflammatory action, depending upon the strength and time of application.

---

* Given to the profession by Dr. Callahan.—Ed.

A fifty per cent. (by volume) solution of sulfuric acid will soften cotton on the carrying instrument. A weak acid solution gives a correspondingly weak reaction in the presence of the soda solution.

The strength of the acid solution should be not less than twenty per cent. and not above forty per cent. for root canal work. In my own practice thirty per cent. to forty per cent. aqueous solution or commercial sulfuric acid by volume is the standard.

Soda bicarbonate should be a saturated solution.

In relation to the action of the acid solution on bone tissue, Mr. George Pollack, F. R. C. S., Surgeon to St. George's Hospital, says: "Dilute sulfuric acid does not affect the living, acting chemically on diseased bone alone." He gives the following experiments: "Portions of dead, diseased and healthy bone were selected and subjected to the action of sulfuric acid,"

viz.: No. 1. Dead bone..... 10 grains
2. Diseased bone ..... 10 grains
3. Healthy bone (middle age).. 10 grains
4. Healthy bone (old age)..... 10 grains

"Exposed to the action of a mixture of sulfuric acid and water one part in four, for three days, at a temperature of one hundred deg., the following were the results:

No. 1. Dead bone, phosphate of lime 2 grs. Carbonate of lime 3.3 grs. dissolved in the mixture.

No. 2. Diseased bone, phosphate of lime 2 grs. Carbonate of lime 1.3 grs. dissolved in the mixture.

Nos. 3 and 4. In both specimens of healthy bone no action took place."

Dr. Garretson, in the treatment of caries of the maxilla, recommends the use of the officinal ordinary sulfuric acid.

On the diseased or partially disorganized soft tissues the solution will have a corrosive and astringent effect, or in other words, will break down or destroy the diseased tissue, leaving a fresh, clear field for nature, with the assistance of mild antiseptic treatment, to take care of herself.

Why does not sulfuric acid attack and destroy divitalized dentin? The acid at first attacks the tooth substance, breaking down the lime-salts, at the same time corroding or carbonizing the organic substance, forming a new compound, thereby establishing a barrier to the further progress of the acid.

Prof. Cassidy, see *Dental Chemistry and Materia Medica*, says: "The acid attacks the earthy portion forming insoluble calcium sulphate (Ca So4), at the same time dehydrating the animal or gelatinous portion, which is mainly made up of carbon, hydrogen and oxygen. These two

latter elements are withdrawn as already alluded to, leaving the indestructible carbon as a residue to be incorporated with the insoluble sulphate, producing thus, a protecting covering to the unaffected parts beneath, against further inroads of the causing agents."

This protecting covering of carbon and calcium carbonate are removed or scraped away by each excursion of the rough broach, permitting the acid to take another bite at the dentin.

The same chemical and mechanical action is repeated so long as the broach is kept in motion in the presence of the acid solution.

The depth to which the acid affects the dentin is, unfortunately, immeasurably small.

It would be a great advantage to the work in hand if the acid would or could be made to penetrate further into the dentin. The reason why a larger area of the dentin is not at once affected has already been mentioned. It may be well to recall, however, that dentin consists of an organic matrix, a reticular tissue of fine fibrils richly impregnated with salts of calcium. Traversing the matrix are long, fine canals or tubes, the dentinal tubules, twenty-five to thirty thousand to the square millimeter. Immediately surrounding the tubules the matrix is especially dense, forming a lining or sheath to the tubes, known as the dentinal sheaths or Neuman's sheaths. Neuman's sheaths are insoluble in boiling sulfuric acid.

Method of Applying Acid in Canals.

Sulfuric acid causes delicate steel instruments to become brittle and to break on small provocation, leaving small pieces of steel buried within the canal. This unpleasant accident is, as a rule, due to the manner of manipulating the broach.

For very fine canals the barbs should be partially or wholly removed from the broach or a fine broach can be made from gauge twenty to twenty-five piano wire. These broaches should be cut to proper lengths and placed in a rigid holder or handle that will hold the broach in a direct line with the line of force. Either pressure or traction may be applied to the delicate steel point. For the heavier work, digging or enlarging should be done with larger and stronger points, made of roughened steel A better and safer instrument may be made by taking the largest tantalum silicate plugger points, No. 104 or 105 S. S. W., bend to straight line, remove from the handle, file or grind to proper shape, and place in the strong right-angle broach holder made of ivory. This makes a most effective root and canal excavator.

The metal is not acted upon or altered in any way by acids. This manner of enlarging or excavating the canal to a large extent at least

eliminates the probability of making a false tract or pocket within the canal, and does away with the necessity of using a drill, at least, until the canal is large enough to make drilling a safe procedure.

The point that I am trying to develop is that I believe that the best results are to be obtained by eliminating the undesirable or dangerous, and taking advantage of the safer and desirable features and results, that may be obtained through the use or application of every chemical agent or instrument that will meet the exigencies of the case in hand.

In straight and sufficiently open canals or in canals that have been enlarged by chemical means to a sufficient size to pilot the root drill, for the sake of speed, for convenience in shaping of canal, a Kerr drill, or a Gates-Glidden, from which the point has been ground, or bud drill, may be used.

If the finer canals contain fairly well organized pulp tissue that the broach fails to engage, sodium-potassium should be applied. After the pulp or other organic tissue has been converted into a soapy substance, the removal of this soap from the canal becomes a necessity; some of it may be removed with a stream of water; only a small proportion, however. Swabbing with cotton on a broach does but little better. If the root canals of an extracted tooth be opened and thoroughly treated with sodium-potassium, the canals then washed out with water as would be done if the tooth were in the mouth, and if you then dry the tooth and crack open the roots, in the apical third or the root canal a dark, rather dense, soapy mass will be found packed within the fine canal. If the tooth fragments be kept dry for a day or so the dentin will show a greenish yellow color—not a very pronounced discoloration, but sufficient to show the presence of a coloring matter. All of this soapy mass will be thoroughly removed from the canal, if sulfuric acid be pumped into the canal in sufficient quantities to overcome the alkali, and having been worked to the end of the canal with broach, then the root canal be flooded with a saturated solution of soda bicarbonate. The reaction will at once remove practically all foreign substance from the canal. If the tooth then be dried and the roots cracked open the canals show white and clean as marble.

With the tantulum root excavator and sulfuric acid the root canal may be enlarged more rapidly and with greater freedom from unpleasant and sometimes dangerous conditions. The acid destroys and breaks down disorganized organic tissue, the soda solution removing the débris without forcing the disorganized substance through an open foramen, as many dentists seem to fear.

If acid solution be placed in a small glass tube, and you then pour

the soda solution into the tube, it will be seen that chemical action is all on top of the acid, or only on the surface of acid exposed to the soda; or, in other words, it does not react in the form of an explosion, the

Fig. 499. Copper band cemented on tooth to facilitate the placing of rubber dam where the cavity extends below the gum margin.

Fig. 500. Showing curvature of buccal roots of upper molar.

larger end of the canal being open and offering no resistance to the gas. If the acid solution should pass through the foramen no further reaction could take place than that of irritation, as is shown in Fig. 505.

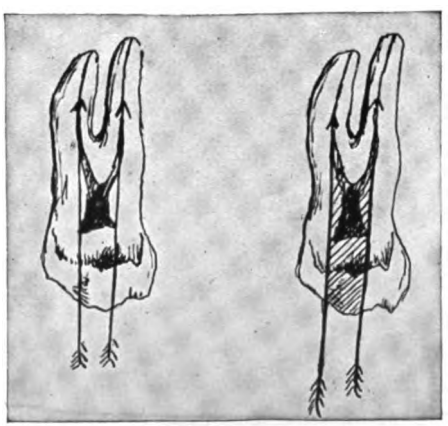

Fig. 501. Shows amount of tooth structure to be removed to get as nearly as possible in a straight line with the foramen.

Fig. 502. Showing curvature of roots of lower molar.

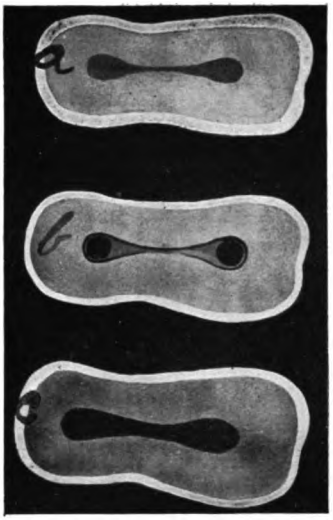

Fig. 504. Transverse sections of large flat root. *A*. Canal filled with disorganized pulp tissue. *B*. Attempt to clean canal with drills and broaches often digs a passageway through the disorganized canal contents. *C*. By chemical methods every vestige of organic tissue may be removed.



Fig. 505. *B*. Self-limiting action of sulphuric acid solution on cancelous bone tissue. *A*. Action of sodium potassium on same bone.

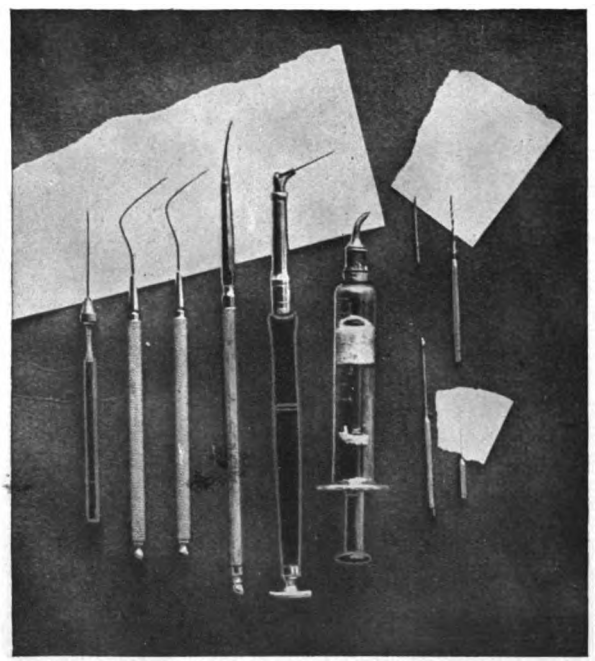

Fig. 506. Some instruments used for the opening of root canals.

Root Canals Filling.

By Dr. J. R. Callahan, Cincinnati, Ohio

Colophony, resin, commonly known as rosin, is obtained from turpentine by distillation. In the process the oil of turpentine comes over and the rosin remains behind. Rosin varies in color from dark red-brown to black and white, according to its purity, and the degree of heat used in its preparation. Chemically, it is the anhydrid of abietic acid. It has the physical and chemical properties common to all rosins. It softens at 176 degrees F. and fuses completely at 275 degrees F., is insoluble in water; with difficulty is soluble in alcohol; freely soluble in chloroform, acetone, benzone, and fatty oils.

The rosin that is best adapted to dental uses that I have been able to find is that prepared by Barnardel for the use of the violinist. It is a French preparation, very near the color of dentin. The formula, as given below, makes a very thin solution. It required a long time for me to realize the advantage in the use of a thin solution. A thick mixture will not pentrate the tubules, nor does it give up enough chloroform to dissolve the gutta-percha:

℞ Rosin ..... gr. xii
Chloroform ..... ʒiij
℥ Ft. sol.

Anatomy of Dentin.

As we are to deal with dentin that has been subjected to infection, a brief rehearsal of the histological anatomy of dentin will aid us in getting our mental eyes in the same focus.

Arthur Hopewell Smith, in his late book, "*An Introduction to Dental Anatomy and Physiology*," says:

"The functions of dentin are to give substance to the tooth itself; to provide a centre of sensation; to protect the pulp. Enamel is without the pale of nutrition. The pulp is highly vitalized and the dentin is on the borderline of the living and the dead: semi-vitalized, if one may so speak.

"Nature would not for a moment tolerate the presence in the midst of living tissues of a dead body like enamel. The result is therefore the presence between the living pulp and the inert enamel, of a large area, relatively speaking, of a tissue which is marvelous and unique. In no other part of the body do we find an entirely tubular structure like dentin. Its peripheral parts where it joins the inorganic enamel and cementum

are less vitalized than in central parts. This explains the reason why the dental tubules are not of the same caliber throughout their lengths. They vary from 1.7 to 5 m. The diameter of the tube diminishes as it proceeds outward, until at the peripheral region of the tooth it becomes immeasurable. The dentin of the crown of teeth is more plentifully supplied with living material (protoplasm) than the roots; hence the tubes branch more frequently in the latter than in the former situation. The tubes carry the dentinal fibrils; that is, the peripheral poles of the odontoblasts."

It is through these dentinal fibrils that nervous stimuli are transmitted to the pulp. Following the teachings of Miller and Black in the study of carious dentin, we note among other interesting things that caries progress along the lines of the dentinal tubuli; that the form of the disintegrated dentin is that of a cone with the apex toward the pulp chamber, and that the dentin is decalcified in advance of the penetration of the micro-organisms.

It is not likely that in the preparation of cavities we always remove the apex of the affected dentin. In deep-seated cavities is this advisable? In spite of the application of strong antiseptic agents, recurrent decay may develop and toxins finally reach the pulp.

Advantages of Rosin.

If the remaining traces of thin layers of decayed dentin can be thoroughly dehydrated, the application of rosin solution may be of great service.

First, rosin being more or less a non-conductor, it reduces the shock of thermal changes.

We are taught that the decalcified dentin that is to be found just in advance of the micro-organisms in carious dentin furnishes food for the invading germs. If the remaining decalcified dentin be saturated with rosin, I imagine the cost of living in that region will become prohibitive. However, if the rosin solution reaches the farthest boundaries of the decalcified dentin through the infected area, then the micro-organisms within the tubuli will have been engulfed within the rosin solution, and unless the bacteria are able to liquify the rosin, they will be forever inhibited from further activity, be they aerobic or anaerobic, in active or spore form. I need only mention the antiseptic properties of the chloroform.

This, you will admit, would be a very desirable condition in which to have a layer of decayed or decalcified dentin over the pulp, where the removal of the layer of decay would mean the exposure of the pulp.

The most satisfactory results that I have had in capping pulps has

been a flow of rosin solution over the exposure, evaporating the chloroform with warm air, then to cause a very thin cement to flow over the floor of the cavity and the thin coat of rosin and allow it to harden, being very careful to avoid pressure of any kind on the cement until quite hard.

This practice has been confined to quite small and recent exposures. Not the least satisfactory use of the rosin solution is after more or less thorough drying of the cavity and application of the rosin prior to the insertion of gutta-percha filling, either as a temporary or permanent filling.

On the removal of a temporary stopping of this nature, that has been in place a week or a month, the decayed dentin, which for any reason may have been left in the cavity, will be found noticeably tough and hard and dry, due to the presence of the rosin, and the sensibility of the dentin will be materially less, showing that the dentin has been free from the irritating effects of acids, or, in other words, the fibrils have been in a state of comparative rest. And after all is said, the chief function of the surgeon is to remove the irritant and place the affected region at rest, to the end that Nature may perform a cure.

Root Canal Filling.

We now come to the consideration of the time-worn subject of root-canal filling.

If possible, is it desirable or necessary that the tubuli be sealed?

Dr. Hermann Prinz, whom I regard as one of the foremost among our scientific research workers, said in a paper read before the St. Louis Dental Society, September 2, 1912: "If the canal is not filled perfectly, serum will seep into it from the apical tissues. The serum furnishes nutrient material for the micro-organisms present in the tubuli of a primarily infected root canal."

Multiple Foramina.

The dentin is traversed by dentinal tubuli, which number from 25,000 to 30,000 to the square millimeter. The pulp in situ sends protoplasmic processes into these tubuli, and is connected with the peripheral tissues by arteries, veins and nerves which pass through the main foramen and a number of small foramina (usually 2-7) present in the apex of the tooth. According to Fischer, these accessory foramina are found in about ninety per cent. of all permanent teeth. These anotomic facts are not sufficiently emphasized at present. Their significance is of great importance for the full comprehension of the pathology of secondary infection.

In an incipiently infected root canal, these dentinal tubuli and the small foramina offer ready hiding-places for various forms of pathogenic bacteria.

Action of Bacteria.

After exhausting the nutrient material, the bacteria become attenuated, or they assume resting forms. If the tubuli and the foramina are tightly sealed, these enclosed bacteria must necessarily remain permanently confined in their lodging places, while if the root canal filling leaks, the seepage of serum furnishes fresh material which offers excellent opportunity for their renewed activities.

By continuity this secondary infection spreads along the lines of least resistance, *i. e.*, toward the apex, and finally reaches the pericementum. This tissue protects itself against the invading foe by a reactive inflammation, which results in the production of a fungus growth known as a granuloma, or in the past, as the abscess sack of pyogenic membrane.

For years the enclosed bacteria may remain dormant. At the slightest provocation, however, overexertion, a cold, increased blood pressure, lowered vitality, or some other cause, they may assume a most virulent activity, resulting in the production of the so-called subacute abscess. Based upon this supposition we are able to furnish a plausible explanation of how these obscure secondary abscesses occur about the devitalized teeth which at one time were pronounced cured.

In one of the most profound papers given to the dental profession on mouth infection, Dr. Rhein says: "Unfortunately, as a profession we must admit that most of the cases of blind abscess are the results of imperfect dental operations. In some cases they may be the result of bad judgment on the part of the operator; in others they may be due to ignorance and incompetence, but a very large number of cases are attributable to the failure of the educated dentist to give the time needed to perform an aseptic operation and have the field absolutely free from the possibility of future infection. This is absolutely nothing short of malpractice when done by a dentist who knows."

We have the testimony of several investigators to the effect that it is possible to sterilize the root canal proper, but it is an impossibility to sterilize the infected dentin of a tooth while it remains in the mouth.

The microscope and the culture media have shown us conclusively that we have been, and are now, leaving enormous numbers of microorganisms within the body with a more or less available route open to the circulatory system where they may reach any part of the body, carrying destruction to those organs or parts that may offer the most attractive lodging place.

A most significant fact must be borne in mind in regard to the devitalized dentin. We have no blood current to assist in the struggle. The dentin has aboslutely no power even to assist in repair. No granulation

nor scar tissue—nothing but an inert tubular mass infected by millions of toxin-producing micro-organisms. We must make of this infected tubular mass an inert, harmless and stable body, including the effective closing of the numerous foramina, to the end that Nature may be able to develop the root mass in a healthy and vigorous peridental membrane that the tooth may serve its several useful purposes for a number of years.

Requirements of Root Canal Filling.

Most of us have at one time or another shared in the opinion that what the root canal might be filled with mattered but little.

The radiograph in the hands of the advanced dental practitioner has brought to light evidence sufficient to prove the fallacy of such an opinion. It does matter as to the material; it does matter as to the manner of placing the material in the canal. The matter of prime importance is the sealing of the more or less numerous foramina, and, as we have no assurance that all the foramina in a given root canal are located near the apex, it becomes our duty to seal the whole length of each canal with a material that will search out and seal minute canals or openings which, owing to physical conditions, we are unable to see.

Gutta-Percha Root Fillings.

Have we a root canal filling material that will meet the requirements indicated above? We have three that may be considered. Gutta-percha and chloro-percha in combination; paraffin, as advocated by Dr. Hermann Prinz and Dr. Dunning, and the combination of rosin and gutta-percha. With the gutta-percha cone and chloro-percha you are quite familiar. We know of many successes as well as of the many unhappy failures with this root filling, sometimes due to faulty manipulation, but often due to the fact that the root canal filling has shrunken sufficiently to admit body fluids to the canal, or permit egress of the micro-organisms that infested the tubuli, and in addition the gutta-percha root fillings are often found to be saturated with decomposed and odoriferous substances that we are altogether too familiar with.

Paraffin Root Fillings.

The paraffin root canal filling, as advocated by Dr. Prinz and Dr. Dunning, has many attractive features, and time may prove it a most, if not the most acceptable root filling. I have not always succeeded in getting the paraffin to the apex of the roots of upper teeth. If the wire is too hot the paraffin will collect about the shank of the instrument, and if not hot enough it does not flow to all parts of the canal. The melted paraffin will, however, follow the paraffin oil into the tubuli

and foramina if treated porperly. It will take time to prove its permanence with the body. Our previous experiences and the experiences of the surgeon have made us a litle shy on this point.

Rosin and Gutta-Percha Root Fillings.

The technic of the rosin-gutta-percha root filling is simple, easy, quick, and sure to seal all tubuli and foramina *that are open.* Before proceeding with the filling of the root canal, all instruments, cotton-paper points, gutta-percha points, should be placed in the steam chest, superheated steam being the most effective sterilizing agent. After steaming the proper length of time, the steam is shut off from the chest. This soon dries the instruments and points and cotton broaches. The gutta-percha and paper points after cooling in the basket have lost none of their desirable properties.

I have said that a root canal should be of the general shape of the fine paper root canal driers as furnished us by the dealers. In addition to this general form, have the mouth of each canal a decided saucer shape. This will facilitate the placing of agents or instruments to or near the apical foramen.

Drying Canal.

The first step, then, is the complete dehydration of the dentin, using acetone, as advised by Dr. Prinz, as the dehydrating agent. After flooding the canal with acetone, use the paper points liberally until the canal is entirely free of moisture. Follow this with warm air. Then hold a warm wire in the canal for a minute or two, being careful that the wire is not hot enough to scar any part of the canal.

Right here is where many root-canal operations fail. The canals and tubuli must be as dry as it is possible to make them, bearing in mind that it is possible to do damage by overheating the root.

Introducing Rosin.

Now flood the dry root canal with the thin rosin solution, pumping it in with a wisp of cotton on a broach. When the canal is full of the solution, pass a fine wire or broach to the end of the canal. Work out all of the air that may be trapped therein. This is of vital importance.

After the canal has been flooded or pumped full of the rosin solution, dip the cotton and broach that is being used into or pick up on the cotton, bismuth oxide hydrate. Work this into the rosin solution that is already in the canal. This is not essential to the preservation of the filling, but makes a more distinct picture of the finer canal fillings when the X-ray is in use.

Inserting Gutta-Percha Cone.

The canal point should be made of the base plate gutta-percha. It should carry no drugs nor any additional element that will have a tendency to weaken or reduce the strength or rigidity of the cone, because we wish the gutta-percha to dissolve rather slowly at the periphery, while the attenuated centre retains rigidity sufficiently to permit of being pushed along.

Select a gutta-percha cone that will reach to or near the end of the canal, holding the cone with a fine foil carrier, and pass the cone carefully and surely about *half-way* into the canal, pumping the cone up and down in the canal, usually from forty to sixty times, and, as it dissolves in the chloroform, advancing the cone farther toward the apex.

The pumping motion forces the rosin solution farther into every opening. The chloroform at the same time dissolves the periphery of the gutta-percha cone, which, becoming more and more attentuated, slips farther toward the apex, surrounding itself with a mixture of gutta-percha and rosin. The rosin seals the tubuli and at the same time causes the gutta-percha to stick tight to the canal walls and makes the gutta-percha more stable and proof against the action of body fluids or substances.

If this does not leave the large end of the gutta-percha cone at or near the end of the canal, place a small cone alongside or on the first one, then, with cold steel plugger points that will go into the canals, gently pack the mass into the canal, using warm air to soften the protruding gutta-percha if necessary.

This packing forces the semi-fluid (chloro-percha and rosin) into the unknown canals and pockets, and at the same time brings the surplus chloro-percha to the mouth of the canal, where it may be taken up with absorbent rolls or cotton.

In multi-rooted teeth complete the filling of each individual canal before starting another.

Rub the steel plugger points on paraffin cake to prevent the partially dissolved gutta-percha from adhering to the instrument. The pulp chamber is to be filled with one of the cements.

Queries Answered.

You may ask: "Do you succeed in filling all canals and tubuli to the farthest extremity?" No; only those that are open and dry to the farthest extremity.

Are we likely to have inflammation in the periapical region following the closure of root canals in this manner?

The probability of inflammatory conditions in all cases depends upon

the ability of the operator to read the pathological signs of each individual case and his skill and delicacy of touch in the manipulation of the various agents used.

Rosin and chloro-percha and gutta-percha cone is superior to chloro-percha in three ways. First, the rosin in chloroform penetrates deeply into the tubuli and foramina, into which *chloro-percha will not enter at all,* leaving within such tubuli or foramina, upon the disappearance of the chloroform, a more or less solid, inert, insoluble substance that enmeshes the contents and seals the lumen of such tubuli or foramina. Second, the rosin and chloroform causes the gutta-percha, in whatever form it may be applied, to adhere closely to the walls of root canal or cavity. Third, the incorporation of the rosin in the freshly made chloro-percha makes an unshrinkable and impervious mass about the gutta-percha cone. If gutta-percha and rosin be dissolved in chloroform and left in an open dish or tube to dry or solidify, the rosin will rise to the surface and harden in a crust over the gutta-percha. When the mixture is made in the root canal, as has been suggested, the rosin in solution is held firmly in place in the dissolved gutta-percha between the canal wall and the cone in the centre.

We must be prepared to meet all sorts of morbid anatomical changes in the pulp chambers, root canals and the dentinal tubuli, due largely to constructive irritations long present in and about the tooth.

The illustrations I show are selected, each one, to assist in demonstrating that the teeth which require root canal treatment are, as a rule, far from being the perfect anatomical specimens that we see illustrated in our text-books. A tooth that has lost its pulp has usually been subjected for a long time to those conditions that bring about destructive as well as constructive changes.

The rosin solution does not show in X-ray pictures until mixed with gutta-percha, when it shows very plainly in the canals and foramina, but not in the tubuli. Chloro-percha will not enter the tubules; bismuth oxide does not dissolve in chloroform, and therefore does not enter the tubuli; the blue stain spoken of enters the tubuli with the chloroform and rosin solution, but does not show in X-ray pictures; so, in order that we might have some visible evidence of the diffusibility of the rosin solution through the dentin, I have resorted to color photography. To vouch for the correctness of the pictures I have the original specimens here for comparison. One better versed than I in laboratory technic could certainly work out a more satisfactory scheme than this.

The pulp canals of a number of extracted teeth were opened mechanically—that is, with burs and drills—dehydrated and pumped full

of the rosin and chloroform that had been stained blue. Then the gutta-percha cones were used as has been described above.

I do not claim that this procedure gives an exact reproduction of conditions in a tooth canal while the tooth is yet in service in the mouth. I do claim that the specimens and the pictures give a clear and understandable basis from which we can work toward a reasonable ideal.

The illustrations following are shown more to explain the theory than to prove results. There is a vast difference between filling a root canal in an extracted tooth and one in situ.

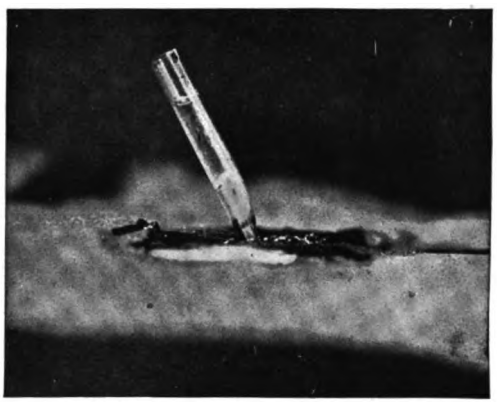

Fig. 507. Water dropped into a dry glass tube does not go to the end of the tube on account of entrapped air. Rosin solution should be worked to the ends of root canals with fine broach.

Fig. 508. Shows what happens when long gutta-percha canal point is forced into canal without the pumping motion.

Fig. 509.
(See caption under Fig. 510)

Figs. 509 and 510. Tooth substance having been dissolved away from root canal filling. Shows the long minute canals that the rosin and gutta-percha solution enters and seals.

Fig. 511. Palatine root of upper molar enlarged with drill, making a false pocket. The rosin-gutta-percha solution not only filled the false pocket, but entered the true canal and filled it to the end.

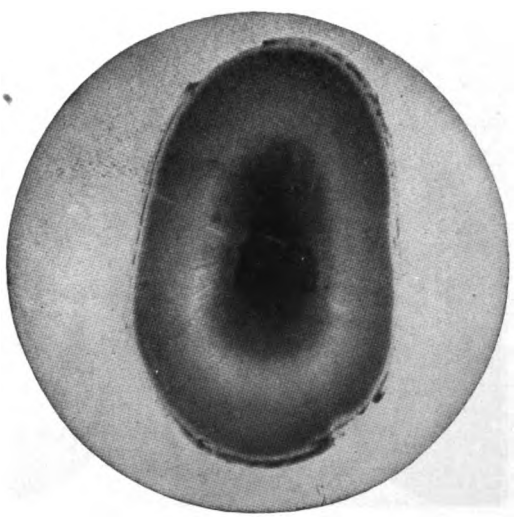

Fig. 512. The shaded area about the root canal filling shows the distance that the rosin has penetrated the dentinal tubuli in this tooth root.

Devitalization of the Pulps of Healthy Teeth For Bridge Work

Until recently the writer has been a sincere advocate of devitalization of teeth to be shell-crowned for bridge abutments, and it is still my opinion that if a tooth is *properly* prepared to receive the *ordinary* type of shell crown the tooth will be so mutilated that the pulp in it will die. A new type of shell crown then, the use of which does not necessitate such destruction of tooth structure as to endanger the vitality of the pulp, is a thing I receive with great gratitude.

It is fortunate that I am able to print the following excellent paper by Dr. D. A. House. I wish to say to readers who may not appreciate the value and importance of Dr. House's paper, that Dr. House demonstrated the making of the crown he describes to me several years ago, and I paid little attention to him. Do not make the mistake of inattention I made. Every dentist should make crowns such as Dr. House describes. What folly it is to extract one abscessed tooth and then devitalize two teeth, fill the canals imperfectly, and insert a bridge!

A Method for Making a Gold Crown for Bridgework without Pulp Devitalization.

D. A. HOUSE, D.D.S., INDIANAPOLIS

Ever striving toward accuracy and perfection to meet new conditions constantly arising, the dental profession has to cope at present with facts which, a few years ago, were neither heard of nor anticipated.

Scientific and clinical research, coupled with Roentgenology, have proved that foci of infection exist in the dental field and not only do exist there but, too often, are there because of faulty dental operations. This naturally places the dental profession in a rather precarious position.

Scientific research has quite conclusively proved that neuritis, arthritis, endocarditis, &c., &c., can be, and are, caused by infection being admitted into the blood stream. That there is somewhere a focus where the infection is produced and that that focus of infection may exist at the apex of the root of a devitalized tooth. The lesion about the tooth may not be manifested in any way whatever. The tooth may not ever be suspected of being in any condition other than normal; and yet it may be the prime source of any one of numerous conditions that make life miserable for the patient and can even destroy life itself.

With the aid of the radiograph these foci of infection are not only

revealed to us almost unfailingly, but it reveals to us the cause of the infection, and embarrassing as it is to admit it, the dental profession must acknowledge it is often due to faulty and unjudicious operations.

If then, the above conditions do exist, and are caused to exist by faulty technic or impossible perfection in operation, the logical procedure is to do the operation in a manner by which the faulty or impossible feature is eliminated.

When a shell crown is indicated in the construction of a bridge, instead of pulp devitalization in order to prepare the natural tooth crown in such a manner that the crown band may be adjusted as accurately as possible around the cervix of the tooth, which is practically impossible to do accurately enough to prevent subsequent irritation of the gingivae, I have adopted the following technic for crown construction. This method

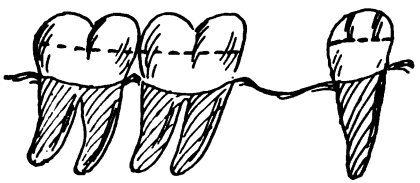

Fig. 513.

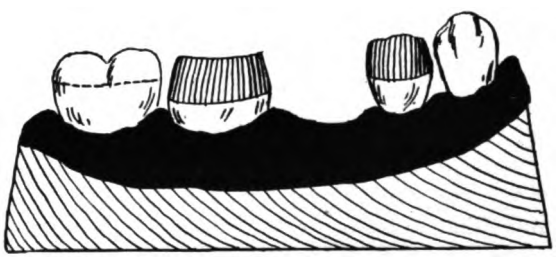

Fig. 514.

not only eliminates pulp removal with is dangerous sequalae but leaves the gum tissue in its natural normal condition, instead of producing a condition conductive to disease.

Having noted the results of this form of crown construction for a number of years, I use it exclusively where the shell crown is indicated for bridge abutments, not only on molars but bicuspids, also where esthetic considerations do not contraindicate its use. The technic being similar in either case, I will illustrate it in the construction of the molar crown only.

The normal form of a molar or bicuspid naturally makes the entire circumference convex. Because of this convexity, the diameter differs

from the occlusal surface to the cervix (Fig. 513). In order to retain an anatomical form of the crown when completed, and to have it sufficiently heavy for rigidity, it is necessary to grind the natural tooth to a point

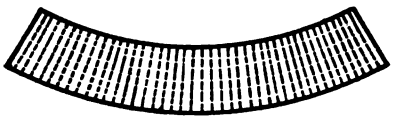

Fig. 516.

Fig. 517.

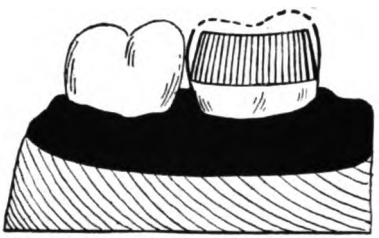

Fig. 519.

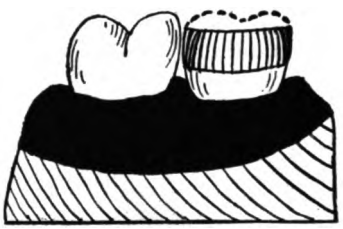

Fig. 518.

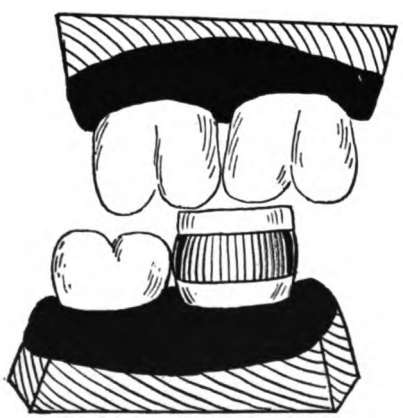

Fig. 520.

about midway between its greatest diameter and the gingival margin. (Fig. 514.)

There is seldom any discomfort to the patient as the enamel is only partially removed. Care should be taken not to injure the contact point of the approximating tooth.

Having ground the tooth conical in form, an impression is taken, model made and a pure gold, 34 gauge, band fitted to the model in the following manner: A piece of gold curved in form like Fig. 515, either by cutting or passing a straight piece through the gold roller with one set screw advanced a little closer than the other, when formed into a band will be conical in shape (Fig. 516), and is fitted to the model closely and

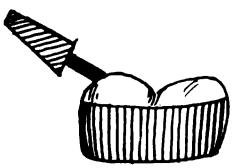

Fig. 521.

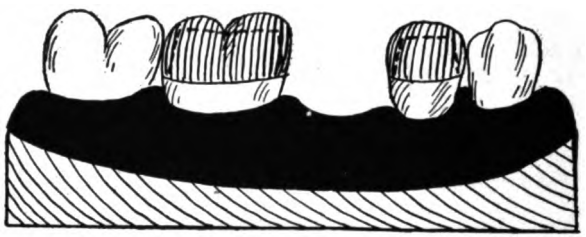

Fig. 522.

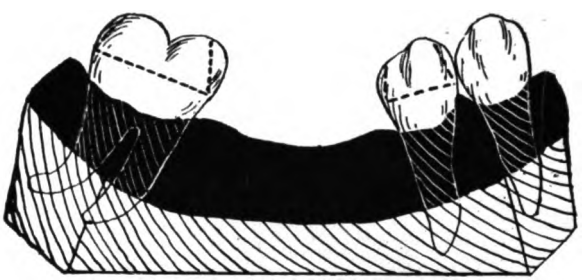

Fig. 523.

made to extend just to the point where the tooth has been ground (Fig. 517). After being fitted to the model, it is fitted on the tooth in the mouth. Be sure to extend it to all points where the enamel has been removed. It should be made to fit the tooth perfectly by burnishing, and the occlusal end should be short enough not to interfere with the closing of the teeth.

It is removed in a plaster impression and before pouring the model a little baseplate wax is flowed on the inner surface of the band, so later, by slightly warming it, it is easily removed from the model.

With the band in its proper position on the model, a second band of 29 or 30 gauge, 22-K. gold is contoured and fitted over the first band, Fig. 518, noting especially the original contour and contact point of the

natural tooth. The second band should be about 1/32 of an inch shorter at the cervical margin than the first band, so that after uniting the two with 22-K. solder the cervical end may be finished to a sharp edge to prevent any thick margins and to facilitate possible future burnishing.

The space between the bands having been perfectly filled with solder, it is now ready for final adjustment to the tooth. The occlusal surface of the tooth having been ground sufficient for a heavy occlusal surface on the crown (Fig. 519), the band is trimmed just even with the occlusal plane. A piece of pure gold, 34 gauge, is soldered on the end of the band, which is then placed on the tooth. The pure gold end is now burnished to the ground occlusal surface of the tooth.

A wafer of softened inlay wax (Fig. 520) is then placed on the occlusal surface of the crown and the patient instructed to "bite." After the wax is chilled, the band and wax are removed, the wax securely attached and carved (Fig. 521). Next invest and cast. Should the casting form an imperfect attachment to the crown, unite the parts with solder.

This part of the technic being completed, it is ready for replacement on the tooth (Fig. 522) for final impression and subsequent finishing of the bridge in whatever manner appeals to the operator.

While this form of crown construction has been most gratifying in all cases where vital teeth are involved, I can most heartily endorse it in cases where a convergence of teeth, due to the long loss of the missing teeth (Fig. 523) has entirely changed their axial relations.

As I said in a preceding paragraph, this form of crown construction can be used for bicuspids when esthetic reasons do not interfere; it can even be carried to the lower cuspids under similar conditions, the technic being similar in all instances.

For one who prefers using the casting process whenever possible, the technic can be changed as follows: After the first pure gold band is fitted, the occlusal end of pure gold is soldered to this, the contour and occlusion are formed in inlay wax and the whole cast in one operation instead of adding the second band of 22-K. gold. But, because of the accurate fitting of the first band, I find that the shrinkage following casting is such as to make replacement of the crown on the tooth for the final impression more difficult than where the double band method is used.

In the above method it is not only possible to construct a most serviceable substitnte for the natural tooth but it is done without sacrificing the vitality of the pulps of natural teeth and without jeopardizing the health and gum tissue and pericemental membrane surrounding the teeth.

Conclusion

To conclude this chapter, I now quote from a paper read before the Chicago Dental Society. As a hen lays eggs primarily " for personal relief " rather than the benefit of humanity, I admit I give the following for the same reason. I want to advise physicians, dentists and radiographers so we may all meet this problem of pulp canal work and systemic infection to the greatest possible advantage of the patients in our care:

To Physicians*

1. Shoulder your share of the responsibility for the occurrence of local foci of infection in the mouth.

2. Do not advise the the extraction of two teeth because one tooth is abscessed—nor all teeth because some are abscessed.

3. Never advise extraction without first making radiographs.

4. Have an expert read the radiographs, or pass on your reading, until you have become expert.

5. Do not say all teeth with the pulps removed should be extracted, for we do not know that this is true.

6. Do not forget that teeth have an important function. This is just as much a truth as it ever was. Keep it in mind.

7. Wake up to the fact that to learn what you should know of this subject you must hear what dentists have to say about it. Invite them to lecture at your meetings and in your schools.

8. Keep this in mind: The dentists of the United States have developed a Research Commission, which will rank with the Carnegie and Rockefeller Laboratories for research.

9. Remember that most of the diseases of infancy were once attributed to teething.

To Dentists

1. Do not jiggle about, and try to sidestep the situation.

2. Support the National Research Commission with your heart, mind and money.

3. Let the apical excision and curettement operation become a common one, not an uncommon one.

4. Admit that the destruction of pulps has been ruthless, and as you admit it, correct the mistake.

---

* August, 1915, *Dental Review.*

5. Develop a new and better bridgework. Bridgework is not to be relegated to the scrap heap—but it should be modified.

6. Never expect to hear again the man who came to your meeting and said he "filled all canals to the apex."

7. Admit it is impossible to reach and fill to the apex all canals. No man can do it by the methods you now use.

8. Look to the National Research Commission to learn if you should extract teeth when it is impossible to fill the canals to the end.

9. Know that it is not a crime to fail to fill a canal perfectly, but that *it is a crime* not to try to fill it.

10. Charge for the treatment of teeth on a time basis and render a bill whether you save the teeth or not.

11. Change your slogan from "Save Teeth" to "*Save Teeth —But Never At The Expense Of Producing A Chronic Abscess.*"

12. Do not depend on medical men to make and read your radiographs for you.

To Radiographers

1. Do not read a diagnosis into every radiograph whether it is there or not. Learn to say, when it is the case, "The radiograph shows me nothing."

2. Believe in the infallibility of the radiograph, knowing it is the product of definite and unchanging chemical and physical laws, but realize that, unless you know these laws, it may mislead you.

3. Never deny the assertion that radiographs have unfortunate limitations. Though the radiograph is the greatest single aid to dental diagnosis, it nevertheless fails often to show us what we want to see.

4. Understand the necessity of making more than one radiograph of a single case. When in doubt, verify with another radiograph.

5. Distrust any radiographic finding that is not backed up by the clinical evidence.

6. Do not profess to be a dental radiographer unless you are a dental pathologist.

7. Try not to blame the radiograph for your occasional silly interpretations of it.

8. Know the list of the common misinterpretations of radiographs. (Appendix, Chapter VI.)

9. Understand that it does not fall within the province of radiographers to be harsh critics of either dentists or physicians. Your position is a delicate one. Handle it with patience, kindness, coolness and honesty. Do not try to turn things upside down all at once.

To Physicians, Dentists and Radiographers All!

Let us all appreciate the necessity for team work. The tendency to clannishness in the human being is fundamental. The boys of the east end hate the boys of the west end. Knowing this human fault of clannishness, let us guard against it.

When a man of one profession meets a bonehead of another, do not attribute the osseous condition of the man's head to the profession of which he is a part.

Let us realize that to the best of our present knowledge, if teeth are properly treated they do not abscess.

Therefore, they must be treated properly.

If teeth are to be treated properly there must be a raise in the average fee charged.

People turn from good dental treatment on account of the cost, and indeed and actually very many of our American people cannot afford to have their teeth treated properly. What is to become of them? Some one answers, "Extract their teeth." The answer is that the medical profession has tried to persuade women not to wear corsets ever since we can remember, but women wear them just the same. Likewise, it will be found impossible to induce poor people to give up their anterior teeth. They will go to the dental quack. And what if we expose the quack and destroy him? It would be a good, though difficult, thing to do, but the point is that we do not want to extract teeth, we want to save them.

The solution of the whole problem lies, not in the development of an inexpensive method of treating pulp canals, which it seems to me, is impossible, but in a publicity campaign which will lessen the necessity for treating canals.

Do people really know that they save health, pain, money and time by having their teeth filled before they ache? In a hazy sort of a way they do; but they do not know it well enough, and it is our fault that they do not. We must teach them.

Our slogans are changing. We no longer say, "Swat the fly," we say, "Prevent the fly"; we do not say, "Reform the criminal," but "Prevent the criminal." We talk little about "curing tuberculosis," but much of "preventing it." So let us not only improve our pulp canal treatment work, but do the bigger thing—try to prevent the conditions which make pulp canal work necessary.

INDEX

Abortion 277
Abscess,
Alveolar 186
Chronic 405
Dentoalveolar 185
Destruction of Tissue in 187, 412, Fig. 452A
How to Avoid.....442, 472
Multirooted Teeth..... 190
Number of Teeth Involved..... 189
Of Crowned Teeth.....191, 452
Opening on Face.....253, 257, 419
Pericemental 195
Photograph of.....373, 379
Probable Causes..... 472
Pyorrhea Alveolaris, Differential Diagnosis 193
Treatment of.....399, 463
When Cured.....381, 463, 465
Absorption of Teeth (See Resorption)
A. C.....2, 9, 11, 24
Acid Fixing Bath..... 78
Acid, Sulphuric..... 479
Advice to
Beginners in Radiography (See the Preface) 128
Dentists 500
Physicians 500
Radiographers 501
Alopecia 278, 429
Alternating Current.....2, 9, 11, 24
Alveolar Abscess (See Abscess)
Ammeter or Amperemeter..... 32
Ampere 4
Amputation of Apex of Tooth Root 201, 413, 419, 468
Angle of X-rays..... 99
Anode 41, 42
Ankylosis 247, 263
Anodyne 447
Anomalies 230
Anterior Palatine Foramen..... 364
Anti-Cathode 41, 42
Antrum of Highmore..... 234
Foreign Body in..... 238
Pus in.....234, Fig. 451
Radiographing of..... 341
Apical Foramen,
Filling to.....175, 437
Filling Through.....408, 446
Multiforamen 439, 473
Apicoectomy 201, 413, 419, 468
Apparatus Radiographic....14, 295, 320
Appendicitis 416
Aprons, X-ray Proof..... 286
Armature 9
Arsenical Necrosis.....231, 422, 472
Arthritis 416, 456
Articulation, Temporo-Mandibular, 242, 266
Artificial Roots..... 213
Asepsis 456, 471
Assistant Anode..... 46
Attachment, Gilmore..... 375
Average
Canal Filling..... 438
Dentist 440
Azo Photographic Printing Paper.. 83

Bacteremia 416
Bacteria, Cultures of..... 472
Bad Canal Work..... 437
Benoist Penetrometer..... 346
Bi-anodal X-ray Tubes..... 44
Bismuth Paste..... 199
Blood Supply..... 266
Bone Eburnation..... 382
Bone Regeneration...203, 381, 400, 465
Bone "Whorls"..... 214
Boxes, View.....136, 406
Bridgework 209
On Vital Teeth..... 498
Bromide Paper..... 347
Broken
Broach in Canal..... 205
Tooth 205, 208
Burn, X-ray (See Dermatitis)

Cabinet, Protective Lead..... 280
Calculus 194, 217
Callahan
Papers by..... 474
Solution 485
Technic for Canal Filling..... 485
Canal Filling,
After-pain 447
Average 438
Asepsis vs. Mechanical Perfection 383, 456
Callahan's Solution..... 485
Causes of Failure..... 458
Chart of 438, 452

Difficulty 437
Economics 453
Encapsulating Apex..... 446
Failures 437
Gutta Percha..... 267
In Molars..... 458
In Teeth Other than Molars... 437
Kinds Seen in Radiographs..... 408
Materials 401
Multiforamen 439, 473
Preparation for..... 474
Proprietary, Pastes..... 401
Radiography of.....370, 447
Repeated Efforts..... 439
Rosin Solution..... 485
Technic 485
To Apex.....175, 437
Through Apical Foramen....408, 446
What Is Bad..... 447
Canals of Teeth,
Enlarging 175, 210, 460 474
Filling 175, 485
Canal Surgery (See Canal Filling)
Cancellous Spots in Bone.....Fig. 401
Cancer 274
Carelessness with X-rays..... 426
Caries,
Dental 269, 420
Of Bone..... 231
Cathode 42
Collars 337
Stream 48, 49, 331
Cement 403
Cementoma .....214, Fig. 431
Chair, Radiographic..... 112
Charts,
Conditions Indicating Extraction. 415
Dr. Best's..... 472
Educational 452
Evidence of Infection..... 410
Ionization 470
Kinds of Canal Fillings..... 408
Milliampere-second 355
Showing Treatment Indicated.... 412
Cholecystitis 416
Circuit, Electric..... 10
Coil,
Faradic (See Faradic Coil).
High Frequency (See High Frequency Coil).
Induction (See Induction Coil).
Interrupterless (See Interrupterless Coil).
Color of X-ray Tube....51, 52, 326, 332
Combination X-ray Tube..... 337
Commutator 9
Compression Cones and Diaphragms 63, 64, 302
Condenser 34
Conductors, Electric..... 1
Congenital Absence of Teeth (See Missing Teeth).
Conservation of Dental Pulp..442, 495
Contact Lantern Slides..... 354
Continuance of Infection After Extraction 464
Converter, Rotary..... 36
Coolidge, X-ray Tube..... 331
Coronoid Process.....Fig. 406
Cranial Sinuses..... 341
Crooke's Tube..... 41
Crowned Teeth.....181, 191, 452, 495
Cultures 472
Culture Media..... 472
Currents 2, 53
Cut Outs (See Fuses).
Cutting of Teeth, Delayed..... 148
Cycle 2
Cyst,
Bone 218
Dentigerous 222

Danger,
Influence of Fees..... 426
Of Electric Currents..... 430
Of the X-rays.....273, 423
To Operator..... 287
To Patient..... 288
Dark Room,
Lantern 68
Tips in Technic..... 350
Ventilation 348
D. C.....2, 9, 11, 19, 295
Death from X-rays.....275, 276
Deciduous Teeth.....157, 161, 162, 163
Delayed Eruption of Teeth..... 148
Densities, Recorded on Radiograph 136, 138
Dental Caries.....269, 420
Dental Pulp,
Conservation for Bridgework.... 495
Electric Test.....394, 395
Test for Vitality.....394, 395
Dental Stereoradiographs.....298, 431
Practical Value of..... 314
Technic for Making..... 310
Dental X-ray Machines..... 320
Denticles 250
Dentist,
Advice to..... 500
Average 440
Educating 445
Dentoalveolar Abscess (See Abscess),
Pain in..... 405
Dermatitis 273, 274, 290, 425
Developing Box.....129, 134
Developer 75
Choice of..... 128
Hydrochinon 75
M. Q..... 75
Pyro 76
Temperature 76

Development,
Of Negatives.....74, 128, 351
Of Prints..... 83
Of Teeth 263
Destruction of Tissue, Bony and Tooth 187, 415
Diagnosis 360
Diagram,
Cathode Stream..... 48
Compression Cone and Diaphragm 64
Coolidge Tube..... 334
High Frequency Coil.....36, 38, 90
Induction Coil.....20, 32, 33, 34, 86
Interrupterless Machine.....39, 92
Mechanical Interrupter..... 28
Pose for Radiographs..70, 99 to 102
Pulp Conservation..... 442
Rheostat 25
Shunt 45
Stereoscopic Work..... 302
Switch 22
Valve Tube in Use..... 54
X-rays 48
X-ray Tubes 46, 57
Diaphragms and Compression Cones, 61, 64, 302
Differential Diagnosis, Pyorrhea and Abscess..... 193
Differentiation, Primary and Secondary Teeth..... 161
Difficulty of Canal Surgery..... 439
Direct Current 2, 9, 11, 19, 295
Disease, Systemic 416
Diseases of Eye, Ear, Nose and Throat 416
Dislocation of Condyle..... 242
Distance Between Target and Film or Plate 124
Distance Between X-ray Tube and Patient 96, 424
Disto-Buccal Root of Upper Molars 391
Doctor,
Best's Charts..... 472
Callahan's Papers..... 474
House's Paper..... 495
Hunter's Paper..... 268
Johnson's Editorial..... 357
Leach's Film-Holder..... 116
Lucas' Technic..... 468
Ottolengui's Words..... 407
Rhein's Technic..... 177
Van Woert's Technic...132, 134, 350
Dose of X-rays.....288, 424
Dry Plates..... 65
Drying,
Immediate 132
Of Negatives..... 80
Of Prints.....84, 353
Duration of Exposure.71, 124, 355, 424
Dynamos 9
Ear, Pain in..... 228
Eburnation, Bone..... 382
Economics 170, 453
Editorial, Dr. Johnson's..... 357
Writer's Reply..... 358
Education,
In Radiographic Work (See the Preface) 294
Of Dentists..... 445
Of Public..... 441
Electric Current, Danger of..... 430
Electric Pulp Testing,
Electrophobia 396
Liability of Accident..... 396
Limitations 395
Technic 394, 395
Electricity 1
Electrolyte 17, 21
Electromagnets 7
Electrophobia 396
Elementary Radiography...1 to 85, 319
Empyema of Maxillary Sinus..... 234
Encapsulation of Root End...408, 446
Endocarditis 416
Enlarging Apparatus..... 433
Enlargement 433
Enteritis 416
Ethmoid Cells.....234, 341
Evidence of Infection in Radiographs,
Chart of..... 411
Examination of Mouth.....398, 416
Example, Horrible..... 389
Exostosis, Dental.....214, 384, 411
Exposure,
For Prints.....83, 138
Of Patient Time Limit.....288, 424
Long with Big Outfit..... 356
Short with Small Outfit..... 356
Time of, for Negatives.....71, 124
Extra-Oral Radiographs.....94, 349
Extraction of Teeth.....162, 168
Chart Indicating..... 415
Continuance of Infection After.. 464
Few at Time..... 464
Eye, Disturbance of.....172, 469

Facial Fistula.....253, 257, 419
Facial Neuralgia (See Neuralgia).
Failures in Canal Work, Causes of. 458
Fallibility of X-rays..... 357
Faraday 8
Faradic Coil (See Electric Pulp Testing).
Fatality from X-ray Lesions...275, 276
Faults in Negative..... 352
Ferrotype 353
Field 9
Filling (See Canal Filling).
Encroaching on Pulp.....181, 378
Large 395
Filling Materials for Canals..... 401

Film,
Description of..... 66
Methods of Holding in Mouth... 109
Mounts (See Radiomount)
Placing Outside the Mouth..... 349
Protection of.....297, 346, 350
Radiographs, Advantages of..... 135
Special X-ray.....66, 96
Film Holders..... 311
Ketcham 347
Kny-Sheerer 305
Leach 116
Stereoscopic 435
Van Woert..... 350
Filter 289, 424
Fistula on Face.....253, 257, 419
Fistulous Tract..... 199
Fixing,
Box 78
Of Negatives.....77, 351
Of Prints 84
Fluorescence of X-ray Tubes,
51, 52, 326, 332
Fluoroscope 55, 143, 144
Foot Switch..... 427
Foramen,
Anterior Palatine..... 364
Mental 363
Foreign Bodies..... 202
In Antrum..... 238
Fracture,
Of Jaw..... 244
Of Tooth..... 208
Friedlander's Shield..... 63
Frontal Sinuses..... 234
Intensifier 344
Pose for..... 341

Gagging 111
Gastric Ulcer..... 416
Generator 9
Gilmore Attachment..... 375
Gloves 286
Granuloma (See Abscess)
Grounding Electric Current..... 120
Growing Cultures..... 472
Guide to Treatment by Radiographs
(Chart) 412
Gutta Percha,
As Canal Filling.....176, 267
Non-irritating 176

Hair, Loss of.....278, 429
Headache 260
High Frequency Coil,
Description of.....33, 322
Diagram of.....36, 38, 90
Technic Involved in Use of...35, 90
Holder, Film..... 311
Ketcham 347
Kny-Sheerer 305
Leach 116
Stereoscopic 435
Van Woert..... 350
Holding Film in Mouth.....109, 426
Horrible Example..... 389
Hydrogen X-ray Tube..... 340
Hydrometer 21
Hyoid Bone..... 368
Hypercementosis (See Cementoma)
"Hypo" 78, 79
Hypochondriac 261

Idiopathic Neuralgia..... 251
Ignorance with X-rays..... 426
Illuminating Boxes.....136, 406
Immediate Drying of Negative.... 132
Immunity 290
Impacted Teeth..168, 206, 259, 262, 417
Indication for Root Resection..413, 419
For Extraction..... 415
Induction Coil,
Description of.....15, 323
Diagrams of.....20, 32, 33, 34
Technic Involved in Use of.... 86
Infallibility of X-rays..... 358
Infection,
About Third Molar..... 418
Continuance After Extraction... 464
Elimination Without Extraction. 463
Evidence of, in Radiographs.381, 411
Local Foci.....272, 399, 462
Metastatic 272, 416, 456
Oral Foci (See Local Foci).
Periapical (See Local Foci).... 410
Pyorrheal 464
Systemic (See Metastatic).
Treatment of.....399, 465
When Overcome.....400, 465
Inferior Dental Canal.....252, 365
Inflammation About Bridge..... 211
Inoculation 472
Insanity 256, 277
Insomnia 256
Installation 15, 36
Insulation 7, 27
Intensifier 81
Intensifying Screens 127, 344
Interpretation of Radiographs..136, 357
Mistakes in..... 361
Interrupterless Coils,
Description of.....38, 320
Radiographs Made with..... 356
Technic Involved in Use of.92 to 94
Interrupters 17
Intra-Oral Radiographs..... 94
Inverse Current..... 53
Inverted Teeth.....172, 173
Involvment of Pulp, Treatment to
Avoid 442
Iodin, Treatment with..... 466
Ionization,
Case Treated..... 467
Chart, Technic.....469, 470

Jumping the Bite..... 263

Kassett 345
Kilowatt 5
Kilowatt-Hour 5
Kinds of Canal Fillings.....401, 409

Lame Teeth..... 184
Lantern Slides..... 354
Large Plate Negatives, Advantages of 135, 392
Lassitude 278
Lead Cabinet.....280, 426
Lead Screen.....280, 296
Leukemia 277
Liability for Accident.....426, 430
Life, Loss of..... 275
Lighting of X-ray Tube,
With High-Frequency Coil..... 91
With Induction Coil..... 89
With Transformer.....93, 94
Limit of Exposure.....288, 424
Lingual Tubercle..... 369
Local Foci of Infection...272, 399, 462
Locked Jaw..... 262
Lower Anterior Teeth, Radiography of 112
Lower Posterior Teeth, Radiography of.....108, 110
Ludwig's Angina..... 253
Luxation 242

Machines, Dental X-ray..... 320
Magnetism 5
Magneto 9
Making,
Crowns for Vital Teeth..... 495
Cultures 472
Dental Radiographs.....65, 85
Lantern Slides..... 354
Negatives (See Negatives).
Photographic Prints.....83, 353
Plastic Radiographs..... 317
Radiographs of Sinuses..... 341
Stereoradiographs 303
Malformed Teeth..... 230
Malposed (See Impacted Teeth).
Manufacturers 66, 297, 445
Mastoid, Pose for..... 344
Materials, Canal Filling.....401, 485
Maxillary Sinus (See Antrum).
Maxillary Suture..... 266
Media, Culture 472
Mental Foramen..... 363
Metastatic Infection.....272, 416, 456
Meters 32
Methods of Holding Film in the Mouth 109
Milliampere Second,
Definition of..... 355
Dose of X-rays..... 423
Exposure Table..... 355
Missing Molars 151
Missing Teeth.....148, 156, 157, 266
Mistakes,
In Canal Filling.....458
In Interpretation of Radiographs 361
Motor 37
Moisture, Protection of Film from, 97, 350
Molars,
Filling Canals of.....458
Impacted Third.168, 206, 259, 262, 417
Lower, Radiography of.....108, 386
Missing 151
Upper Radiography of.....99, 390
Mounts, Film (See Radiomounts)
Mouth, Examination of.....398, 416
Myelosarcoma of Lower Jaw..... 226

Nasal Cavity Spots..... 365
Necrosis 231, 365, 368
Negatives,
Densities Recorded in.....136, 407
Development of.....74, 130, 350, 351
Drying of.....80, 130, 132
Faults in..... 352
Fixing of.....77, 351
Intensification of..... 81
Marking of.....141, 451
Reducing of..... 81
Scratching 135
Washing of.....79, 132, 350
Nephritis 416
Neuralgia, Facial 160, 180, 249, 392
Neurasthenia 256
Neuritis 416
Neuroses 256
New Standards in Canal Work.... 440
New Words, Dr. Ottolengui's.... 407
Non-Conductor 2
North Pole of Magnet..... 6
Nostrils .....Fig. 403

Odontoma 152, 156, 228, 229
Ohm 3
Oral Foci of Infection (See Local Foci).
Orthodontia 163, 164
Oscillimeter 54
Oscilloscope (See Oscillimeter).
Osteology 263
Osteoma 227
Osteosclerosis 382
Overhead Wiring..... 327

Pain,
After Canal Filling..... 447
Of Dentoalveolar Abscesses..... 405
Of X-ray Lesions..... 277
Palatine Foramen 364

Paper,
Bromide 347
Photographic 83, 347
Radiographs on..... 317
Parallel Spark (See Terminal Spark Gap) 43
Patients, Limit of Exposure for 288, 424
Penetration of X-rays..... 56
Penetrometer 55, 346
Perforation of Teeth.....179, 375
Periapical Infection (See Abscess) 410
Treatment of.....272, 399, 462, 464
Pericemental Abscess..... 195
Pericemtitis, Chronic..... 184
Perspective 142, 144, 298
Phase 319
Phenol Sulphonic Acid, Treatment with 465
Photograph of Abscess.....373, 379
Photographic Paraphernalia Needed, 295
Photographic Prints, 83, 84, 137, 138, 353
Physical Condition..... 400
Physician,
Advice to..... 500
His position..... 463
Placing Film Outside the Mouth... 349
Planted Teeth..... 212
Plastic Radiography..... 317
Plastic Stereoradiographs..... 318
Plate Changers..... 300
Plates and Films,
Advantages of Large Plate Negative 135, 392
Fogged 352
Photographic 65
X-ray 66, 96
Potassium and Sodium, Treatment with 477
Pose for Making Radiographs,
Of the Antra of Highmore..117, 341
Of the Ethmoid Cells..... 341
Of the Lower Anterior Teeth.... 112
Of the Lower Molar and Bicuspid Region 108, 110
Of the Upper Anterior Teeth.... 103
Of the Upper Molar and Bicuspid Region 98
Of the Sphenoids..... 341
With the Film Outside the Mouth. 349
Position of Film and Direction of X-rays 347
Position of Film in the Mouth..94, 95
Positive Wire, Test for..... 19
Positives 83
Potential 2, 3
Pregnancy 277
Preparation of Canals for Filling.. 474
Prescription 447
Primary,
Current 11, 27, 33
Teeth (See Deciduous Teeth).
Winding 11, 27, 33
Prints, Photographic 137
Development of..... 83
Drying of.....84, 353
Exposure 83, 138
Fixing of..... 84
Washing of..... 84
Probing 199
Process, Coronoid.....Fig. 406
Proprietary Canal Filling Materials. 401
Protection 287
Apron 286
Box 297, 346
Cabinets 280, 426
Gloves 286
Of Films.....297, 346, 350
Points in for Operator.....287, 427
Screens 280, 296
Shield 59, 285
Spectacles 286
X-ray Tube..... 285
Psychoses 256
Public Education..... 441
Publicity 445
Pulp (See Dental Pulp).
Pulpitis 421
Pulp Stones 179, 384
Pulp, Test for Vitality..... 394
Punctured X-ray Tube..... 52
Purchasing a Radiographic Outfit. 292
Pyorrhea Alveolaris.....193, 464
"Pyro" 76

Radiodontia 85
Radiographers, Advice to..... 501
Radiographic Appearance of Anterior Palatine Foramen.... 364
Antra 235
Canal Fillings.....401, 408
Canal Fillings Short of Apex.369, 438
Cancellous Spots in Bone.....Fig. 401
Carious Cavity..... 420
Coronoid Process of Mandible, Fig. 406
Cyst .....220 to 225
Disto-buccal Root of Upper Molars 391
Fistulous Tract..... 199
Granuloma (same as Abscess).
Hyoid Bone 368
Inferior Dental Canal..... 365
Mental Foramen..... 363
Nasal Cavity..... 365
Nostrils .....Fig. 403
Odontoma 152, 228, 229
Osteosclerosis 382
Pyorrhea 193
Spinal Column..... 368

Radiographic Outfit, Purchasing a..292
Radiograph or Radiogram..... 65
Radiographs,
Extra-oral 94, 349
Intra-oral 94
Interpretation of.....136, 357
Made Direct on Photographic Paper 347
Mistakes in Interpretation..... 361
Preparation of, for Study with Stereoscope 311
Technic for Making.....85, 341
Treatment Guided by..... 413
Radiography,
Dental .....85 to 319
Elementary .....1 to 85
Plastic 317
Stereoscopic .....298 to 319
Radiography of,
Canal Fillings.....369, 401
Canal Filling Materials..... 401
Cements 403
Lower Anterior Teeth..... 112
Lower Posterior Teeth.....108, 110
Molars 99, 108, 386, 390
Sinuses 341
Upper Anterior Teeth..... 103
Upper Posterior Teeth..... 98
Radiolucent..... 407
Radiolucency 407
Radiopaque 407
Radiopacity 407
Radioparent 407
Radioparency 407
Radiomounts 130, 131, 132, 133
Radium Rays..... 291
Reading Glass..... 393
Reading Radiographs (See Interpretation of Radiograph).
Records,
Of Densities in Radiographs.136, 138
Radiographic Records..... 268
Rectifier 24
Reducer 81
Regeneration of Bone, 203, 381, 400, 465
Reproductions 137
Requirements of a Radiographic Outfit 295
Research Work..... 263
Resection,
Of Inferior Dental Nerve..... 252
Of Mandible..... 247
Of Tooth Roots (See Root Resection).
Resorption of Teeth.....157, 165
Retained Deciduous Teeth..... 157
Rheostat 25
Rigg's Disease (See Pyorrhea Alveolaris).
Roentgen,
Ray (See X-ray).
Wm. Conrad..... 49
Words (Also See the Preface).. 49
Root End, Encapsulation of..... 446
Root Resection (Apicoectomy),
A Case..... 468
Necessity of Radiographs..... 419
When Indicated.....412, 419
Roots of Teeth,
Absorption of (See Resorption),
Amputation of.....201, 413, 419, 468
Artificial 213
Forming 160
Fracture of 208
In Antrum..... 238
Radiographed for Bridgework.. 209
Rosin Solution.....485, 486
Rotary Converter..... 36
Ruhmkorff Coil (See Induction Coil).

Salivation 350
Secondary,
Current 11, 27, 33
Dentin 180, 442
Rays 57, 63, 289
Winding 11, 27, 33
Shield for X-ray Tube (See Protection Shield).
Short Circuit..... 19
Short Teeth..... 380
Shunt 42
Sinus, Pus (See Abscess).
Sinuses, Cranial..... 341
Sinuses, Radiography of..... 341
Skiagraph, or Skiagram..... 65
Slides, Lantern..... 354
Slogan 444
Sneezing 422
Sodium and Potassium, Treatment with 477
Soft Tube Technic..... 349
South Pole of Magnet..... 6
Spark Gap,
Current or Coil Regulating...35, 36
Inverse 52, 53, 56
Parallel (Same as Terminal).
Series 52, 53
Terminal 20, 35. 36, 39, 43, 44
Tube Regulating.....45, 49, 339
Spasm, Facial Muscles..... 260
Specialists in Radiographic Work, 292, 294
Spectacles 286
Sphenoid Cells..... 341
Spinal Column..... 368
Squeegee Board..... 353
Stands, X-ray Tube....59, 60, 284, 296
Static Machine..... 14
Stereoradiographs,
Plastic 317
Technic for Making..... 303
Stereoscope 298, 299

Stereoscopic,
Radiography 144, 298
Table 301
Tube Stand.....301, 303
Sterility 277
Sterilization, Technic of..... 471
Stones,
Pulp 179, 384
Salivary 217
Supernumerary Teeth..... 167
Suppuration (See Abscess and Pyorrhea).
Switches 17, 427
Synchronous 39
Systemic Disease..... 416

Tables (See Charts).
Target 41, 42, 333
Distance of Skin to..... 424
Technic,
Callahan for Canal Filling..474, 485
Dark Room Pointers..135, 350 to 354
For Covering Films..... 97
For Culture Making..... 472
For Developing.....74, 128
For Drying Negatives Immediately 132
For Holding Film..... 109
For Ionization..... 469, 470
For Lighting X-ray tube, 89, 91, 93, 94
For Making Crown on Tooth with Vital Pulp..... 495
For Making Dental Radiographs, 85 to 136, 341 to 357
For Making Dental Negatives for Immediate Use..... 132
For Making Electric Test for Pulp Vitality.....394, 395
For Making House Crown..... 495
For Making Lantern Slides..... 354
For Making Negatives.....74, 128
For Making Plastic Radiographs 317
For Making Photographic Prints, 83, 353
For Making Radiographs...65 to 85
For Making Radiographs of Sinuses 341
For Making Stereoradiographs.. 290
For Sterilization..... 471
For Using Coolidge Tube..... 334
For Using High Frequency Coil 90
For Using Induction Coil..... 86
For Using Interrupterless Coil.. 92
Mistakes in Pulp Canal..... 458
Pointers in.....135, 345 to 356
Pulp Canal Surgery.....474, 485
Soft Tube..... 349
Van Woert.....132, 134
Teeth,
Abscess of (See Abscess).
Absorption of (See Resorption).
Anomalies 230
Canals of (See Canals).
Caries of, Hidden..... 269
Crowned 181, 191
Cutting Delayed..... 148
Deciduous 151, 157, 161, 162, 163
Delayed Eruption..... 148
Development of..... 263
Differentiation Between Primary and Secondary..... 161
Enlarging Canals of, 176, 210, 460, 474
Eruption of, Delayed..... 148
Extraction of.....162, 168, 415, 464
Filling (See Canal Filling)..181, 378
For Bridgework.....209, 495
Forming Roots of..... 160
Fracture 208
Impacted 168, 206, 259, 262, 417
Lame 184
Malformed 230
Missing 148, 151, 156, 157, 266
Moving 163, 164
Planted 212
Primary (See Deciduous).
Resorption of.....157, 165
Retained Deciduous Teeth..... 157
Roots of (see Roots).
Short 380
Supernumerary 167
Tumor of..... 214
Unerupted, Brought into Position 165, 418
What Is Straight Through..Fig. 389
Temporary Teeth (See Deciduous Teeth).
Temporo-Mandibular Articulation, 242, 266
Terminal Spark Gap, 20, 35, 36, 39, 43, 44
Tesla Coil (See High Frequency Coil).
Test,
For Polarity of Induction Coil.. 41
For Polarity of Lead Wires on D. C..... 19
For Pulp Vitality.....394
Therapeutic Agent, X-ray as..... 294
Thinking, Where It Leads Us..... 441
Third Molars (See Molars).
Tic Douloureux (See Neuralgia).
Tic, Facial Gesticulatory..... 260
Titubator 78
Tract, Fistulous..... 199
Transformer (See also Interrupterless Coil)..... 11
Trayrocker 78
Trays for Developing and Fixing 74, 350
Treatment,
Guided by Radiographs..... 413
Of Infection.....399, 400, 465

Treatment with,
Iodin 466
Ionization 469, 470
Phenol-Sulphonic Acid..... 465
Resection.....201, 413, 419, 468
Sodium and Potassium..... 477
Trigeminal Neuralgia (See Neuralgia).
Tube, Valve..... 54
Tube, X-ray..... 41
and Patient, Distance Between 96, 424
Bi-anodal 44
Color of.....51, 52, 326, 332
Combination 337
Coolidge 331
Crooke's 41
Hard 42
High 42
High-Frequency 57, 58
Hydrogen 340
Inverse in 53, 90
Low 42
Properly Lighted.....50, 51
Puncture of..... 52
Rack 58
Shield 59, 285
Soft 42
Stand 59, 60, 284, 296
Vacuum 41, 42
Vacuum Regulator.....45, 331
Vacuum to Buy..... 340
Tumor .....214, 224 to 229, 250
Turbinate Bones..... 237
Twitching 260

Unerupted Teeth,
Brought into Position.....165, 418
Malposed 206, 259, 262, 417
Unit 326
Upper Anterior Teeth, Radiography of 103
Upper Posterior Teeth, Radiography of..... 98
Uses of the Radiograph in Dentistry .....146 to 273, 416 to 423
Using Coolidge Tube, Technic.... 334

Vacuum 41, 42
Regulator 45, 331
X-ray Tube, of.....42, 340
Valve Tube.....53, 337
Van Woert,
Developing Tank..... 134
Film Holder and Indicator..... 350
Technic 134
Velocity of Electricity..... 3
Velox 83
Ventilation of Dark Room..... 348
Vibrator 17, 23
View Boxes.....136, 406
Villard Tube..... 54
Volt 3

Washing,
Of Negative.....79, 132, 350
Of Print..... 84
Watt 5
Winding,
Primary 11, 12, 27, 33
Secondary 11, 12, 27, 33
Wiring for Installation.....15, 36
Wires in Canals.173 to 176, 179, 183, 377
Wisdom Teeth (See Third Molars)

X-ray,
As a Therapeutic Agent..... 294
Burn.....273, 274, 290, 425
Carelessness with..... 426
Dangers of..... 273
Dental Machines..... 320
Discovery of..... 49
Dose of.....288, 424
Film 66, 96
Ignorance with..... 426
Limit of Exposure to.....288, 424
Machines 14
Outfit 295
Penetration of..... 56
Proof Box.....297, 346
Tubes (See Tubes).
Tube Stand.....59, 60, 284, 296
Unit 326